

# Frontal lobe epilepsy with atypical seizure semiology resembling shuddering attacks or wet dog shake seizures

Alena Jahodova<sup>1</sup>, Pavel Krsek<sup>1</sup>, Vladimir Komarek<sup>1</sup>, Martin Kudr<sup>1</sup>, Martin Kyncl<sup>2</sup>, Josef Zamecnik<sup>3</sup>, Michal Tichy<sup>4</sup>

<sup>1</sup> Department of Pediatric Neurology,

<sup>2</sup> Department of Radiology,

<sup>3</sup> Department of Pathology, Molecular Medicine,

<sup>4</sup> Department of Neurosurgery, Charles University, Second Medical School, Motol Hospital, Prague, Czech Republic

Received June 22, 2011; Accepted January 25, 2012

**ABSTRACT** – We report a girl with a drug-resistant frontal lobe epilepsy caused by focal cortical dysplasia, who exhibited uncommon seizures. The seizures consisted of shoulder or whole body shuddering after a short psychic aura and face grimacing. Consciousness was fully preserved. The seizures resembled “wet dog shake” seizures described in rat models of epilepsy or shuddering attacks in infants. EEG findings were inconclusive, however, MRI showed a clear dysplastic lesion in the right frontal mesial and polar structures. The patient underwent an extended lesionectomy guided by neuronavigation and intraoperative electrocorticography. Focal cortical dysplasia type Ib was histologically confirmed and the patient has been seizure-free for the three years following resection. [*Published with video sequences*]

**Key words:** frontal lobe epilepsy, wet dog shake attacks, focal cortical dysplasia, epilepsy surgery, seizure semiology, shuddering

The semiology of seizures arising from the cingulate gyrus, medial frontal, orbitofrontal, or frontopolar regions is usually characterised by motor symptoms accompanied by emotional feelings and viscerosensory symptoms. Typical hypermotor seizures from this area are characterised by short repetitive thrashing, pedalling, thrusting, laughing, screaming and/or crying (Bancaud and Talairach, 1992; Bleasel and Dinner, 2008; Alexopoulos

and Tandon, 2008). However, the patient presented in this study with frontopolar-frontomesial epilepsy exhibited an atypical seizure type resembling shuddering attacks in infancy or “wet dog shakes” seen in rat models of epilepsy.

Shuddering attacks are benign shivering movements that occur in young children, consisting of rapid shivering of the head, shoulder, and occasionally the trunk (Tibussek *et al.*, 2008). The aetiology of this



**Correspondence:**

Pavel Krsek  
Department of Pediatric Neurology,  
Motol Epilepsy Centre,  
Charles University, 2nd Medical School,  
Motol Hospital,  
V Uvalu 84,  
CZ 15006 Prague 5, Czech Republic  
<pavel.krsek@post.cz>

disorder is unknown and an association with epilepsy has not been reported (Jan, 2010). These events do not require any specific treatment and spontaneous remission is expected.

Wet dog shake behaviour has been studied in multiple rat models of epilepsy. Repeated wet dog shakes occur during limbic seizures in rats with focal epilepsy induced by kindling of limbic structures, as well as kainic acid and pilocarpine models of epilepsy (Rondouin *et al.*, 1987; Shin *et al.*, 2009). This type of epileptic seizure has never been observed in humans. The characterisation of the seizures and localisation of the epileptogenic zone in our case were supported by the fact the resective epilepsy surgery was successful.

## Case report

The female patient was born in 2000 at term without complications. She had no family history of epilepsy or any other neurological disorder and normal development. She suffered a single episode of uncomplicated febrile convulsions at two years of age. The first seizure occurred in February 2006 at the age of six years during uncomplicated gastroenteritis with vomiting, but no fever. Seizures were highly stereotyped, lasting a few seconds, consisting of a facial grimace (described by the patient's mother as "similar to eating a lemon"), followed by the shuddering of the shoulders and body. These behaviours were preceded by an aura described as a strange feeling on her back. Seizure frequency was high from the onset; up to 20 events per day.

The patient was examined by a local neurologist. Her EEG initially revealed no epileptiform abnormality. MRI showed cortical structural and signal changes of the right frontopolar and frontomesial region which were interpreted as a cortical malformation or, less probably, benign brain tumour. Treatment was initiated with valproic acid and subsequently with a combination of valproic acid and lamotrigine with good effect (seizure frequency was reduced to a maximum of five events per day and remained the same over the next five months). In August 2006, however, without any provoking factor, seizure frequency increased markedly up to 70 events per day.

The patient was first admitted to our hospital in October 2006. The neurological examination was unremarkable. Her EEG showed normal background activity and no epileptiform activity during wakefulness. Low-voltage bifrontal spikes appeared during non-REM sleep (*figure 1*). Dozens of short simple partial seizures were captured, consistent with the semiology described. EEG during seizures did not show any ictal/evolving patterns and was frequently obscured by muscle artefacts. High-resolution MRI demonstrated changes typical of focal cortical dysplasia

in the medial orbitofrontal gyrus and frontal pole, with extension to the anterior cingulate gyrus, rostral cortex and caudal and mesial parts of the superior frontal gyrus on the right, showing increased cortical thickness, increased T2 signal in the cortex, and blurred grey/white matter junction (*figures 2 and 3*).

The child's epilepsy became markedly drug-resistant; treatment with valproic acid, carbamazepine, lamotrigine, topiramate and clonazepam in different combinations was ineffective. Seizure frequency varied from 10 to 40 per day. The girl developed a learning disability and her cognitive impairment gradually worsened. Psychological examination confirmed deficits in verbal memory, speech perception, and attention, as well as specific learning disabilities (dyslexia, dysgraphia, dyspraxia, and discalculia).

In November 2007, the patient thus underwent a preoperative diagnostic work-up. The EEG and MRI findings remained unchanged and  $^1\text{H}$  MR spectroscopy using the chemical shift imaging (CSI) technique showed a complex metabolic abnormality in the region of the MRI lesion. Other neuroimaging tests were not performed.

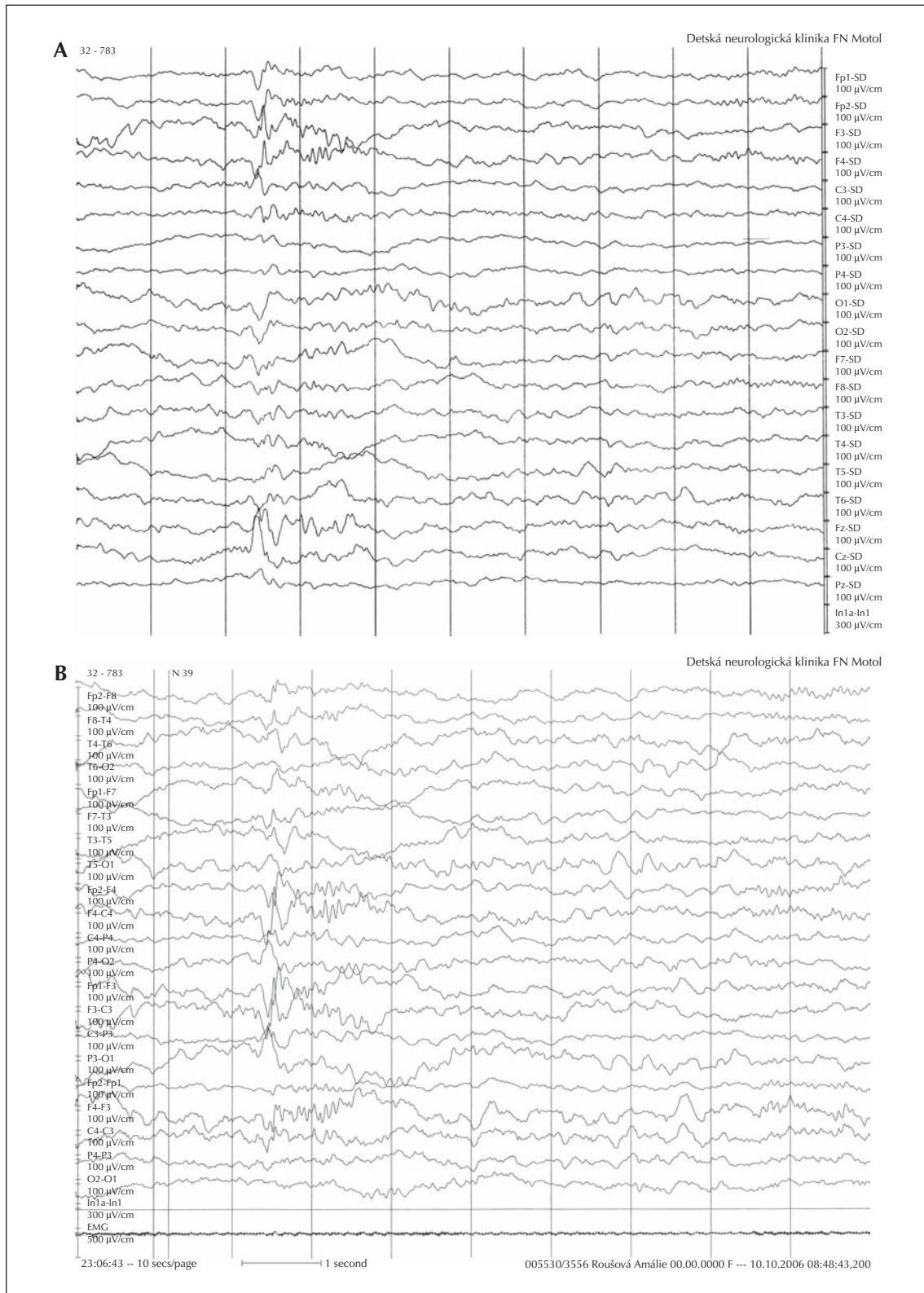
The girl underwent one-stage resective epilepsy surgery in January 2008 which included an extended lesionectomy with neuronavigation and electrocorticography. No neurological deficits were present after surgery. Postoperative MRI revealed the complete removal of the lesion and no complications (*figures 2 and 3*). Histological examination of the resected brain tissue confirmed focal cortical dysplasia (FCD) type Ib (*figure 4*) according to the current classification of FCD (Palmini *et al.*, 2004). Specifically, there was disorganisation of the normal structure of the cerebral cortex, presence of immature neurons, and heterotopic neurons in the white matter.

The patient was followed for more than three years and no seizures were observed to date. Repeated postoperative EEGs were free of epileptiform discharges. During the first few months after surgery, the girl was more tired and her learning disabilities were more emphasized. This was confirmed by the psychological tests. At that time, she was using a combination of carbamazepine and topiramate. After topiramate withdrawal and levetiracetam initiation, neuropsychological testing demonstrated improvement.

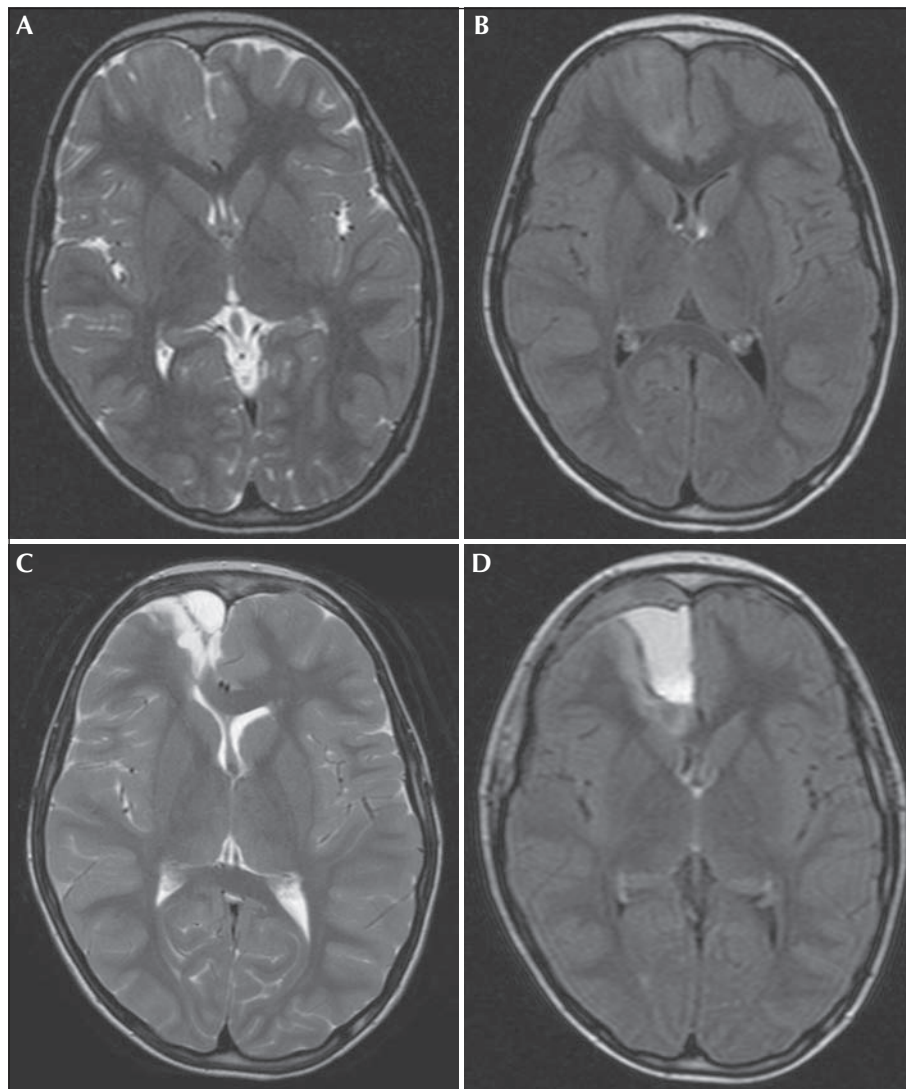
## Discussion

We report an atypical case of frontal lobe epilepsy, with seizures arising from the anterior frontomesial and frontopolar region of the cingulate gyrus.

It is often difficult to document seizures arising from the cingulate and other medial frontal cortex (Devinsky *et al.*, 1995; So, 1998). The "gold standard"



**Figure 1.** Interictal EEG of the patient during non-REM sleep showing low-voltage bilateral mesial frontal spikes. The occurrence of these spikes was very infrequent. **(A)** Source derivation (SD), and **(B)** longitudinal montage. EEG recording settings: sampling rate: 200 Hz; high-pass filter: 0.5 Hz; low-pass filter: 70 Hz; notch filter: 50 Hz.

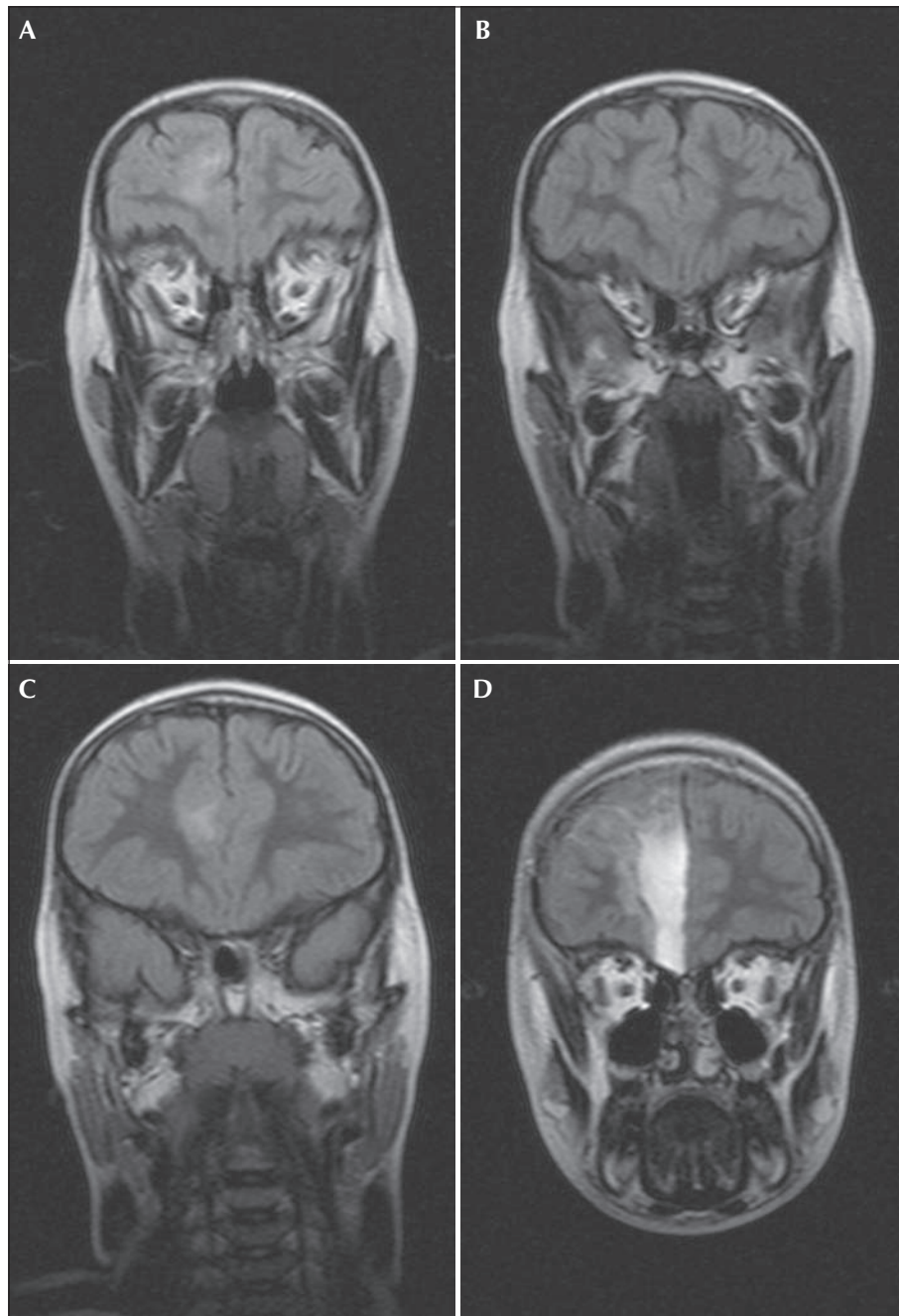


**Figure 2.** High-resolution MRI (transversal plane) of the patient. (A) T2-weighted and (B) FLAIR images. Increased cortical thickness, hyperintense cortical signal changes, and blurred grey/white matter junction, changes typical of FCD, localised to the medial orbitofrontal gyrus and frontal pole with extension to the anterior cingulate gyrus, rostral cortex and caudal and mesial parts of superior frontal gyrus. (C, D) Postoperative MRI; complete resection of the lesion was confirmed.

for demonstrating mesial frontal localisation of the epileptogenic zone is seizure freedom after a relatively restricted cortical resection of that area. Prior to resection, determination of the seizure onset zone requires either intracranial electrodes or neuroimaging methods such as MRI, PET, or ictal SPECT.

Despite these challenges in localising medial frontal and cingulate seizure foci, requiring documentation of seizure semiology, it appears that epilepsy originating from this region is most commonly expressed as one or more of three clinical seizure types: (1) absence, (2) hypermotor, and (3) postural tonic seizures (Williamson, 1992; So, 1998; Bleasel and Dinner, 2008). Other seizure types occur less fre-


quently. Most patients with cingulate epilepsy have an early onset of seizures consisting of brief staring spells and loss of motor tone, often progressing to tonic-clonic activity. Seizures are usually worse during sleep but diurnal events can occur. In later childhood, auras are common and seizures may develop more emotional motor expressions, such as fearful facial expressions or laughter, complex hypermotor automatisms, and lateralised motor phenomena that reflect ictal spread patterns (Vogt, 2009). Typical characteristics of seizures that arise from the frontopolar region include initial loss of consciousness, axial clonic jerks, version of eyes and head, and autonomic symptoms (Williamson, 1992).



**Figure 3.** High-resolution MRI (coronal plane); FLAIR images.

Our case exhibited none of the above mentioned semiological features of seizures arising from the mesial frontal and frontopolar cortex. Moreover, we did not find any literature describing this type of epileptic seizure in humans. Our patient's seizures mostly resembled shuddering attacks. These benign non-epileptic events typically begin in infancy or early childhood. The clinical events consist of rapid shivering of the head, shoulder, and occasionally the trunk.

The events have been reported as brief, usually lasting for not more than a few seconds. Frequency can be up to more than 100 events per day with a great inter- and intra-individual variability. Events have sudden onset and may be accompanied by facial grimacing (Riehl and Mink, 2010). The attacks are not associated with any alteration in consciousness and children tend to resume their previous activity immediately following an episode without apparent distress.



**Figure 4.** Histological findings revealed disorganisation of the normal structure of the cerebral cortex and presence of immature neurons and heterotopic neurons in white matter.

It is necessary to distinguish these episodes from epileptic seizures. The patients do not manifest any EEG abnormalities during the attacks or between the attacks. Video recordings reveal only shivering movement lasting several seconds (Tibussek *et al.*, 2008). The clinical events in our patient were similar to the shuddering attacks, but she did not fulfil the criteria of this diagnosis, mainly because of the age when the episodes started (6 years old). Furthermore, neuropsychological tests demonstrated a decline in cognitive functions in the girl. Cognitive deficits are not associated with shuddering attacks, but are commonly seen in patients suffering from focal intractable epilepsy (Klein *et al.*, 2000).

In addition to shuddering attacks, the clinical events resembled the “wet dog shake” (WDS) seizures described in animal models of epilepsy. This type of abnormal behaviour was reported in various rat models of limbic epilepsy, such as kindling, kainic acid and pilocarpine-induced seizures (Rondouin *et al.*, 1987; Shin *et al.*, 2009) and has never been observed in humans. Two main hypotheses are used to explain the circuitries involved in the expression of WDS behaviour. For the “generalisation hypothesis”, WDS is a marker of the progression of limbic seizures towards generalisation (Rondouin *et al.*, 1987) and for the “anti-convulsant hypothesis”, WDS is the expression of inhibitory processes associated with limbic seizures (Le Gal La Salle and Cavalheiro, 1981; Rodrigues *et al.*, 2005).

The Cingulate cortex is usually considered part of the limbic lobe. It is connected with the limbic structures through the Papez circuit. Moreover, the anterior cingulate cortex is connected reciprocally with the amygdala and it receives direct projections from the hippocampus (Vogt, 2009). However, it should be stressed that there are important differences in manifestation of the seizures between the rat models and human epilepsy.

Our patient’s interictal EEG was normal when awake and showed infrequent bifrontal spikes when asleep. However, scalp EEG findings in patients with mesial frontal seizures are notoriously ambiguous and often non-lateralising or misleading (Bleasel and Dinner, 2008). Interictal discharges generated by the mesial frontal cortex could be seen over both the ipsilateral and contralateral frontal or parietal cortex, or over both temporal lobes. In other cases, the ictal discharge produces a low voltage fast activity and attenuation of the background activity, which is often obscured by muscle artefacts. Scalp EEG recordings without either interictal or ictal epileptiform activity are not infrequent (Bass *et al.*, 1995).

Because EEG localisation of the epileptogenic zone is frequently vague, high-resolution MRI plays a critical role in the evaluation process for epilepsy surgery candidates with mesial frontal epilepsy. In our case, both high-resolution MRI and histopathology clearly proved there was a dysplastic lesion in the right frontopolar and frontomesial region (FCD type Ib

according to the histopathological classification). FCD is a typical cause of focal intractable epilepsy in children (Harvey *et al.*, 2008; Krsek *et al.*, 2008). After resection of the lesion, the patient was rendered seizure-free.

To summarise, this case of frontal lobe epilepsy with unusual clinical manifestations demonstrates the diversity of motor phenomena associated with epileptic activation of the anteromesial frontal lobe. The case also shows that events characterised by “shuddering-like attacks” can have an epileptic origin and is furthermore an example of successful surgical treatment of intractable epilepsy. The radiological evaluation was essential for the choice of treatment options, and we encourage early surgical interventions for appropriately selected patients suffering from lesional epilepsy. □

#### Disclosure.

This work was supported by grants MZOFNM2005-6504 and Kontakt Program ME09042.

#### Legend for video sequence

Typical spontaneous seizures of the child recorded during video/EEG sessions.

#### Key words for video research on [www.epilepticdisorders.com](http://www.epilepticdisorders.com)

*Syndrome:* focal non-idiopathic frontal (FLE)

*Etiology:* focal cortical dysplasia (type I)

*Phenomenology:* face; automotor (distal, mouth or tongue) seizure; shuddering

*Localization:* frontal lobe (right)

#### References

- Alexopoulos AV, Tandon N. Basal frontal lobe epilepsy. In: Lüders HO. *Textbook of epilepsy surgery*. London: Informa Healthcare Ltd, 2008: 285-313.
- Bancaud J, Talairach J. Clinical semiology of frontal lobe seizures. *Adv Neurol* 1992; 57: 3-58.
- Bass N, Wyllie E, Comair Y, Kotagal P, Ruggieri P, Holthausen H. Supplementary sensorimotor area seizures in children and adolescents. *J Pediatr* 1995; 126: 537-44.
- Bleasel A, Dinner D. Mesial frontal epilepsy. In: Lüders HO. *Textbook of epilepsy surgery*. London: Informa Healthcare Ltd, 2008: 274-84.
- Devinsky O, Morrell MJ, Vogt BA. Contributions of anterior cingulate cortex to behaviour. *Brain* 1995; 118: 279-306.
- Harvey AS, Cross JH, Shinnar S, Mathern BW; ILAE Pediatric Epilepsy Surgery Survey Taskforce. Defining the spectrum of international practice in pediatric epilepsy surgery patients. *Epilepsia* 2008; 49: 146-55.
- Jan MM. Shuddering attacks are not related to essential tremor. *J Child Neurol* 2010; 25: 881-3.
- Klein B, Levin B, Duchowny M, Llabre M. Cognitive outcome of children with epilepsy and malformations of cortical development. *Neurology* 2000; 55: 230-5.
- Krsek P, Maton B, Korman B, *et al.* Different features of histopathological subtypes of pediatric focal cortical dysplasia. *Ann Neurol* 2008; 63: 758-69.
- Le Gal La Salle G, Cavalheiro EA. Stimulation of septal and amygdaloid nuclei: EEG and behavioral responses during early development of kindling with special reference to wet dog shakes. *Exp Neurol* 1981; 74: 717-27.
- Palmini A, Najm I, Avanzini G, *et al.* Terminology and classification of the cortical dysplasias. *Neurology* 2004; 62: 2-8.
- Riehl JA, Mink JW. Shuddering attacks. *J Pediatr Neurol* 2010; 8: 25-9.
- Rodrigues MC, Rossetti F, Foresti ML, *et al.* Correlation between shaking behaviors and seizure severity in five animal models of convulsive seizures. *Epilepsy Behav* 2005; 6: 328-36.
- Rondouin G, Lerner-Natoli M, Hashizume A. Wet dog shakes in limbic versus generalized seizures. *Exp Neurol* 1987; 95: 500-5.
- Shin EJ, Jeong JH, Chung YH, *et al.* Decrease in the kainate-induced wet dog shake behavior in genetically epilepsy-prone rats: possible involvement of an impaired synaptic transmission to the 5-HT(2A) receptor. *J Pharmacol Sci* 2009; 110: 401-4.
- So NK. Mesial frontal epilepsy. *Epilepsia* 1998; 39: 49-61.
- Tibussek D, Karenfort M, Mayatepek E, Assmann B. Clinical reasoning: shuddering attacks in infancy. *Neurology* 2008; 70: 38-41.
- Vogt BA. *Cingulate neurobiology and disease*. Oxford : Oxford University Press, 2009.
- Williamson PD. Frontal lobe seizures. Problems of diagnosis and classification. *Adv Neurol* 1992; 57: 289-309.