

Ambulatory non-convulsive status epilepticus evolving into a malignant form

José L Fernández-Torre^{1,2,3}, Peter W Kaplan⁴,
Mariano Rebollo⁵, Agustín Gutiérrez⁶,
Miguel A Hernández-Hernández^{3,7}, José L Vázquez-Higuera⁵

¹ Department of Clinical Neurophysiology, "Marqués de Valdecilla" University Hospital, Santander, Cantabria, Spain

² Department of Physiology and Pharmacology, University of Cantabria, Santander

³ Instituto de Formación e Investigación Marqués de Valdecilla (IFIMAV), Santander

⁴ Department of Neurology, Johns Hopkins University School of Medicine, Johns Hopkins Bayview Medical Center, Baltimore, USA

⁵ Department of Neurology, "Marqués de Valdecilla" University Hospital, Santander

⁶ Department of Radiology, "Marqués de Valdecilla" University Hospital, Santander

⁷ Department of Intensive Medicine, "Marqués de Valdecilla" University Hospital, Santander, Cantabria, Spain

Received May 14, 2011; Accepted January 25, 2012

ABSTRACT – We retrospectively analysed the clinical characteristics, electroencephalogram (EEG) records, brain magnetic resonance imaging (MRI) scans, antiepileptic therapy and prognosis of a case series with ambulatory non-convulsive status epilepticus (NCSE) which evolved into a malignant form (mNCSE). mNCSE was defined as NCSE that continues or recurs five days or more after the onset of general anaesthesia, including those cases where NCSE recurs upon reduction or withdrawal of anaesthetic therapy. Four women and two men were studied. The mean age was 42.8 years (range: 19-63 years). Two of six patients had a previous diagnosis of epilepsy. Four patients died. Two patients had a good outcome with return to consciousness and activities of daily life, and one of these subjects developed temporal lobe epilepsy. In four patients, the cause of mNCSE was encephalitis. Clinical presentation was complex partial status epilepticus (CPSE) in three patients and generalised NCSE (GNCSE) in the other three. Two of the latter had encephalitis and one was diagnosed with progressive myoclonus epilepsy (PME) of Lafora type. The mean duration of the NCSE episode was 47.5 days (range: 9-139 days; SD: 53.1). In three patients, continuous or rhythmic focal epileptiform discharges were the EEG pattern at onset. In the other three, continuous rhythmic generalised spike-wave, polyspike-wave or sharp slow-wave complexes were observed. Antiepileptic treatment was heterogeneous and patients were treated with an average of 6.0 AEDs (range: 3-10; SD: 3.0). In summary, mNCSE is a severe epileptic condition that occurs often in the context of encephalitis or pre-existing epilepsy. Both CPSE and GNCSE may occur. Although high mortality is associated with mNCSE, some patients may survive with normal or good recovery.

Key words: non-convulsive status epilepticus, coma, refractory status epilepticus, anaesthetic drugs, profound sedation

Correspondence:

José L Fernández-Torre
Department of Clinical Neurophysiology,
"Marqués de Valdecilla" University
Hospital,
Avda Valdecilla,
s/n. 39008 Santander, Cantabria, Spain
<jlfernandez@humv.es>
<ftorrenfc@hotmail.com>

Non-convulsive status epilepticus (NCSE) is a pleomorphic and heterogeneous epileptic condition in which behaviour disturbance and level of consciousness may range from minimal to coma (Kaplan, 1999; Fernández-Torre, 2009; Fernández-Torre *et al.*, 2012). Rarely, status epilepticus (SE) may exhibit a malignant course (Holtkamp *et al.*, 2005). However, little attention has been focused on ambulatory or non-comatose patients with partial or generalised refractory NCSE (rNCSE) which may persist with parenteral antiepileptic drugs (AEDs) to the point of remaining resistant to at least one anaesthetic agent, or may relapse during initial treatment and then require profound sedation with anaesthetic drugs.

The purpose of this study is to present the electroclinical features of a group of patients with ambulatory rNCSE which evolved into a malignant form (mNCSE).

Methods

Definition and diagnostic criteria for mNCSE

rNCSE is defined as NCSE which has neither responded to first-line therapy (benzodiazepines) nor second-line therapy, and which, according to the treatment protocols, requires the application of general anaesthesia (propofol, thiopental, pentobarbital or midazolam). mNCSE is defined as NCSE that continues or recurs five days or more after the onset of general anaesthesia, including those cases where NCSE recurs upon reduction or withdrawal of anaesthetic therapy. We employed a modified definition of that recently proposed by Shorvon for super-refractory SE in the third London-Innsbruck Colloquium on SE (Shorvon, 2011; Shorvon and Ferlisi, 2011). Shorvon's definition concerns tonic-clonic SE and not NCSE or *epilepsia partialis continua*. Therefore, we established a distinct frame period of five days following the criteria used by Holtkamp *et al.* (2005) for malignant SE. Interestingly, a recent investigation on very prolonged SE employed a similar duration (Drislane *et al.*, 2011).

All our patients were initially "ambulatory" before developing seizures and were not resident in an intensive care unit (ICU) or in coma. Subjects initially in coma or presenting with convulsive or subtle post-convulsive SE were excluded. In practical terms, they were initially classified as generalised NCSE (GNCSE) or absence status epilepticus (ASE) and complex partial status epilepticus (CPSE). CPSE was also sub-classified into two subtypes (Kaplan, 1996; Fernández-Torre *et al.*, 2012): 1) cyclic CPSE with recurrent complex partial seizures without recovery of consciousness between seizures; and 2) continuous CPSE showing continuous seizure activity.

An important point of this study is the clinical course of the cases; our patients initially demonstrated clinical and electroencephalogram (EEG) evidence of ambulatory NCSE that remained refractory to standard intravenous benzodiazepines (IVBZDs) (e.g. lorazepam or diazepam) and parenteral second-line agents (e.g. phenytoin, valproate or levetiracetam). We consider that during this period, our patients developed rNCSE. Subsequently, they were transferred to the ICU for institution of profound sedation (burst-suppression or flat EEG) with one or more anaesthetic drugs, when necessary. Although epileptiform activity ceased partially or completely during profound sedation, NCSE returned in all when anaesthetic drugs were tapered. Anaesthetic agents were then reintroduced, requiring more than five days to control electroclinical mNCSE.

Patient inclusion

Our observational study included six patients fulfilling the definition criteria for mNCSE. Five patients were studied in the Department of Clinical Neurophysiology at Marqués de Valdecilla University Hospital (HUMV, Spain) during the last nine years and one patient (Case 6) was evaluated in the Department of Neurology at Johns Hopkins Bayview Medical Center (JHBMC, USA) during the past year. Three patients (Cases 3, 4 and 5) were previously investigated and the full description of these patients is documented in a Spanish doctoral thesis, as well as an original research article (Fernández-Torre, 2009; Fernández-Torre *et al.*, 2012). One patient (Case 3) was also previously reported in detail elsewhere (Fernández-Torre *et al.*, 2006). However, this cohort was not previously analysed for electroclinical characteristics that lead to this new designation of severity (mNCSE) which may still result in favourable outcomes with minor neuroimaging anomalies, despite prolonged treatment with profound sedation in the ICU.

Electroencephalography

EEG recordings were performed with 21 scalp electrodes placed according to the international 10-20 system. A continuous EEG or video-EEG recording was obtained for at least 30 minutes including multimodal (somatosensory, auditory, and photic) stimulation in non-comatose and comatose individuals. Special attention was focused on the distinction between rhythmic and periodic patterns. "Rhythmic" was defined as repetition of waveform with relatively uniform morphology and duration, with no interval between consecutive waveforms. In contrast, "periodic" was defined identically but with

a quantifiable interval between discharges (Hirsch, 2011). In both cases, this EEG pattern involved at least 80% of the recording. This protocol was approved by the local ethics committee.

Data collection

All clinical data were gathered from chart review, EEG reports and protocols, discharge summaries, and resident sign-out notes. Baseline demographic data (age and gender) and medical history were recorded. In all cases, subsequent follow-up EEGs were performed.

The onset of NCSE was considered to be the moment in which the first EEG confirmed the presence of ongoing seizures. The final time of cessation of the episode of NCSE was determined by the clear improvement in mental state and resolution of clinical symptoms accompanied by an EEG regression of seizure activity.

Results

Six patients were identified with the diagnosis of mNCSE. Classification and all demographic, clinical, and neuroimaging features are summarised in *table 1*. Patients included four women and two men. The mean age was 42.8 years (range: 19-63 years). All six patients were transferred to the ICU for treatment of NCSE and institution of parenteral anaesthetic agents under optimal support and environment. The duration of treatment with AEDs before profound sedation varied from 12 hours (Case 5) to 25 days (Case 1) (*table 2*). In

one patient (Case 5), a drastic and severe worsening of consciousness due to GNCSE was the cause of early admission to the ICU. In contrast, the presence of mild changes in mental status at onset and a limited episode of CPSE were considerations for the late ICU admission in another patient (Case 1). Titration of anaesthetic anticonvulsants to at least a burst-suppression pattern was performed in all cases. Moreover, in four (Cases 1, 2, 4 and 6), profound sedation was increased until a flat-line EEG recording was obtained.

Two of six (Cases 1 and 4) had a previous diagnosis of epilepsy. One had post-traumatic epilepsy (Case 1) and another had progressive myoclonus epilepsy (PME) with Lafora disease (Case 4), initially diagnosed as juvenile myoclonic epilepsy. For the PME patient, a genetic study showed a mutation in the *EPM2* gene.

In three subjects (Cases 1, 2 and 6), the clinical presentation included either continuous (Case 1) or cyclic (Case 2 and 6) CPSE. The PME patient (Case 4) had a generalised tonic-clonic seizure followed by an episode of refractory, atypical ASE. Finally, two patients (Cases 3 and 5) were transferred to the ICU because of a progressive decline of consciousness and generalised epileptiform discharges on the EEG, in keeping with the diagnosis of GNCSE.

In four patients (Cases 2, 3, 5 and 6), the cause of mNCSE was encephalitis. Encephalitis was defined as fever with altered sensorium for at least 24 hours with cerebrospinal fluid (CSF) pleocytosis and/or raised proteins. In two patients (Cases 5 and 6), CSF white blood cell count was 300/mm³ and 20/mm³,

Table 1. Clinical and neuroradiological characteristics of patients.

Patient	Sex/age	Cause	Clinical presentation	NCSE type at ICU	Neuroimaging
1	M/59	Post-traumatic epilepsy	Continuous CPSE	FSG	MRI: Residual temporal resection
2	F/63	Encephalitis	Cyclic CPSE	FSG	MRI: Bilateral temporal enhancement
3	M/55	Encephalitis	GNCSE	Generalised	MRI: Right basal ganglia hypodensity*
4	F/19	PME Lafora type	GTCS, atypical ASE	Generalised	MRI: Diffuse cortical atrophy
5	F/39	Encephalitis	GNCSE	Generalised	MRI: Diffuse brain oedema; temporo-insular atrophy (follow-up of 5 years)
6	F/22	Encephalitis	Cyclic CPSE	Focal	MRI: Minimal right temporal enhancement; right mesio-temporal sclerosis (follow-up of 18 months)

ASE: absence status epilepticus; CPSE: complex partial status epilepticus; FSG: focal secondary generalised; GTCS: generalised tonic-clonic seizure; GNCSE: generalised non-convulsive status epilepticus; MRI: magnetic resonance imaging; PME: progressive myoclonus epilepsy;

(*) necrotising leukoencephalopathy was observed by necropsy.

Table 2. Duration of treatment before sedation, total duration of mNCSE episode, antiepileptic and sedative therapy, complications and outcome.

Patient	Duration of treatment before sedation	Total duration of mNCSE	Treatment	Complications at ICU	Outcome
1	25 days	139 days	PHT, CLZ, OXC, CBZ, VPA, LEV, TPM, PB, LTG, VGB, PPF, MDZ, THP, lidocaine, ketamine, ECT, surgery	Jugular thrombosis, urinary infection, pressure ulcers, multiorgan failure [†]	Fatal
2	1 day	9 days	PHT, LEV, CLZ, PPF, MDZ	Digestive haemorrhage, ileus, septic shock, multiorgan failure [†]	Fatal
3	3 days	15 days	PHT, CLZ, VPA, PPF, MDZ	Broncho-pneumonia, septic shock [†]	Fatal
4	2 days	86 days	VPA, CLZ, LTG, PHT, PB, LEV, TPM, ESM, ZNS, PPF, MDZ, THP, IVIg	Superior vena cava syndrome; mesenteric thrombosis [†]	Fatal
5	12 hours	19 days	PHT, PB, VPA, CLZ, PPF, THP, steroids	Respiratory infection, renal failure, CIP	Good
6	4 days	17 days	LZP, PHT, VPA, LEV, TPM, LCS, MDZ, PPF, PBT, PB, steroids	Congestive heart failure, pneumonia	Good

CBZ: carbamazepine; CIP: critical illness polyneuropathy; CLZ: clonazepam; ECT: electroconvulsive therapy; ESM: ethosuximide; IVIg: intravenous immunoglobulins; LCS: lacosamide; LEV: levetiracetam; LZP: lorazepam; LTG: lamotrigine; MDZ: midazolam; OXC: oxcarbazepine; PB: phenobarbital; PBT: pentobarbital; PHT: phenytoin; PPF: propofol; THP: thiopental; TPM: topiramate; VPA: valproate; VGB: vigabatrin; ZNS: zonisamide; [†]clinical cause of death.

respectively. In contrast, two patients (Cases 2 and 3) had a low CSF white blood cell count, but in one (Case 3) a brain biopsy was reported to be in keeping with non-specific necrotising encephalitis (Fernández-Torre *et al.*, 2006). The presence of infective organisms was not confirmed for any of the patients. Autoimmune or paraneoplastic causes of encephalitis were not identified. In two (Cases 2 and 3), encephalitis emerged in the setting of an underlying haematological disorder. In these patients, there was a previous diagnosis of follicular lymphoma (Case 2) and chronic refractory lymphatic leukaemia type B (Case 3), respectively. Neuroimaging anomalies were minor in all patients (table 1). Temporal enhancement was observed in two patients (Cases 2 and 6), diffuse brain oedema in one (Case 5) and diffuse cortical atrophy in another (Case 4). In one patient (Case 1), only changes compatible with a residual temporal resection were observed. In another (Case 3), MRI disclosed a hypodense lesion localised to the right basal ganglia and basal portion of the temporal lobe and insula. These minor changes contrast with the severity of those described in subjects with comatose NCSE (Fernández-Torre *et al.*, 2012).

All ictal EEG features, duration of the episode, treatment and outcome are summarised in tables 2 and 3. In all subjects with rhythmic generalised epileptiform discharges, except that with PME, the frequency varied between 1.5 and 3.0 Hz (figure 1). In four patients (Cases 1-4), generalised periodic epileptiform discharges (GPEDs) were observed after the institution of anaesthesia (figure 2). In one patient (Case 4), NCSE remained intractable until death. In contrast, in another three patients (Cases 1, 2 and 3), mNCSE was finally controlled and EEGs revealed findings in keeping with moderate or severe diffuse encephalopathy. The mean duration of the NCSE episode was 47.5 days (range: 9-139 days; SD: 53.1). Antiepileptic treatment was heterogeneous and patients were treated with an average of 6.0 AEDs (range: 3-10; SD: 3.0). Anaesthetics employed were propofol ($n=6$), midazolam ($n=5$), thiopental sodium ($n=3$), and pentobarbital sodium ($n=1$). Significant medical complications during the ICU admission are given in table 2. Four patients died during the course of mNCSE; the clinical causes of death are mentioned in table 2. Post mortem examination revealed multifocal necrotising leukoencephalopathy in one (Case 3) (Fernández-Torre

Table 3. EEG findings at onset and during evolution of mNCSE.

Patient	EEG pattern at onset	EEG pattern during evolution
1	Continuous rhythmic focal EDs	GPEDs (PSIDDs)
2	Recurrent Szs arising from the right temporal lobe	Continuous rhythmic generalised SWC, 1.5-2.5Hz GPEDs (PSIDDs); right frontal Szs
3	Continuous rhythmic SSWC, 2-2.5Hz	GPEDs (PSIDDs)
4	Continuous rhythmic generalised PSWC/SWC, 3-6Hz	SIRPIDs*; GPEDs (PSIDDs)
5	Continuous rhythmic generalised SWC/SSWC, 2-3Hz	No other pattern
6	Szs arising from the right temporal area, spreading to left side	BiPLEDs

BiPLEDs: bilateral independent periodic epileptiform discharges; EDs: epileptiform discharges; GPEDs: generalised periodic epileptiform discharges; PSIDDs: periodic short-interval diffuse discharges; PSWC: polyspike-wave complexes; SIRPIDs: stimulus-induced rhythmic, periodic, ictal discharges; SWC: spike-wave complexes; SSWC: sharp slow-wave complexes; Szs: seizures.

*A figure showing an example of SIRPIDs of patient 4 can be found in Fernández-Torre *et al.* (2012).

et al., 2006). Unfortunately, autopsy was not authorised in two patients (Cases 1 and 4) and results were not available in another (Case 2). In contrast, two patients (Cases 5 and 6) were discharged with a normal neurological examination and marked recovery of activities of daily life. The follow-up for these patients was five years and 18 months, respectively. One of the subjects (Case 5) developed bilateral diffuse and symmetric temporo-insular atrophy and the other (Case 6) had refractory temporal lobe epilepsy with subsequent right mesio-temporal sclerosis (*table 2*).

Illustrative clinical cases

Case 1

A 59-year-old man with antecedents of severe cranial trauma, right-sided temporal craniotomy and post-traumatic epilepsy was admitted to our emergency unit because of slowness in mental activity and alteration of behaviour. An urgent portable EEG showed continuous seizure activity arising from the right posterior temporal region (continuous CPSE) (*figure 3A*). After the administration of IVBZDs, a marked reduction of focal epileptiform discharges accompanied by mild clinical improvement was observed (*figure 3B*). Brain computed tomography (CT) and MRI did not reveal modifications in relation to his previous neuroimaging studies and acute cerebral lesions were ruled out. He was transferred to the neurological ward and treatment with intravenous phenytoin and benzodiazepines was started. During the following 25 days, CPSE remained refractory despite treatment with several conventional AEDs including carbamazepine, oxcarbazepine, valproate, clonazepam, phenobarbital,

and levetiracetam. He became stuporous and, finally, was transferred to the ICU where general anaesthesia was initiated. Despite the use of anaesthetic therapy, focal secondary GNCSE remained intractable for the next four months. During this period, diverse combinations of conventional AEDs, lidocaine, ketamine, electroconvulsive therapy and, finally, surgery were employed without clinical improvement (*table 2*). A pattern of GPEDs occurred frequently following the withdrawal of anaesthetic drugs (*figure 2*). Autoimmune, infectious or paraneoplastic causes were not demonstrated. He never awoke, however, a few days before his death, an EEG revealed cessation of epileptiform activity and severe diffuse encephalopathy. He died as a result of multiorgan failure. Unfortunately, necropsy was not authorised.

Case 2

A 63-year-old woman with a previous diagnosis of follicular lymphoma (stage III/IV) was admitted to our department with intermittent fever, lethargy, and confusion. Brain CT was normal. An urgent EEG showed recurrent complex partial seizures arising from the right temporal lobe (cyclic CPSE). A lumbar puncture disclosed two white cells (100% lymphocytes), 55 mg/dL of proteins and 125 mg/dL of glucose. The patient's mental status did not improve after IVBZDs. Treatment with phenytoin was started. Twenty hours later, she experienced one tonic-clonic seizure and her level of consciousness worsened. She was transferred to the ICU where an EEG revealed findings in keeping with focal secondary GNCSE (*figure 1A*). During the next nine days, focal secondary GNCSE remained intractable to conventional

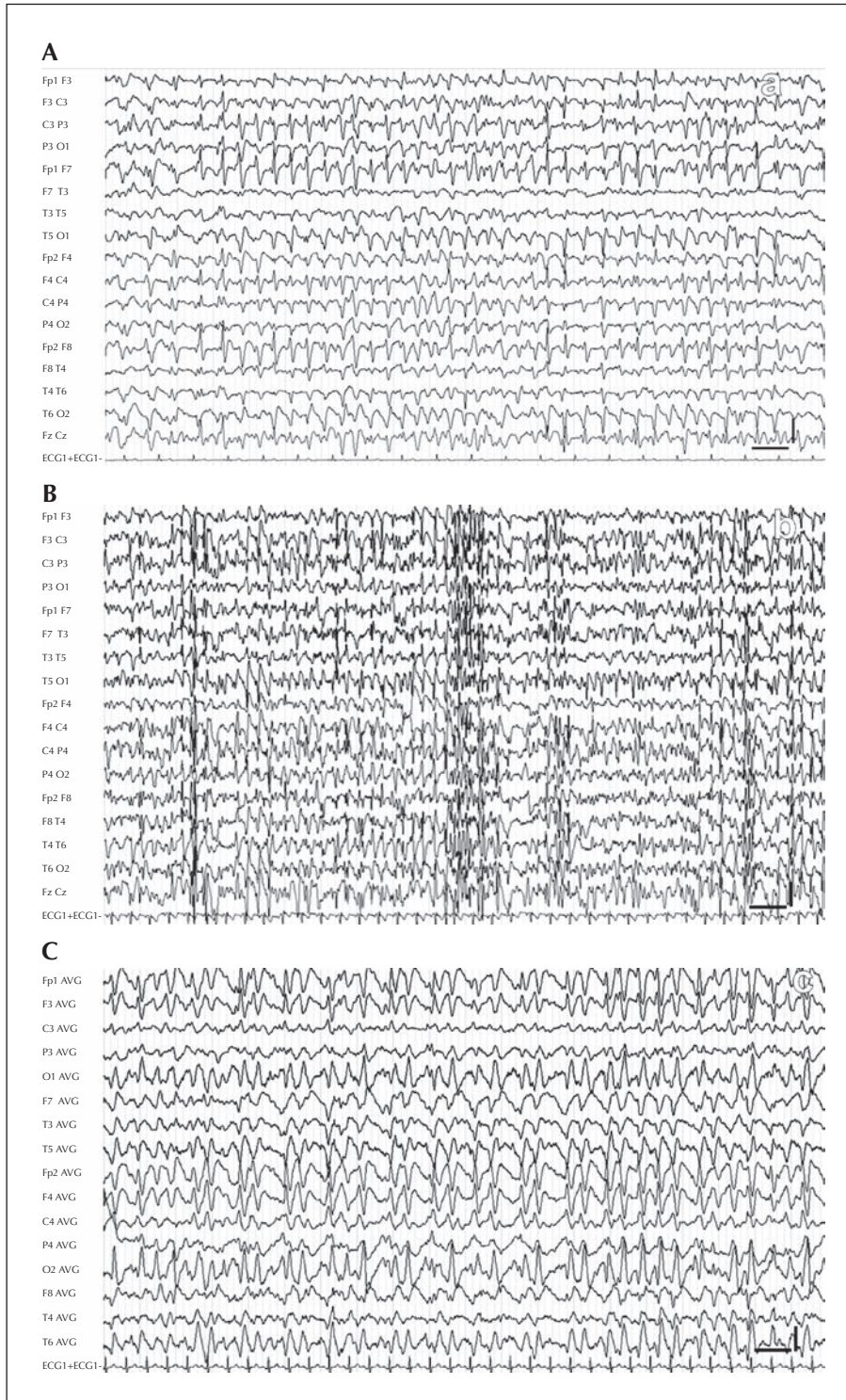


Figure 1. EEGs showing continuous generalised frank epileptiform discharges, in keeping with the diagnosis of GNCSE in coma. (A) EEG recording of Patient 2. (B) EEG recording of Patient 4 diagnosed with PME of Lafora type. (C) EEG recording of Patient 5; note that in this case the frequency of epileptiform discharges was less than 3.0 Hz. Low filter: 0.5 Hz; high filter: 30 Hz; notch filter: 50 Hz; vertical bar: 100 μ V; horizontal bar: 1 second.

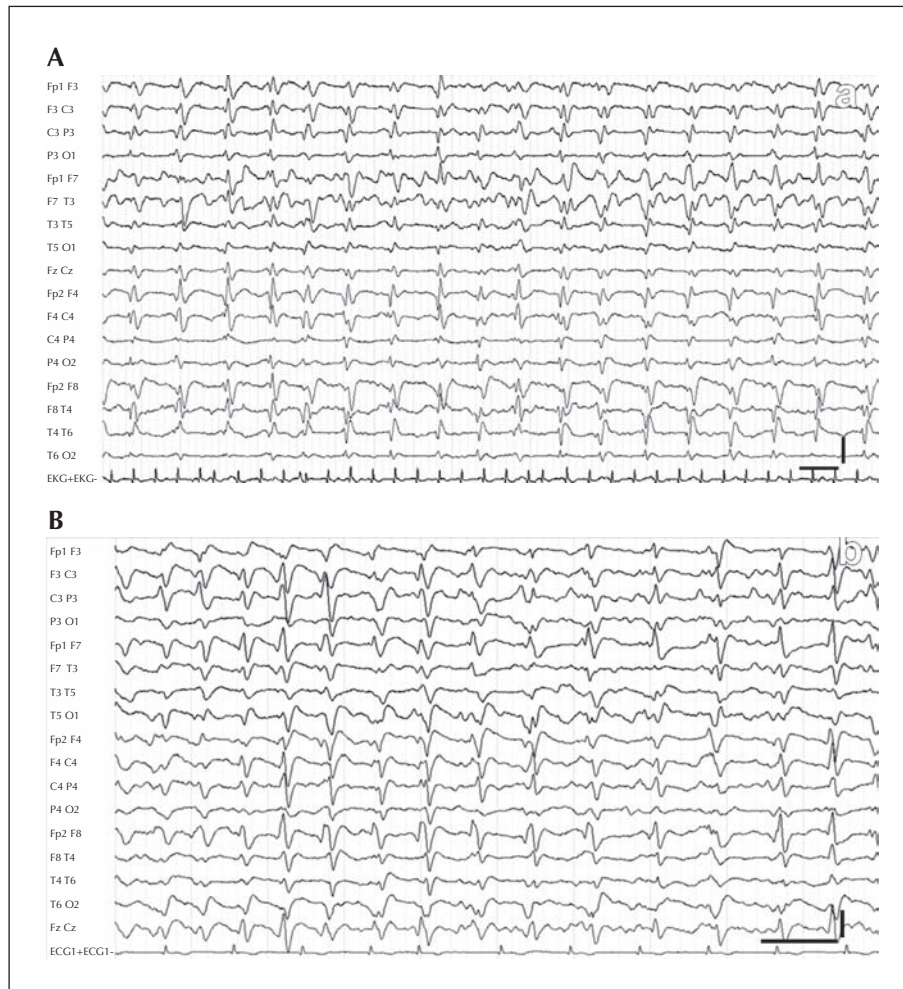


Figure 2. Continuous generalised periodic epileptiform discharges (GPEDs) each occurring for one second in Patients 1 (A) and 2 (B). Low filter: 0.5 Hz; high filter: 30 Hz; notch filter: 50 Hz; vertical bar: 100 μ V; horizontal bar: 1 second.

AEDs and anaesthetic therapy (table 2). Brain MRI disclosed bilateral temporal enhancement but was otherwise normal. Finally, an EEG was compatible with moderate diffuse encephalopathy. She died of septic complications and multiorgan failure 20 days later.

Discussion

Our study highlights the existence of malignant cases of NCSE in ambulatory or non-comatose subjects, which may result in favourable outcomes and minor neuroimaging anomalies, despite prolonged and intensive ICU treatment with standard AEDs followed by anaesthetic coma. mNCSE occurred more frequently with encephalitis or pre-existing epilepsy and despite its refractory nature, it may have a good outcome. mNCSE should therefore not be considered as a *hopeless* condition.

Although non-comatose forms of NCSE are considered to warrant acute and urgent treatment, conventional intravenous AEDs are usually sufficient to control NCSE. Recently, a study concluded that a clinical response to acute IVBZDs in patients with NCSE is predictive of survival and better functional recovery (Hopp *et al.*, 2011). Although this is also our feeling, it did not occur in Case 1. Our case series and the literature highlight the fact that highly intractable and super-refractory forms may be encountered. Of note, CPSE was the most common clinical presentation. This feature confirms other reports of CPSE occurring with refractory SE and malignant SE (Holtkamp *et al.*, 2005). The presence of triggering encephalitis, focal cerebral lesions, or focal epilepsy could explain this higher incidence of CPSE. Nevertheless, in three patients (Cases 3, 4 and 5), a pattern of GNCSE was observed. Two of these three (Cases 3 and 5) had encephalitis and one (Case 4) was diagnosed with PME of Lafora type.

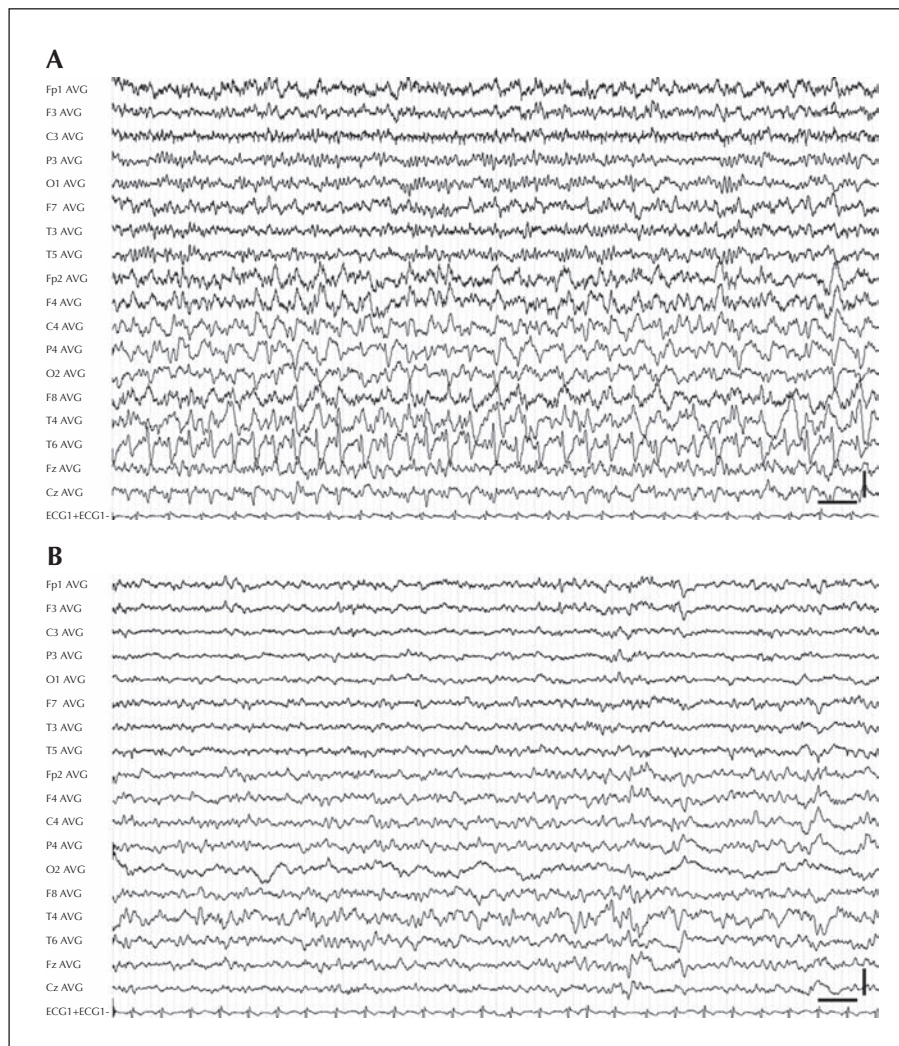


Figure 3. First EEG carried out in Patient 1. **(A)** Note the presence of continuous spikes and spike-wave complexes involving the right hemisphere, maximum in the posterior temporal region (continuous CPSE). **(B)** Complete abolition of epileptiform discharges following the intravenous administration of 4 mg of diazepam, accompanied by slight clinical improvement. Low filter: 0.5 Hz; high filter: 30 Hz; notch filter: 50 Hz; vertical bar: 100 μ V; horizontal bar: 1 second.

It is most likely that a multifocal disease such as encephalitis often causes focal secondary GNCSE.

Two patients had a history of haematological disorders. It is well-known that NCSE is not a rare neurological complication in subjects with cancer (Drislane, 1994; Cocito *et al.*, 2001; Blitshteyn and Jaekle, 2006). Both the occurrence of CNS infections in the context of immunosuppression and neurotoxicity secondary to the chemotherapy may notably contribute to the frequency of this complication and its poor prognosis (both patients died).

The duration of mNCSE varied from 9 to 139 days. In our study, two patients (Cases 5 and 6) were discharged with a normal or markedly improved neurological examination after 19 and 17 days of EEG-confirmed

mNCSE, respectively. One patient (Case 6), after cessation of EEG-confirmed mNCSE, progressed with independent activities of daily life only after several further weeks. An important finding is that one patient (Case 5) resumed an entirely normal life without residual consequences, while another (Case 6) developed temporal lobe epilepsy. Both patients clearly demonstrate that normal or independent living states can be achieved despite the highly intractable nature of mNCSE, prolonged ICU inpatient stays, and a heavy medication burden. This underscores the point that such cases should not be regarded as *hopeless*, particularly as the length of intensive treatment continues without seizure resolution. Interestingly, other investigators have obtained similar conclusions

(Mirski *et al.*, 1995; Nagayama *et al.*, 2005; Dara *et al.*, 2006; Cooper *et al.*, 2009; Drislane *et al.*, 2009; Fernández-Torre, 2010; Johnson *et al.*, 2010; Drislane *et al.*, 2011; Bausell *et al.*, 2011). Mirski *et al.* (1995) reported recovery of consciousness and significant neurological function in a young male with possible viral encephalitis after more than 53 days in a therapeutic barbiturate coma. Dara *et al.* (2006) described a case of refractory SE for more than nine weeks, secondary to presumptive lupus cerebritis. They highlighted the need for continuous aggressive therapy when neuroimaging remains normal. Most recently, Drislane *et al.* (2011) compared clinical features of 10 survivors of prolonged SE with 11 non-survivors. They found that presentation in coma and the existence of multiple medical problems were predictive factors for unfavourable evolution. However, these investigators highlighted that predictive factors for outcome are not completely reliable and individual considerations may significantly modify the final prognosis.

The low number of patients in this case series precludes any statistical predictions of favourable risk factors, however, it was noted that both patients with good outcome had encephalitis without superimposed immunosuppression and absence of severe lesions on MRI studies.

The mortality rate (66%) in our study was notably high. This could have been a consequence of the severity of illness and state of immunocompetence in our patients. One patient suffered from a fatal degenerative disease and two were severely immunosuppressed. Both survivors in our series were diagnosed with encephalitis, which, if mild, may account for a favourable outcome, despite being highly irritative and hence causing epileptic discharges which are difficult to control. Indeed, Nagayama *et al.* (2005) described five adult subjects with persistent but reversible coma, secondary to viral or brainstem encephalitis. Interestingly, one of these patients had NCSE of CPSE type. These authors concluded that post-encephalitic coma, even complicated with NCSE, should not be regarded as *hopeless* in terms of recovery of consciousness. This high incidence of encephalitis in cases of mNCSE was also noted by Holtkamp *et al.* (2005) who found this aetiology to be a frequent cause of malignant SE in general. Generalised periodic EEG anomalies occurred during the evolution of both CPSE and GNCSE (Cases 1-4). These EEG features appear frequent in situations of mNCSE. Interestingly, in all these patients, persistent GPEDs appeared after the introduction of anaesthetic treatment and onset of profound sedation. Under these circumstances, it can be very difficult to know if the patient has only NCSE or, in contrast, whether severe irreversible brain damage or encephalopathy has also emerged. Of note, all our patients revealing this EEG pattern died. Although the pathophysiology of

these EEG features remains speculative, interestingly, in the third London-Innsbruck Colloquium on status epilepticus held in Oxford, Amzica (2011) described the occurrence of pseudo-rhythmic “spiky” waves (self-oscillatory activities) termed “n-complexes” in animals that underwent high levels of deep anaesthesia. The origin of this type of activity was found in the hippocampus. These results suggest that the progressive abolition of cortical activities with increased depth of coma is paralleled by an opposite evolution in the hippocampus (Amzica, 2011). The repercussion of these findings, with regards to the interpretation of EEGs of patients with refractory or malignant SE that underwent profound sedation, remains unknown. Moreover, in several of the unequivocal cases of NCSE reported here, including one case with complete recovery, rhythmic epileptiform discharges had a frequency of less than 3 cycles/second. This feature is interesting, taking into account that a secondary criterion (improvement or appearance of normal alpha) is required for diagnosis of non-convulsive seizures in comatose subjects when repetitive sharp-slow wave complexes occur in a frequency less than 3 cycles/second (Chong and Hirsch, 2005; Jirsch and Hirsch, 2007). Obviously, although this secondary criterion was not completely fulfilled in some of our patients, they clearly demonstrated NCSE. Our findings therefore suggest that we do not have to be excessively dogmatic in the interpretation of EEG patterns and that accurate electroclinical correlation and EEG monitoring are the clue to reaching a definitive and accurate diagnosis.

Conclusion

In summary, mNCSE is a severe epileptic condition that often occurs in the context of encephalitis or pre-existing epilepsy, in which both CPSE and GNCSE may occur. Although high mortality is associated with mNCSE, some patients may survive with “normal” or good recovery. □

Disclosures.

The authors thank the neurologists and intensive care personnel who referred the patients.

This investigation was partially presented as poster at the 3rd London-Innsbruck Colloquium on Acute Seizures and Status Epilepticus, held in Oxford, April 2011.

None of the authors has any conflict of interest to disclose.

References

Amzica F. Cellular mechanisms underlying EEG waveforms during coma. The 3rd London-Innsbruck colloquium on acute seizures and status epilepticus. Oxford, April 2011. *Epilepsia* 2011; 52: 25-7.

- Bausell R, Svoronos A, Lennihan L, Hirsch LJ. Recovery after severe refractory status epilepticus and 4 months of coma. *Neurology* 2011; 77: 1494-5.
- Blitshteyn S, Jaeckle KA. Nonconvulsive status epilepticus in metastatic CNS disease. *Neurology* 2006; 66: 1261-3.
- Chong DJ, Hirsch LJ. Which EEG patterns warrant treatment in the critically ill? Reviewing the evidence for treatment of periodic epileptiform discharges and related patterns. *J Clin Neurophysiol* 2005; 22: 79-91.
- Cocito L, Audenino D, Primavera A. Altered mental state and nonconvulsive status epilepticus in patients with cancer. *Arch Neurol* 2001; 58: 1310.
- Cooper AD, Britton JW, Rabinstein AA. Functional and cognitive outcome in prolonged refractory status epilepticus. *Arch Neurol* 2009; 66: 1505-9.
- Dara SI, Tungpalan LA, Manno EM, et al. Prolonged coma from refractory status epilepticus. *Neurocrit Care* 2006; 4: 140-2.
- Drislane FW. Nonconvulsive status epilepticus in patients with cancer. *Clin Neurol Neurosurg* 1994; 96: 314-8.
- Drislane FW, Blum AS, Lopez MR, Gautam S, Schomer DL. Duration of refractory status epilepticus and outcome: loss of prognostic utility after several hours. *Epilepsia* 2009; 50: 1566-71.
- Drislane FW, Lopez MR, Blum AS, Schomer DL. Survivors and nonsurvivors of very prolonged status epilepticus. *Epilepsy Behav* 2011; 22: 342-5.
- Fernández-Torre JL. *Clinical and electroencephalographic characteristics of nonconvulsive status epilepticus in adults*. Doctoral Thesis. University of Cantabria, 2009.
- Fernández-Torre JL. Prognostic utility of duration in refractory nonconvulsive status epilepticus. *Epilepsia* 2010; 51: 319.
- Fernández-Torre JL, Arce F, Martínez-Martínez M, González-Rato J, Infante J, Calleja J. Necrotizing leukoencephalopathy associated with nonconvulsive status epilepticus and periodic short-interval diffuse discharges: a clinicopathological study. *Clin EEG Neurosci* 2006; 37: 50-3.
- Fernández-Torre JL, Rebollo M, Gutiérrez A, López-Espadas F, Hernández-Hernández MA. Nonconvulsive status epilepticus in adults: electroclinical differences between proper and comatose forms. *Clin Neurophysiol* 2012; 123: 244-51. doi:10.1016/j.clinph.2011.06.020.
- Hirsch LJ. Classification of EEG patterns in patients with impaired consciousness. *Epilepsia* 2011; 52: S21-4.
- Holtkamp M, Othman J, Buchheim K, Masuhr F, Schielke E, Meierkord H. A "malignant" variant of status epilepticus. *Arch Neurol* 2005; 62: 1428-31.
- Hopp JL, Sanchez A, Krumholz A, Hart G, Barry E. Nonconvulsive status epilepticus. Value of a benzodiazepine trial for predicting outcomes. *The Neurologist* 2011; 17: 325-9.
- Jirsch J, Hirsch LJ. Nonconvulsive seizures: developing a rational approach to the diagnosis and management in the critically ill population. *Clin Neurophysiol* 2007; 118: 1660-70.
- Johnson N, Henry C, Fessler A, Dalmau J. Anti-NMDA receptor encephalitis causing prolonged nonconvulsive status epilepticus. *Neurology* 2010; 75: 1480-2.
- Kaplan PW. Nonconvulsive status epilepticus in the emergency room. *Epilepsia* 1996; 37: 643-50.
- Kaplan PW. Assessing the outcomes in patients with nonconvulsive status epilepticus: nonconvulsive status epilepticus is underdiagnosed, potentially overtreated, and confounded by comorbidity. *J Clin Neurophysiol* 1999; 16: 341-52.
- Mirski MA, Williams MA, Hanley DF. Prolonged pentobarbital and phenobarbital coma for refractory generalized status epilepticus. *Crit Care Med* 1995; 23: 400-4.
- Nagayama M, Matsushima K, Nagayama T, Shinohara Y. Persistent but reversible coma in encephalitis. *Neurocrit Care* 2005; 2: 252-7.
- Shorvon S. Super-refractory status epilepticus: an approach to therapy in this difficult clinical situation. The 3rd London-Innsbruck colloquium on acute seizures and status epilepticus. Oxford, April 2011. *Epilepsia* 2011; 52: S53-6.
- Shorvon S, Ferlisi M. The treatment of super-refractory status epilepticus: a critical review of available therapies and a clinical treatment protocol. *Brain* 2011; 134: 2802-18.