

Intracranial localisation of ictal urinary urge epileptogenic zone to the non-dominant temporal lobe

Khatuna Gurgenchvili¹, Shavonne L Massey², Mitzie Grant³, Joseph Piatt Jr⁴, Agustin Legido⁵, Ignacio Valencia⁵

¹ Department of Neurology, Hahnemann University Hospital, Drexel University College of Medicine

² Department of Pediatrics, St. Christopher's Hospital for Children

³ Departments of Psychiatry and Pediatrics, Drexel University College of Medicine

⁴ Section of Neurosurgery, Department of Surgery, St. Christopher's Hospital for Children

⁵ Section of Neurology, Department of Pediatrics, St. Christopher's Hospital for Children, Philadelphia, USA

Received March 27, 2011; Accepted November 24, 2011

ABSTRACT – Ictal urinary urge is a rare symptom of focal epilepsy usually localising to the non-dominant hemisphere, specifically, the temporal lobe. Lateralisation in previously described cases has been established using scalp video-EEG monitoring or functional imaging. We report the case of a 19-year-old girl with refractory epilepsy and ictal urinary urge arising from the non-dominant temporal lobe, confirmed by invasive, subdural EEG monitoring. Since undergoing a temporal lobectomy two and a half years ago, the patient has not experienced ictal urinary urge. To our knowledge, this is the first report demonstrating localisation of ictal urinary urge epileptogenic zone to the non-dominant temporal lobe by invasive intracranial monitoring.

Key words: ictal urinary urge, seizure, visceral aura, non-dominant temporal lobe, localisation, invasive EEG

Ictal urinary urge is a clinical manifestation of a partial seizure characterised by an intense desire to urinate, described in temporal lobe epilepsy (Baumgartner *et al.*, 2000; Janszky *et al.*, 2007; Loddenkemper *et al.*, 2003; Loddenkemper and Kotagal, 2005). Previous reports have described this seizure type as arising from the non-dominant hemisphere, specifically the temporal lobe (Baumgartner *et al.*, 2000; Baumgartner *et al.*, 2001; Loddenkemper *et al.*, 2003; Loddenkemper and Kotagal, 2005). Single photon emission computed tomography (SPECT) studies demonstrate hyperperfusion of the insula and the superior temporal gyrus during ictal urinary urge (Baumgartner *et al.*, 2001) and lateralisation has been documented by surface video-electroencephalography (EEG), magnetic resonance

Correspondence:

Ignacio Valencia
Section of Neurology,
St Christopher's Hospital for Children,
Erie Avenue at Front Street,
Philadelphia, PA 19134, USA
<Ignacio.Valencia@drexelmed.edu>

imaging (MRI), positron emission tomography (PET), and ictal SPECT (Baumgartner *et al.*, 2000; Janszky *et al.*, 2007; Loddenkemper *et al.*, 2003). The objective of this case report was to describe confirmed, invasive evidence of a urinary urge epileptogenic zone localising to the non-dominant temporal lobe.

Case report

The patient was a 19-year-old left-handed female with a history of left fronto-nasal encephalocele, subependymal nodular heterotopia, and widespread left cortical dysplasia, described in our previous manuscript (Rojas *et al.*, 2006). She had her first seizure at age 13 and was presented to us at age 15 with a two-year history of seizures. The episodes were characterised by an intense desire to urinate, followed by dystonic posturing of the right arm. Right-sided tingling was reported 5-10 seconds later, which was followed by head/eye version and impaired cognition. The episodes occurred three to four times per month. Two years after, the patient's epilepsy became intractable and pharmacotherapy was unsuccessful with four antiepileptic medications, including oxcarbazepine, topiramate, valproic acid, and levetiracetam. Her early developmental history was unremarkable and she was reported to have had normal school performance until onset of her seizures. Her neurological examination was unremarkable, with the exception that her dominant left hand was slightly stronger than her right. She had fluent speech and results of a brief cognitive evaluation revealed average, age-appropriate short-term verbal memory with low average vocabulary and short-term visual memory.

The patient was admitted to St. Christopher's Hospital for Children where scalp video-EEG monitoring captured three typical clinical seizures with electrographic correlate with left hemispheric onset, possibly over the temporal lobe (*figure 1*). Given her lack of response to multiple antiepileptic medications, she was considered a candidate for surgical resection.

As part of the presurgical evaluation, the patient underwent magnetoencephalography (MEG) and Wada testing. MEG localised sharp activity in the left posterior and antero-medial fronto-temporal lobes. The Wada test revealed right hemisphere dominance in language and memory. As non-invasive EEG suggested left temporal onset of seizure activity and MRI showed evidence of widespread dysplasia, invasive EEG was performed to further localise the epileptogenic zone. A left fronto-parietal craniotomy for implantation of subdural electrode grids and strips was performed. A 2 by 8-electrode grid was laid over the frontal operculum and inferior frontal gyrus, a 4 by 6 grid was placed over the lateral temporal lobe, and two 1 by 8 strips

were passed around the lateral and inferior surface of the left temporal lobe (*figure 2B and C*). Three clinical and electrographic seizures were captured (*figure 2A-D*). All seizures had temporal lobe onset, but propagated differently (*figure 2B and C*). Seizures were clinically characterised by an urge to urinate followed by right-sided paresthesias, staring, and unresponsiveness lasting less than two minutes. Two of the seizures also had right-sided version of the head and eyes, followed by generalised tonic-clonic movements.

Following the conclusion of invasive EEG monitoring, the patient underwent surgery. Using the Brain Lab computer-assisted image guidance system, a left temporal lobectomy was performed. The lateral temporal cortex was first removed and then the remaining heterotopia in the anterior mesial temporal lobe was removed in a subpial fashion, as far back as the tectal plate. The brain was noted to be dysmorphic and the temporal horn was not clearly identified. Lastly, the lateral posterior inferior temporal cortex was aspirated. She tolerated the procedure without complications, with no observable disruption in her speech or memory. Pathology confirmed architectural dysplasia, heterotopic neurons and abnormally convoluted islands of grey matter embedded in subcortical white matter, consistent with cortical dysplasia. She was discharged on levetiracetam and topiramate medication. After surgery, the patient remained seizure-free for eight months, at which point she developed simple partial seizures typified by right-sided paresthesias with no change in alertness. At two and a half years follow-up, she has not experienced ictal urinary urgency.

Discussion

Ictal vegetative symptoms are common in temporal lobe epilepsy. Clinical manifestations stem from the multiple organ systems, including cardiovascular, respiratory, gastrointestinal, cutaneous, ophthalmologic, genito-urinary, and sexual organs (Baumgartner *et al.*, 2001). Previous groups have acknowledged that these symptoms can provide information on the localisation and lateralisation of the epileptogenic focus (Baumgartner *et al.*, 2001). Though no lateralising sign is 100% accurate, the additional information that lateralising signs can contribute to a presurgical evaluation is well-established (Loddenkemper and Kotagal, 2005). The control of micturition is complex and has been localised within the brain. Functional imaging studies have revealed that the pons, thalamus, insula, periaqueductal grey, prefrontal cortices, and anterior cingulate gyrus are involved in bladder control (Charil *et al.*, 2003; Kavia *et al.*, 2005). Further studies of pathological conditions including stroke

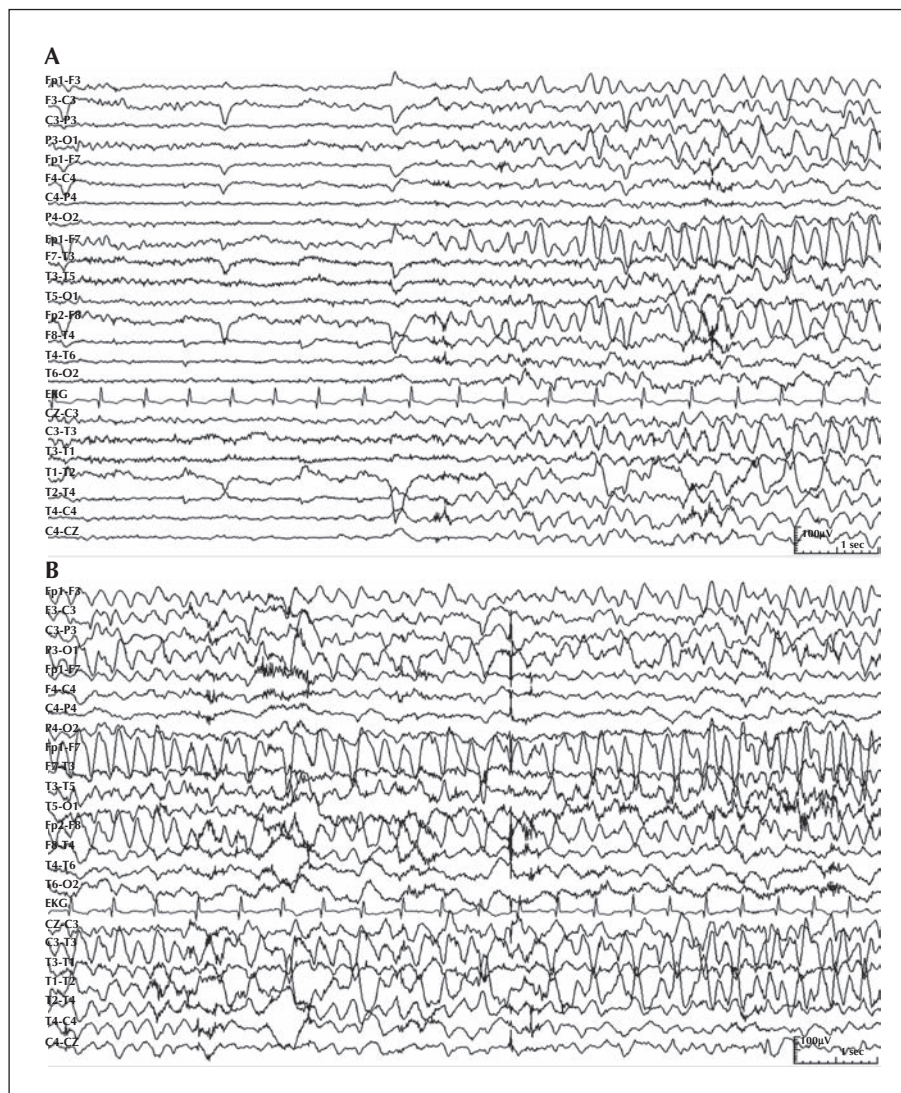


Figure 1. (A and B) Ten-second consecutive epochs of scalp EEG showing onset of seizure with rhythmic theta activity, evolving into rhythmic sharply contoured theta and delta, phase reversing between T3-T1 and T3-F7. The surface EEG showed interictal sharp waves at T3 and T5.

(Kuroiwa *et al.*, 1987), multiple sclerosis (Charil *et al.*, 2003), and disorders of micturition (Sakakibara *et al.*, 2004) demonstrate the importance of the right hemisphere in bladder control. In 1997, Blok *et al.* (1997) reviewed PET scans from various steps of micturition in 17 healthy, right-handed males and found increased blood flow in the right-sided structures during micturition. The authors concluded that, similar to cat models, the human brainstem contains several nuclei, predominantly on the right side, responsible for bladder control. The following year, the authors replicated these findings in healthy, right-handed, female volunteers (Blok *et al.*, 1998). In 2008, Hruz *et al.* (2008) used functional MRI to study the brain function of seven healthy patients during passive bladder filling and emptying. They found that the inferior frontal

gyrus, predominantly on the right side, had increased activity with bladder filling, along with activity in the cerebellum, frontal mesial and operculum bilaterally. The lateralisation of ictal urinary urge to the right hemisphere is supported by these studies.

Ictal urinary urgency is a rare ictal vegetative symptom that occurs in focal epilepsy. It manifests as an intense urge to urinate during a seizure and differs from ictal urination and the urinary incontinence seen in generalised seizures. The prevalence of ictal urinary urgency in temporal lobe epilepsy ranges from 0.4 to 3% (Baumgartner *et al.*, 2000; Janszky *et al.*, 2007; Loddenkemper *et al.*, 2003). Generally, the literature suggests that ictal urinary urgency has a significant lateralising value, arising from the non-dominant temporal lobe, right or left. In 2000, Baumgartner *et al.*

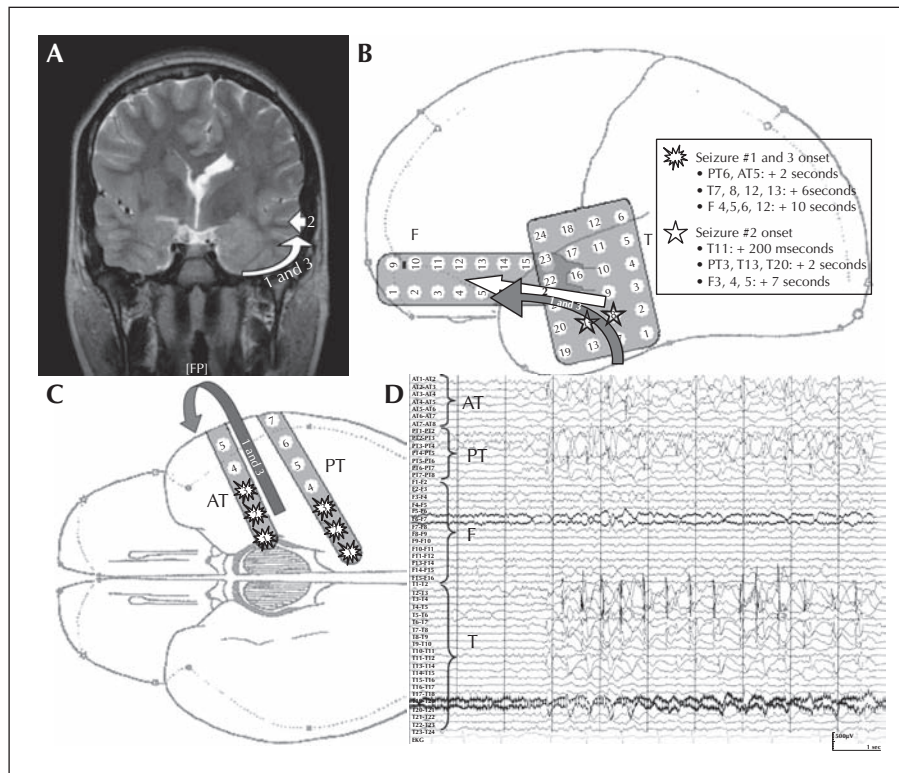


Figure 2. (A) T-2 weighted coronal view of 1.5 Tesla MRI brain demonstrating overt cortical dysplasia of the left temporal lobe. Arrows depict the site of onset and spread of the three electrographic seizures captured on invasive EEG (seizures labelled 1, 2, and 3). (B and C) Placement of the left temporal grids and strips. Arrows and stars depict the site of onset and propagation of the three electrographic seizures captured on invasive EEG (seizures labelled 1, 2, and 3).

(D) Subdural EEG tracing showing an example of a seizure with temporal onset and subsequent spreading throughout the temporal lobe.

The subdural EEG showed interictal spikes and sharp waves, occasionally in rhythmic runs, over the anterior temporal (AT 3-4) and posterior temporal (PT 4-5) strips. The frontal grid did not show interictal epileptiform activity. The lack of fast gamma or beta activity at the onset of the seizure indicates a deeper generator.

Note: AT: anterior temporal strip; PT: posterior temporal strip; F: Frontal grid; T: Temporal grid.

reported six patients with medically refractory temporal lobe epilepsy who experienced ictal urinary urge. On video-EEG, the seizures were lateralised to the non-dominant hemisphere in four patients. In one patient with bilateral seizures, ictal urinary urge only accompanied those originating in the right temporal lobe. Ictal SPECT performed on these patients revealed hyperperfusion of the right temporal lobe, specifically the superior temporal gyrus and insular cortex, in two of the patients. In 2003, Loddenkemper *et al.* (2003) described six additional patients with temporal lobe epilepsy who experienced ictal urinary urge. In all of their patients, the video-EEG localised seizure onset to the non-dominant right temporal lobe. Two patients also had resolution of seizures and ictal urinary urgency after surgical resection. On the contrary, in 2007, Janszky *et al.* (2007) found no significance in the lateralisation of ictal urinary urge in four patients with medial temporal lobe epilepsy. They suggested that periictal vegetative symptoms, including ictal urinary

urge, have a very limited role in the lateralisation of seizure activity.

While the resolution of seizure activity after non-dominant temporal lobectomy does suggest localisation of the seizure to that area of the brain in our patient, this case does offer additional important information. All studies documenting the significance of ictal urinary urge lateralising to the non-dominant temporal lobe used surface EEG monitoring, functional MRI, and SPECT. To our knowledge, none of the reported cases were studied using invasive intracranial monitoring. Yet, invasive intracranial monitoring is extremely important in determining the true localisation of the seizure focus. Relying on associated symptoms and surface EEG can be misleading as symptoms may develop from discharges spreading from the epileptogenic zone (Baumgartner *et al.*, 2001).

Our patient presented with complex partial seizures characterised by urinary urgency, paresthesias, and automatisms due to cortical malformation. Invasive

subdural EEG monitoring mapped the epileptogenic zone of the seizures to her left, non-dominant temporal lobe, and ictal urinary urgency resolved following resection of the left temporal lobe. These results support the findings of previous studies (Baumgartner et al., 2000; Baumgartner et al., 2001; Loddenkemper et al., 2003; Loddenkemper and Kotagal, 2005), indicating that ictal urinary urgency does lateralise to the non-dominant temporal lobe. This fact is not surprising, given that central bladder control also lateralises to the non-dominant hemisphere (Blok et al., 1997; Hruz et al., 2008; Kavia et al., 2005). We thereby conclude that this case report supports the localisation of ictal urinary urgency epileptogenic zone to the non-dominant temporal lobe. To our knowledge, this is the first description of invasive localisation of this rare vegetative symptom. □

Disclosure.

None of the authors have any conflicts of interest. This study was not funded. This work has not been presented nor previously submitted for publication.

References

- Baumgartner C, Groppe G, Leutmezer F, et al. Ictal urinary urge indicates seizure onset in the nondominant temporal lobe. *Neurology* 2000;55:432-4.
- Baumgartner C, Lurger S, Leutmezer F. Autonomic symptoms during epileptic seizures. *Epileptic Disord* 2001;3:103-16.
- Blok BF, Willemsen AT, Holstege G. A PET study on brain control of micturition in humans. *Brain* 1997;120:111-21.
- Blok BF, Sturms LM, Holstege G. Brain activation during micturition in women. *Brain* 1998;121:2033-42.
- Charil A, Zijdenbos AP, Taylor J, et al. Statistical mapping analysis of lesion location and neurological disability in multiple sclerosis: application to 452 patient data sets. *Neuroimage* 2003;19:532-44.
- Hruz P, Lovblad KO, Nirkko AC, Thoeny H, El-Koussy M, Danuser H. Identification of brain structures involved in micturition with functional magnetic resonance imaging (fMRI). *J Neuroradiol* 2008;35:144-9.
- Janszky J, Fogarasi A, Toth V, et al. Peri-ictal vegetative symptoms in temporal lobe epilepsy. *Epilepsy Behav* 2007;11:125-9.
- Kavia RB, Dasgupta R, Fowler CJ. Functional imaging and the central control of the bladder. *J Comp Neurol* 2005;493:27-32.
- Kuroiwa Y, Tohgi H, Ono S, Itoh M. Frequency and urgency of micturition in hemiplegic patients: relationship to hemisphere laterality of lesions. *J Neurol* 1987;234:100-2.
- Loddenkemper T, Kotagal P. Lateralizing signs during seizures in focal epilepsy. *Epilepsy Behav* 2005;7:1-17.
- Loddenkemper T, Foldvary N, Raja S, Neme S, Luders HO. Ictal urinary urge: further evidence for lateralization to the nondominant hemisphere. *Epilepsia* 2003;44:124-6.
- Rojas L, Melvin JJ, Faerber EN, Valencia I. Anterior encephalocle associated with subependymal nodular heterotopia, cortical dysplasia and epilepsy: case report and review of the literature. *Eur J Paediatr Neurol* 2006;10:227-9.
- Sakakibara R, Uchida Y, Uchiyama T, Yamanishi T, Hattori T. Reduced cerebellar vermis activation during urinary storage and micturition in multiple system atrophy: 99mTc-labelled ECD SPECT study. *Eur J Neurol* 2004;11:705-8.