

Hypnopompic seizures

Amer M. Awad, Hans O. Lüders

Neurological Institute, Case Western Reserve University,
University Hospitals Case Medical Center, Cleveland, Ohio, USA

Received May 17, 2010; Accepted September 22, 2010

ABSTRACT – The relationship between epilepsy and sleep is complex and bidirectional. Ictal awakening is probably a common and well-described phenomenon. In this small observational study we describe arousal from sleep as the only, or at least main, manifestation of some epileptic seizures. We coin the term “hypnopompic seizures” to describe this entity. Five patients with intractable epilepsy were monitored by continuous video-electroencephalogram. Four of them had left temporal lobe epilepsy and one patient had generalised epilepsy. Hypnopompic seizures accounted for 30-100% of their seizure types captured during monitoring. All the seizures occurred during stage II sleep and were brief. Hypnopompic seizures are extremely subtle and may be underdiagnosed and underreported. Future larger studies are needed to shed some light on this unique entity and its neuropathophysiology. Epileptologists should be aware of this type of seizure and careful review of electroencephalograms during the transition from sleep to arousal is imperative to capture these seizures. Physicians, patients and families also need to be aware of such a subtle manifestation of seizures. Improved awareness of hypnopompic seizures and subtle seizures, in general, help guide accurate and early diagnosis, thorough monitoring and appropriate management.

Key words: hypnopompic, seizures, arousal, sleep, ictal arousal

The relationship between arousal from sleep and epileptic seizures has been described and evaluated (Janz, 1953; Janz, 1974; Shouse, 1987; Wieser, 1991; Manni *et al.*, 1997; Malow *et al.*, 2000; Dasheiff and Kofke, 2003). The term “awakening epilepsy” (*Aufwach-Epilepsien*) was first coined by Janz in 1953 (Janz, 1953). He referred to the awakening as a triggering mechanism for epileptic seizures. In this study, we have explored the opposite phenomenon of awakening as the result, rather than the cause, of the seizure. To our knowledge, the phenomenon of awakening as the only or the most prominent manifestation of an epileptic seizure has not been previously described or evaluated. We coin the term “hypnopompic (arousing) seizures” to describe this phenomenon.

Patients

The clinical and electrographic features of the patients are summarised in *table 1*.

Patient 1

The patient is a 31-year-old right-handed man with history of lesional left temporal lobe epilepsy secondary to left temporal oligodendroglioma status post resection. He was admitted to the epilepsy monitoring unit (EMU) for evaluation of new onset seizures. The seizures were described by the patient as abdominal auras followed by inability to talk. The video-EEG (VEEG) evaluation revealed a normal interictal recording. During his eight days stay in the EMU, the patient had only one epileptic seizure.

doi: 10.1684/epd.2010.0336

Correspondence:

A.M. Awad, MD
11100 Euclid Ave.,
Cleveland, OH 44106, USA
<ameraldo@gmail.com>

Table 1. The clinical and electrographic features of the five patients.

| Patient | Age | Gender | Epileptogenic Zone | Aetiology | Number of seizures recorded | Number of hypnopompic seizures | EEG seizure pattern of hypnopompic seizure |
|---------|-----|--------|--------------------|------------------------|-----------------------------|--------------------------------|--|
| 1 | 31 | Male | Left temporal | Oligodendroglioma | 1 | 1 (100%) | Rhythmic theta |
| 2 | 56 | Female | Left temporal | Mesotemporal sclerosis | 3 | 1 (30%) | Rhythmic theta |
| 3 | 48 | Male | Left temporal | Unknown | 17 | 5 (45%) | Rhythmic theta |
| 4 | 28 | Female | Generalised | Unknown | 90 | 30 (30%) | Burst of polyspikes |
| 5 | 55 | Female | Left temporal | Unknown | 3 | 2 (75%) | Rhythmic theta |

On scalp EEG, the electrographic seizure was characterized by evolving rhythmic delta activity. The EEG onset occurred over the left temporal region. The seizure lasted for 30 seconds. The only clinical manifestation of the seizure was arousal from sleep. Post-ictally, the patient was confused, amnesic and dysphasic. The patient denied having aura or any breathing problem. On careful observation, specific sensory stimuli, such as light or sound that may have woken the patient up were not observed. On examination, there was no tongue biting or urinary incontinence.

Patient 2

The patient is a 56-year-old right-handed woman with history of lesional left temporal lobe epilepsy secondary to left mesotemporal sclerosis status post left temporal lobectomy. The patient was admitted to the EMU for evaluation of breakthrough seizures after the surgery. She described her seizures as olfactory aura or abdominal aura followed by inability to communicate. The inter-ictal EEG showed left temporal slowing and sharp waves. While in the EMU, three events were recorded: one characterized by abdom-

inal aura followed by aphasia with left temporal seizure onset, another manifested by olfactory aura with left temporal seizure onset and a third characterized by a 65-second-long EEG seizure pattern consisting of repetitive sharp and rhythmic theta activity over the left temporal area (*figure 1*). The only clinical symptomatology of the seizure was waking up from sleep. After the event, the patient was awake and alert but was amnesic of the event. She denied having aura or breathing difficulties. On examination, there was no urinary incontinence and no evidence of tongue biting. The patient denied being woken up by a loud noise or light.

Patient 3

The patient is a 48-year-old right-handed man with history of non-lesional left temporal lobe epilepsy since the age of nine. The patient was admitted for evaluation of intractable seizures, described by the mother as blank staring and automatism followed by asymmetric tonic posturing of both arms. The patient's inter-ictal EEG revealed left temporal slowing with no epileptiform discharges. While

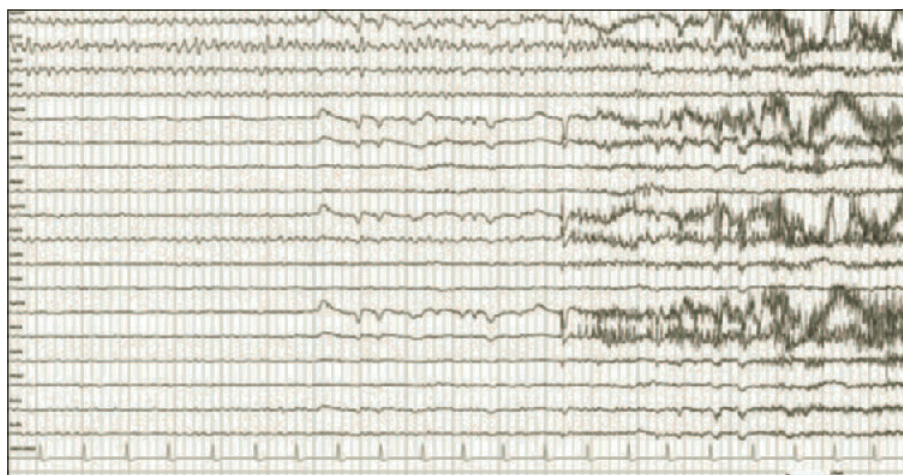


Figure 1. Longitudinal bipolar montage showing an EEG seizure pattern characterized by rhythmic theta activity over the left temporal region associated with arousal.

in the EMU, the patient had 17 seizures with left temporal onset characterized by rhythmic theta activity. At least five of the 17 seizures lasted for approximately 40 seconds and the only clinical manifestation was awakening from sleep with the patient being amnesic to the event, denying aura or breathing problems as well as being woken up by light or sound. There was no evidence of other seizure manifestations like tongue biting or urinary incontinence on physical examination.

Patient 4

The patient is a 28-year-old right-handed woman with autism and intractable generalised epilepsy. The patient underwent leg surgery during which she did not receive her antiepileptic medications. Postoperatively, she started having clusters of tonic seizures every five minutes. A bedside VEEG was initiated to evaluate possible status epilepticus. Her EEG showed very frequent (every 5-10 seconds) 2-2.5 Hz generalised spike-and-slow wave complexes and generalised polyspikes. The patient was asleep throughout the whole recording. During the first six hours of recording, more than 60 tonic seizures were recorded, characterized clinically by tonic posturing of both upper extremities lasting for 20-30 seconds and electrographically by electrodecremental response with superimposed 20-25 Hz activity, followed by beta activity then alpha activity then spike-and-slow wave complexes. While observing the VEEG, we noted that every 2-5 minutes the EEG showed a burst of polyspikes lasting for about six seconds, followed by generalised delta activity (hyper-synchrony) and subsequently sudden arousal (*figure 2*). About 30 bursts were counted in the first six hours. The only, or at least the most prominent, clinical manifestation of these bursts was sudden arousal from sleep.

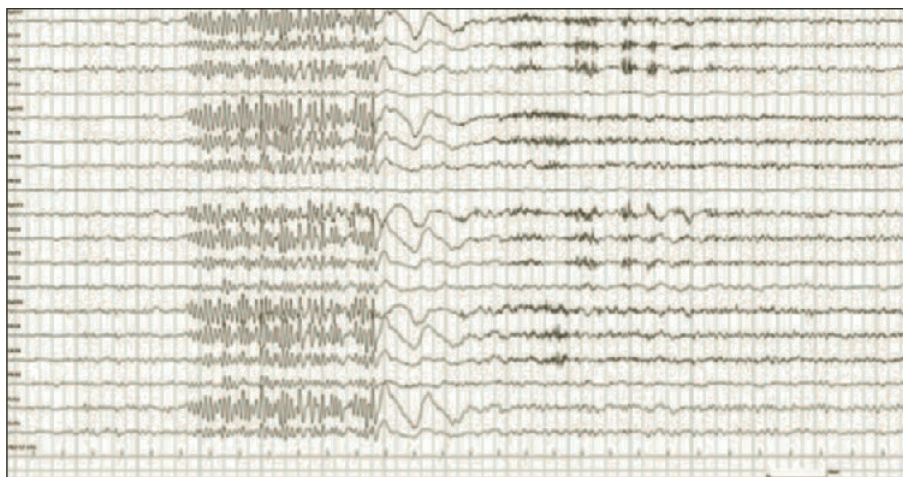


Figure 2. Longitudinal bipolar montage showing an EEG seizure pattern characterized by generalized polyspikes followed by delta activity and arousal.

Patient 5

The patient is a 55-year-old right handed woman with intractable non-lesional left temporal lobe epilepsy. Historically, her seizures consisted of abdominal aura followed by aphasia, unresponsiveness and/or vomiting. Her inter-ictal EEG showed left temporal sharp waves. The patient had three seizures while being monitored in the EMU. Of the three seizures, two occurred during sleep. The only symptom of the nocturnal seizures was awakening from sleep. The patient denied aura and breathing problems. The EEG showed a prolonged ictal discharge lasting for one minute and 40 seconds, which started as rhythmic theta activity over the left temporal region.

Discussion

The propensity of seizures to wake up the patient from sleep has only been studied in very few clinical trials in humans. The main studies to address this question include those by Manni *et al.* (1997), Malow *et al.* (2000) and Dasheiff and Kofke (2003).

Manni and co-workers evaluated 20 patients with focal epilepsy by ambulatory EEG. They analyzed 49 seizures of which 39 occurred during sleep. The investigators found that 72% of focal seizures, which occurred during sleep, were followed by awakening. The authors did not provide details on the clinical manifestations of the nocturnal seizures. Malow *et al.* (2000) studied 14 patients with a total number of 67 mesial temporal lobe seizures recorded by intracranial electrodes and found the electrographic seizure preceded arousal from sleep in 13 patients. Dasheiff and Kofke (2003) retrospectively

reviewed intracranial EEG recordings in 172 patients with a total number of 7571 clinical seizures and 8017 electrographic seizures. In their study, 22 patients had 308 seizures during sleep. They noticed that patients woke up *after* the electrographic seizure onset. For four events, spontaneous awakening was followed by a clinical seizure. The authors noted that electrographic seizures could only wake the patient if the discharges were generalised rather than focal.

In our series of four patients with focal epilepsy and one patient with generalised epilepsy, we observed that the electrographic seizure preceded the awakening and that awakening was the *only* manifestation of the seizure, or at least the most prominent manifestation. In contrast to Dasheiff and Kofke's findings, not only generalised but also focal EEG seizure patterns were capable of arousing the patient from sleep. In addition, temporal lobe seizures have not been previously associated with arousal as the predominant manifestation.

The mechanism by which a seizure can wake up the patient is largely unknown but there are several theories that could explain this phenomenon. Three inter-related subthalamocortical systems mediate the switching between wakefulness and sleep. These systems include: the ascending reticular activating system (ARAS), the ventral preoptic (VLPO) area and the orexin/hypocretin system (Saper, 2000; Nestler *et al.*, 2001; Marcus *et al.*, 2001; Posner *et al.*, 2007; Sakurai, 2007).

Despite the fact that the arousal systems are classically viewed as "ascending", there is a "descending" cortical feedback system that has to be active continuously to maintain consciousness (Afifi and Bergman, 2005; Blumfield, 2002). This could explain the mechanism of hypnopompic seizures; a seizure may spread *downstream* to the reticular activating system and arouse the patient before any other symptomatology. Moreover, a connection between mesial temporal lobe and midbrain raphe nuclei is also well-described (Giovacchini *et al.*, 2005). This hypothesis could be tested in animals by implanting intracranial electrodes in the brain stem and/or alternatively by stimulating cortical intracranial electrodes while the animal is sleeping. In a study that was conducted on cats by Shouse (1987), thalamic hyperexcitability was suggested to be a potential mechanism of epileptic awakening. Another possibility to explain hypnopompic seizures includes a surge in excitatory neurotransmitters which could, in turn, stimulate the reticular activating system. In addition, secondary factors may also cause arousal. These secondary causes include, but are not limited to: autonomic and respiratory changes previously mentioned by Dasheiff and Kofke (2003) and reactionary phenomena to the ictal event, such as pain or discomfort. In addition, other subtle seizure phenomena which can pass unnoticed by the patient and the observers (i.e. very brief loss of awareness, subtle muscle tension which could only be detected by additional electromyography (EMG) leads,

auras of which the patient is amnesic, etc) could also explain awakening. Finally, the fact that the patients were amnesic does not exclude aura or other seizure phenomena since non-rapid eye movement (NREM) sleep is not conducive to storing memory.

Despite the uncertainty of the underlying mechanism, this report shows that seizures, in which the only detectable or the most prominent phenomenon is an unexplained awakening, do exist. This entity is clinically important due to its subtlety and we suggest that clinically-driven seizure classification should take this phenomenon into consideration. Health care providers may include "sudden unexplained awakening" as a possible seizure pattern in their inquiry about seizures. Families need to be aware of this entity and seek medical attention. During video-EEG monitoring, epileptologists and co-workers may need to pay special attention to periods of sudden unexplained arousals and examine the patient thoroughly after the arousal.

Conclusion

Hypnopompic seizures are seizures that solely or predominantly present with awakening from sleep. The exact mechanism(s) and frequency of this type of seizures remain unknown. Carefully conducted studies should shed some light on this intriguing phenomenon that is probably underdiagnosed. Awareness of this entity will help improve the yield and accuracy of VEEG monitoring. □

Disclosure.

None of the authors has any conflict of interest or financial support to disclose.

References

- Afifi AK, Bergman RA. *Functional Neuroanatomy*. In: New York: The McGraw Hill Companies Inc, 2005: 402-3.
- Blumfield H. *Neuroanatomy through Clinical Cases*. Sunderland: Massachusetts: Sinauer Associates Inc, 2002: 590-1.
- Dasheiff RM, Kofke WA. Primarily generalized seizures are more effective than partial seizures in arousing patients from sleep. *Neurol Res* 2003; 25: 63-7.
- Giovacchini G, Toczek MT, Bonwetsch R, *et al*. 5-HT 1A receptors are reduced in temporal lobe epilepsy after partial-volume correction. *J Nucl Med* 2005; 46: 1128-35.
- Janz D. Epilepsy and the sleeping-waking cycle. In: Magnus O, Lorentz de Hass, AM. *The Epilepsies, Ch 26. Handbook of Clinical Neurology*, Vol 15. New York: Elsevier, 1974.
- Janz D. Aufwach-Epilepsien. *Arch Psychiatr Nervenkr* 1953; 191: 73-98.
- Malow BA, Bowes RJ, Ross D. Relationship of temporal lobe seizures to sleep and arousal: A combined scalp-intracranial electrode study. *Sleep* 2000; 23: 231-4.

Manni R, Galimberti CA, Sartori I, Politini L, Murelli R, Tartara A. Nocturnal partial seizures and arousals/awakenings from sleep: an ambulatory EEG study. *Funct Neurol* 1997; 12: 107-11.

Marcus JN, Aschkenasi CJ, Lee CE, et al. Differential expression of orexin receptors 1 and 2 in the rat brain. *J Comp Neurol* 2001; 435: 6-25.

Nestler EJ, Hyman SE, Malenka RC. *Molecular Neuropharmacology. A Foundation for Clinical Neuroscience*. In: New York: McGraw-Hill Companies, 2001: 289-313.

Posner JB, Saper CB, Schiff ND, Plum F. *Plum and Posner's diagnosis of stupor and coma*. In: New York: Oxford University Press, 2007: 328.

Sakurai T. Discovery of orexin. *Nippon Yakurigaku Zasshi* 2007; 130: 19-22.

Saper CB. Brainstem modulation of sensation, movement and consciousness. In: Kandel ER, Schwartz JH, Jessell TM, eds. *Principles of Neural Science*. New York: McGraw-Hill, 2000: 889-909.

Shouse MN. Thalamocortical mechanisms of state-dependent seizures during amygdala kindling and systemic penicillin epilepsy in cats. *Brain Res* 1987; 425: 198-203.

Wieser HG. Temporal lobe epilepsy, sleep and arousal: stereo-EEG findings. *Epilepsy Res* 1991; 2 (Suppl.): 97-119.