

**Case report**

## McCune Albright syndrome and bilateral adrenal hyperplasia: the *GNAS* mutation may only be present in adrenal tissue

Anna Angelousi,<sup>1\*</sup> Filip Fencl,<sup>2\*</sup> Fabio R. Faucz,<sup>1</sup> Jana Malikova,<sup>2</sup>  
Zdenek Sumnik,<sup>2</sup> Jan Lebl,<sup>2</sup> Constantine A. Stratakis<sup>1</sup>

<sup>1</sup>Section on Endocrinology & Genetics, Program on Developmental Endocrinology & Genetics, Eunice Kennedy Shriver National Institute of Child Health and Human Development (NICHD), NIH, Bethesda, USA; <sup>2</sup>Department of Pediatrics, University Hospital Motol, Prague, Czech Republic

\*A.A. and F.F. share the co first-authorship of this manuscript.

### ABSTRACT

**OBJECTIVE:** Corticotropin (ACTH)-independent hypercortisolism due to bilateral adrenocortical hyperplasia (BAH) in infancy is an extremely rare condition that is often caused by McCune Albright syndrome (MAS). MAS is caused by an activating mutation of the *GNAS* gene which leads to increased cyclic (c) adenosine monophosphate (AMP) signaling. Most forms of BAH are linked to increased cAMP signaling. We report the case of an infant with MAS who had BAH. **METHODS:** Genomic DNA fragments from blood and adrenal tissue encompassing regions (exons 8 and 9) with the hot spot activating missense *GNAS* mutations were amplified by classical bidirectional Sanger sequencing. **RESULTS:** The infant was found to carry the most common *GNAS* mutation, in exon 8 (c.602G >A, p. R201H), only in her adrenocortical tissue, despite extensive skin and other findings. **CONCLUSIONS:** We conclude that infants with MAS, despite absence of the *GNAS* activating mutation in blood, may still have significant clinical findings, including ACTH-independent hypercortisolism. Molecular confirmation of the diagnosis should be sought at the tissue level in these patients.

**Key words:** Bilateral adrenocortical hyperplasia, Cushing syndrome, Primary pigmented nodular adrenocortical disease, *PRKARIA*, Protein kinase A

### Address for correspondence:

Dr. Fabio R. Faucz, Section on Endocrinology & Genetics,  
Program on Developmental Endocrinology & Genetics, Eunice  
Kennedy Shriver National Institute of Child Health and Human  
Development (NICHD), National Institutes of Health (NIH),  
CRC, East Laboratories, Room 1-3216, 10 Center Drive,  
Bethesda, MD20892, USA;  
Tel.: 301-451-7177; Fax: 301-4020574,  
E-mail: fabio.faucz@nih.gov

Received 22-04-2015, Accepted 24-04-2015

### INTRODUCTION

McCune Albright syndrome (MAS) is a very rare genetic disorder that is caused by activating mutations in the *GNAS* gene in a mosaic manner.<sup>1</sup> *GNAS* encodes the alpha subunit of the stimulatory G protein (Gsa) that regulates the synthesis of cyclic adenosine monophosphate (cAMP).<sup>1</sup> Activating *GNAS* mutations result in decreased GTPase activity of Gsa, constitu-

tive activation of adenylate cyclase and, consequently, increased cAMP levels in all tissues where the *GNAS* mutations are present.<sup>1,2</sup> Because of mosaicism, the manifestations are dependent on the distribution of the mutations.<sup>1</sup> MAS usually presents with a constellation of cutaneous (multiple café-au-lait spots), skeletal (polyostotic fibrous dysplasia) and endocrine manifestations (precocious puberty, growth hormone [GH] excess, hypercortisolism, hyperthyroidism and phosphate wasting).<sup>3</sup>

Hypercortisolism in MAS is always ACTH-independent and leads to Cushing syndrome (CS), often mild and cyclical, but occasionally severe and with significant mortality. Onset of CS is usually in the first year of life and, very rarely, is congenital. The anatomical basis of CS has been attributed variously to bilateral nodular hyperplasia,<sup>4</sup> bilateral atypical adenomas,<sup>5</sup> bilateral macronodular disease<sup>6</sup> and other forms of bilateral hyperplasia.<sup>7</sup> Exceptionally, CS in the context of MAS resolves spontaneously.<sup>8</sup> We recently described primary bimorphic adrenocortical disease (PBAD) as the unifying descriptive term of the histopathology causing ACTH-independent CS in MAS.<sup>10</sup>

In this report, we present the case of an infant that had intense clinical signs of MAS and ACTH-independent hypercortisolism suggesting widespread presence of the *GNAS* mutation. Still, repeated testing of blood cells did not show the presence of the causative *GNAS* mutation; on the other hand, the defect was present in both adrenal glands.

## SUBJECTS & METHODOLOGY

### *Clinical investigations*

MAS was diagnosed per standard criteria.<sup>5</sup> Written informed consent was obtained from the parents and the study was approved by the institutional review boards of the participating centers.

### *Genetic studies*

DNA was extracted from peripheral blood leucocytes and adrenal tissue according to commercially available protocols (QIAGEN, Valencia, CA, USA). Genomic DNA fragments encompassing regions (exons 8 and 9) previously found to contain activating missense *GNAS* mutations (known as “gsp mutations”) were

amplified by classical bidirectional Sanger sequencing, as previously described, using the following primers: forward: 5'-CAAGCAGGCTGACTATGTGC-3' and reverse: 5'-ACCACGAAGATGATGGCAGT-3'. This primer pair yielded a PCR product of 321bp.<sup>9</sup> Direct sequencing of the purified fragment was performed using the Genetic Sequencer ABI3500 (Applied Biosystems, Grand Island, USA).

## RESULTS

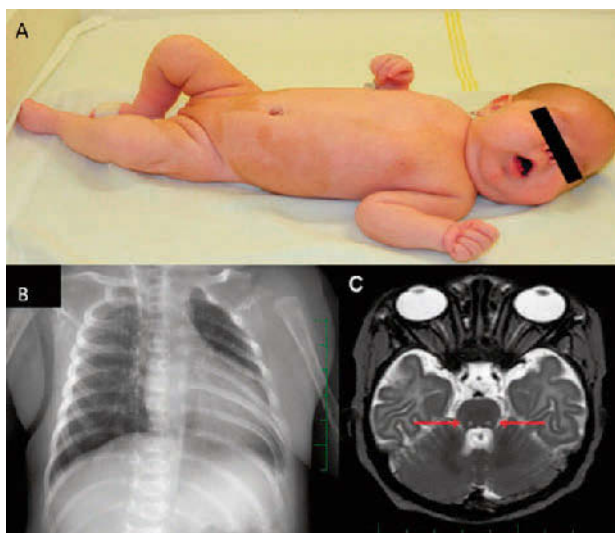
### *Clinical case report*

A female infant with uneventful perinatal and intrauterine history presented with tachycardia (200 beats per minute) at the age of 1 month. At the age of 2 months, the echocardiography showed signs of hypertrophic cardiomyopathy predominantly of the interventricular septum, obstruction of the left ventricle outflow tract and mitral insufficiency (grade 2-3). She had no clinical signs of heart failure except decreased oral intake and failure to thrive. Blood pressure was normal. Physical examination revealed persistent tachycardia with systolic murmur 3/6, pigmented lesions on head, trunk and extremities, with predilection on the left side, facial plethora and other signs of CS (Figure 1A). Laboratory tests revealed hyperthyroidism: TSH 0.008 mIU/l (normal range 0.460-7.300 mIU/l); fT4 44.29 pmol/l (normal range 8.50-24.00 pmol/l) and hypercortisolism with low or undetectable ACTH (ACTH 1 ng/l with a normal range of 7.2-63.3 ng/l). Radiological studies revealed fibrous dysplasia of both humerus and multiple ribs (Figure 1B). Magnetic resonance imaging (MRI) showed bilateral adrenal enlargement. The diagnosis of MAS was suspected based on clinical and laboratory findings and an appropriate treatment was initiated based on clinical manifestations. Clinical improvement was achieved within a few days from presentation after the initiation of thyreostatic therapy (thiamazole at an initial dose of 0.8 mg/kg/day) and beta-blockers (propranolol gradually increased to a dose of 4 mg/kg/day). Myocardial hypertrophy was also partially reversed. Bilateral adrenalectomy was performed at the age of 3 months. Adrenal histology revealed bilateral thickening of the adrenal cortex with irregular nodular conversion, consistent with PBAD. Substitution therapy was initiated with hydro-

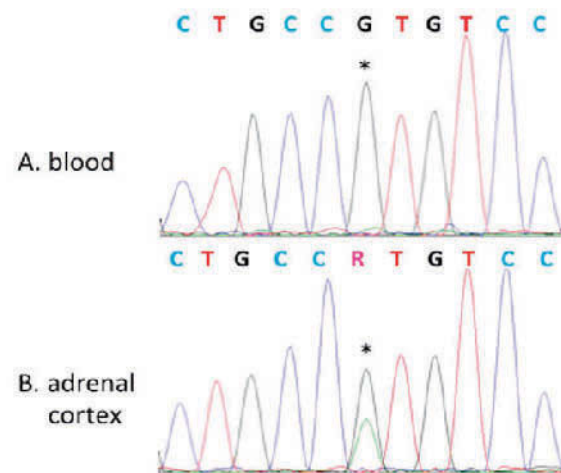
cortisone and fludrocortisone. At the age of 4 months, the patient developed signs of peripheral precocious puberty; an ovarian cyst on the right side was seen upon imaging (maximum diameter of 7.5 cm). A combination treatment of cyproterone acetate (initial dose of 2 mg/kg/day) and tamoxifen (initial dose of 1 mg/kg/day) was initiated with gradual regression of the cyst's size. MRI of the brain showed various abnormalities of the central nervous system (CNS): nonspecific signal focal alteration in the left thalamus and stripe signal changes in the dorsal brainstem and pons (Figure 1C), most likely corresponding to non-specific neurodegeneration. Delayed myelination of brain and mild cortical and periventricular atrophy were also described. The patient died suddenly at 15 months of age in the course of a viral respiratory track infection probably due to adrenal crisis.

### Genetic studies

Direct sequencing of the *GNAS* exons 8 and 9 of the patient's blood and adrenal DNA revealed normal sequence in the former, and the well-known heterozygous mutation in exon 8 (RefSeq NM\_000516) from guanine to adenine (c.602G>A; rs121913495) in the latter. The c.602G>A *GNAS* mutation leads to an amino acid replacement in codon 201, from arginine (R) to histidine H (p.R201H) (Figure 2).



**Figure 1.** A. Skin pigmentations with café-au-lait spots; B. X ray with fibrous dysplasia of multiple ribs; C. Nonspecific signal focal alteration in the left thalamus and stripe signal changes in the dorsal brainstem and pons.



**Figure 2.** Electropherograms showing the analysis of the *GNAS* gene (exon 8, Reference Sequence: NM\_000516). A. Blood sample: normal sequence from germline DNA; B. Adrenal tissue: heterozygous substitution of guanine to adenine in the codon 602 of the *GNAS* gene (c.602G>A; rs121913495). \*mutation position.

### DISCUSSION

We present the case of an infant with the classical triad of MAS (café-au-lait spots, polyostotic fibrous dysplasia and precocious puberty), as well as hyperthyroidism and CS due to PBAD, myocardial impairment and CNS abnormalities (Figure 1A). Despite the severity of the disease, and previous suggestions that in severe cases of MAS the causative *GNAS* mutation may be detectable in the blood,<sup>1</sup> the p.R201H defect was only found in one of the affected tissues (i.e. the adrenal cortex) but not in blood cells (Figure 2).

*GNAS*-activating R201 mutations were first described in sporadic GH-secreting pituitary adenomas.<sup>2</sup> It has been shown that the replacement of arginine at position 201 of the *GNAS* protein with either cysteine or histidine causes a 30-fold decrease in intrinsic GTPase activity leading to high cAMP levels.<sup>1</sup> Since the mutation is only present post-zygotically, the extent of the disease is determined by the proliferation, migration and survival of the cells in which the mutation spontaneously occurred.<sup>1</sup> Thus, it makes sense that the mutation load should be reflected in the clinical presentation; yet, as the patient of this report demonstrates, this is not always the case.

Determining the extent of the presence of the

mutation is important: the prognosis of patients with MAS varies considerably and it roughly corresponds to mutation load, which in turn determines the extent of organ involvement. In general, CNS, cardiac and hepatic involvement is associated with a poorer prognosis and even mortality, as our case demonstrates.

CS in infancy in the context of MAS is often severe, although a few cases with spontaneous remission have also been described.<sup>8</sup> PBAD associated with MAS is the most common cause of ACTH-independent CS due to BAH in infancy,<sup>10</sup> more frequent than PPNAD or isolated macronodular adrenal disease (iMAD) that are almost never seen in the first year of life. On the other hand, asymmetric enlargement of the adrenal gland in the context of MAS and ACTH-independent CS should be differentiated from adrenocortical cancer which is seen more frequently than MAS at this age, albeit also being a very rare occurrence. Li-Fraumeni or Beckwith-Widemann syndromes, adrenal tumors and ACTH-dependent CS should also be differentiated at this age from MAS.

In conclusion, we report the case of a child with severe MAS and CS due to PBAD who had no detectable load of the *GNAS* causative mutation (p.R201H) in her peripheral blood. The case illustrates the need for tissue examination when molecular confirmation of MAS is sought.

#### ACKNOWLEDGMENTS

We thank the family of the patient for their participation in this study.

#### CONFLICT OF INTEREST

The authors declare that there is no conflict of interest.

#### FUNDING

This research was supported by the Intramural Research Program of the National Institutes of Health,

Eunice Kennedy Shriver National Institute of Child Health and Human Development (Clinical trial registration number of NCT00005927) and in part by the Greek State Foundation for Scholarships (IKY).

#### REFERENCES

1. Weinstein LS, Shenker A, Gejman PV, Merino MJ, Friedman E, Spiegel AM, 1991 Activating mutations of the stimulatory G protein in the McCune-Albright syndrome. *N Engl J Med* 325: 1688-1695.
2. Landis CA, Masters SB, Spada A, Pace AM, Bourne HR, Vallar L, 1989 GTPase inhibiting mutations activate the alpha chain of Gs and stimulate adenylyl cyclase in human pituitary tumours. *Nature* 340: 692-696.
3. Lumbroso SF, Paris F, Sultan C, 2004 Activating Gsalpha mutations: analysis of 113 patients with signs of McCune-Albright syndrome-a European Collaborative Study. *J Clin Endocrinol Metab* 89: 2107-2113.
4. Kirk JM, Brain CE, Carson DJ, Hyde JC, Grant DB, 1999 Cushing's syndrome caused by nodular adrenal hyperplasia in children with McCune-Albright syndrome. *J Pediatr* 134: 789-792.
5. Benjamin DR, McRoberts JW, 1973 Polyostotic fibrous dysplasia associated with Cushing syndrome. *Arch Pathol* 96: 175-178.
6. Hamajima T, Maruwaka K, Homma K, Matsuo K, Fujieda K, Hasegawa T, 2010 Unilateral adrenalectomy can be an alternative therapy for infantile onset Cushing's syndrome caused by ACTH-independent macronodular adrenal hyperplasia with McCune-Albright syndrome. *Endocr J* 57: 819-824.
7. Paris F, Philibert P, Lumbroso S, Servant N, Kalfa N, Sultan C, 2009 Isolated Cushing's syndrome: an unusual presentation of McCune-Albright syndrome in the neonatal period. *Horm Res* 72: 315-319.
8. Gillis DA, Rosler TS, Hannon BZ, Koplewitz BZ, Hirsch HJ, 2008 Prolonged remission of severe Cushing syndrome without adrenalectomy in an infant with McCune-Albright syndrome. *J Pediatr* 152: 882-884.
9. Faucez FR, Horvath A, Rothenbuhler A, et al, 2011 Phosphodiesterase 11A (PDE11A) genetic variants may increase susceptibility to prostatic cancer. *J Clin Endocrinol Metab* 96: 135-140.
10. Carney JA, Young WF, CA Stratakis CA, 2011 Primary bimorphic adrenocortical disease: cause of hypercortisolism in McCune-Albright syndrome. *Am J Surg Pathol* 35: 1311-1326.