

# Metinel Node—The First Lymph Node Draining a Metastasis—Contains Tumor-Reactive Lymphocytes

Kjell Dahl, PhD, MD,<sup>1</sup> Mona Karlsson, PhD,<sup>2</sup> Per Marits, MD,<sup>2</sup> Anna Hoffstedt, MD,<sup>3</sup> Ola Winqvist, PhD, MD,<sup>2</sup> and Magnus Thörn, PhD, MD<sup>1</sup>

<sup>1</sup>Department of Surgery, Stockholm South General Hospital, Stockholm 118 83, Sweden

<sup>2</sup>Department of Medicine, Unit of Clinical Allergy Research, Karolinska Hospital, Stockholm 171 76, Sweden

<sup>3</sup>Department of Digital Imaging/Nuclear Medicine, Stockholm South General Hospital, Stockholm 118 83, Sweden

---

**Background:** We previously identified tumor-reactive lymphocytes in the first lymph nodes that drain the primary tumor. In this study, we performed lymphatic mapping to investigate the possibility of finding the first lymph nodes that drain metastases, and of learning whether these lymph nodes contained tumor-reactive lymphocytes suitable for adoptive immunotherapy.

**Methods:** Nineteen patients were studied. The primary tumor site was colorectal cancer in seven patients, malignant melanoma in four, ovarian cancer and breast cancer in two, and one each with pancreatic cancer, cholangiocarcinoma, leiomyosarcoma, and squamous cellular cancer of the tongue. By injection of Patent blue dye or radioactive tracers around the metastases, we identified draining lymph nodes from liver metastases (n = 9), intra-abdominal local recurrences (n = 3), and regional lymph node metastases (n = 7). In six patients, a preoperative lymphoscintigraphy was performed.

**Results:** We located the first draining lymph node or nodes from metastases or local recurrences; we named them “metinel nodes.” Lymphocytes from the metinel nodes proliferated, showed clonal expansion, and produced interferon gamma (via *in vitro* expansions on stimulation with tumor homogenate) and interleukins, all of which demonstrate the characteristics of tumor-reactive lymphocytes. Eight of the nineteen patients received immunotherapy on the basis of tumor-reactive T cells derived from the metinel nodes.

**Conclusions:** We demonstrate that it is possible to locate the first lymph nodes draining subcutaneous, lymphatic, and visceral metastases, the so-called metinel nodes. Metinel node-derived lymphocytes may be used to treat disseminated solid cancer, and clinical trials should evaluate the effect of such treatment.

**Key Words:** Solid tumors—Metastases—Sentinel node—Lymphatic mapping—Immunotherapy.

---

The global cancer registry Globocan shows 10.9 million new incident cases and 6.7 million deaths worldwide due to cancer in 2002.<sup>1</sup> A total of 24.6 million persons are estimated to be alive with cancer (within 3 years of diagnosis). Leading causes of death from cancer, in order, are those of the lung (1.18 million), stomach (700,000), and liver

(598,000). Most of these deaths were caused by metastatic disease, and they verify the fact that surgery and oncological therapy do not cure most patients with disseminated cancer. The incidence of cancer will continue to increase, especially in developing countries, largely due to smoking, infections, and lifestyles resembling those of people living in industrialized countries.<sup>1,2</sup> Thus, intensified efforts are warranted, both to prevent cancer and to find new modalities of treating patients with metastatic cancer.

---

Published online February 26, 2008.  
Address correspondence and reprint requests to: K. Dahl;  
E-mail: kjell.dahl@sodersjukhuset.se

Published by © The Author(s) 2008

Tumor cells spread by lymphogenous and hematogenous routes into the systemic circulation to disseminate the disease. The importance of tumor lymphangiogenesis has lately been proven in studies where high levels in colorectal cancer specimens of lymphangiogenic peptides, and vascular endothelial growth factor (VEGF)-C and/or VEGF-D promote tumor lymphangiogenesis and metastasis.<sup>3</sup> The sentinel node concept implies that the lymphatic drainage from a primary tumor first drains to a certain locoregional lymph node specific for each individual and that its tumor status is representative for the entire lymphatic field. The concept is established in staging for breast cancer<sup>4</sup> and malignant melanoma<sup>5</sup> and has also been evaluated in several other types of malignancies, such as colon cancer,<sup>6</sup> ovarian cancer,<sup>7</sup> pancreatic cancer,<sup>8</sup> and urinary bladder cancer.<sup>9</sup> The technique has been used as a diagnostic tool to improve staging and to tailor the extent of regional lymph node dissections. Probably most solid tumors disseminate first through the lymphatics and thereafter enter the systemic circulation via lymphovenous shunts present in the first draining lymph nodes.<sup>10-12</sup> Approximately half of the lymphatic fluid entering a lymph node continues directly into the systemic circulation; therefore, lymphogenic spreading of the tumor cells may be mandatory for hematogenic dissemination.<sup>3,13</sup>

However, to our knowledge, only one study has previously evaluated lymphatic mapping in metastases where liver metastases were investigated.<sup>14</sup> Because it has been proven that both metastases and primary tumors have the capacity to metastasize<sup>15-17</sup> and induce lymphangiogenesis,<sup>18</sup> we assume that lymphatic drainage from metastases may have an equal importance in metastases as the sentinel node concept in many solid primary tumors for correct staging. We have previously experienced surprises in lymphatic mapping within patients with colon cancer<sup>6</sup> and urinary bladder cancer<sup>9</sup> regarding primary tumor lymphatic drainage. We believe that a similar technique may be of use in surgery for liver metastases and other solid metastatic tumors for correct staging, and thereby for giving the patients the most appropriate therapy.

We previously showed that a sentinel node derived from a primary tumor contains specific tumor-reactive lymphocytes that have immunological reactivity toward the tumor in patients with colon cancer<sup>19</sup> and in patients with urinary bladder cancer.<sup>20</sup> Through the injection of Patent blue dye or radioactive tracer subserosally during surgery around the colonic tumor or transurethrally around the urinary bladder tumor, the sentinel nodes were found. A biopsy was

performed, and the nodes' immunological role and function were studied. After preparation, the lymphocytes were identified, isolated, and proliferated *in vitro* by stimulation of interleukins (ILs) and tumor antigen. Lymphocytes from sentinel nodes proliferated dose dependently and secreted interferon (IFN)- $\gamma$  on stimulation with tumor homogenate.

The aim of the present study was to investigate lymphatic drainage from metastases and identify first draining lymph nodes. We also analyzed tumor-reactive immunological properties in lymphocytes derived from these lymph nodes.

## MATERIALS AND METHODS

### Patients

Nineteen patients (9 men and 10 women, average age 51.5 years) with metastases from solid tumors were included in the study. Patient characteristics are shown in Table 1. The operations were performed during the period of November 2003 to January 2007. The study was approved by the local ethical committee, and each patient provided informed consent.

The lymph nodes that drained metastases were identified by injecting approximately 1 mL Patent blue dye (PB) (Guerbet, Paris) subserosally or subcutaneously in four places around one of the metastasis or in the tissues close to the local recurrences with a 27-gauge needle. After the injection of PB, the first draining lymph nodes turned blue within 3 to 10 minutes and were regarded as metastases-draining lymph nodes. In our previous work, a 10-minute cutoff was sufficient to identify sentinel nodes to primary tumors. We have experienced that during this period of time the first draining lymph nodes turn blue. Waiting longer means that a second echelon of draining lymph nodes may be colored blue, which does not represent the first draining lymph nodes. We arbitrarily applied the same 10-minute limit when detecting lymph nodes that drain metastases. These lymph nodes were either immediately removed or marked with sutures.

The sources of the liver metastases in our study were from colorectal cancer in five patients and in one patient each from ovarian cancer, breast cancer, cholangiocarcinoma, and leiomyosarcoma. Four patients had subcutaneous lymph node metastases from disseminated malignant melanoma, and one patient each had metastases from ovarian cancer, breast cancer, and squamous cell carcinoma of the tongue. Two patients had intra-abdominal local recurrences

TABLE 1. Patient characteristics<sup>a</sup>

Patient	Age (y)	Sex	Primary tumor	Origin metinel node	Tracer	Number of metinel nodes	Metinel node pos/neg for metastases	Successful expansion	Alive	Follow-up time (mo)
1	48	M	Colon	Intra-abdominal local recurrence	PB	3	3 neg	Yes	Yes	38
2	54	M	Rectum	Liver metastasis	PB	2	2 neg	Yes	Yes	38
3	50	M	Mal melanoma	Subcutaneous metastasis	PB	2	2 pos	No	No	–
4	77	F	Colon	Liver metastasis	PB	3	3 neg	No	No	–
5	74	M	Colon	Liver metastasis	PB	2	1 pos 1 neg	Yes	No	–
6	66	M	Colon	Liver metastasis	PB	1	MI	No	Yes	29
7	51	F	Ovarian cancer	Liver metastasis	PB	2	1 pos 1 neg	Yes <sup>b</sup>	No	–
8	64	F	Ovarian cancer	Groin lymph node	PB/RT	5	5 pos	No	No	–
9	59	F	Pancreatic cancer	Intra-abdominal local recurrence	PB	4	MI	No	No	–
10	39	F	Mal melanoma	Groin lymph node	PB/RT	4	2 neg	No	Yes	11
11	47	M	Mal melanoma	Truncal metastasis	RT	1	2 pos	No	No	–
12	45	F	Breast cancer	Cervical lymph node	PB/RT	2	2 neg	Yes	Yes	5
13	33	F	Tongue cancer	Truncal lymph node	RT	3	MI	No	Yes	6
14	64	F	Colon	Intra-abdominal local recurrence	PB	2	1 pos 1 neg	Yes	Yes	4
15	41	F	Breast cancer	Liver metastasis	PB	2	2 neg	No	Yes	4
16	39	M	Mal melanoma	Cervical lymph node	PB/RT	2	2 neg	No	Yes	2
17	20	M	Cholangiocarcinoma	Liver metastasis	PB	3	3 neg	Yes	No	–
18	65	M	Colon	Liver metastasis	PB	3	1 pos 2 neg	Yes	Yes	1
19	42	F	Leiomyosarcoma	Liver metastasis	PB	4	4 pos	Yes	Yes	1

pos, positive; neg, negative; Mal, malignant; PB, Patent blue dye; MI, missing information; RT, radioactive tracer ( $4 \times 10$ – $15$  MBq Tc-nanokolloid).

<sup>a</sup> Data regarding the expansions for patients 1, 2, 5, and 6 also exist in unpublished data.

<sup>b</sup> Patient died on the projected day of transfusion.

after surgery for colon cancer, and one patient had an intra-abdominal local recurrence after surgery for pancreatic cancer.

Because of these liver metastases, five patients underwent partial right-sided liver resections (patients 4, 5, 6, 15, and 17), and three patients underwent partial left-sided liver resection (patients 2, 18, and 19). The patient with metastases resulting from ovarian cancer (patient 7) had several large, bulky, cystic tumors, and surgeons performed an almost complete right-sided liver resection. In four cases, surgery was performed for solitary colorectal liver metastases (patients 2, 4, 5 and 6), and in the remaining five cases, tumor-reducing surgery was performed.

In six cases, a preoperative lymphoscintigraphy was performed by a subcutaneous injection of  $4 \times 10$  to  $15$  MBq Tc-nanokolloid radioactive tracer in quadrants around the metastasis. The lymphoscintigraphies were performed to plan the surgical procedure by localizing the lymph node or nodes draining the metastasis. The position of the metastasis-draining lymph node or nodes was marked on the skin with a felt-tip pen. When the lymphoscintigraphy was not performed on the day of surgery, a

new peritumoral injection of radioactive tracer was made at start of surgery. The draining nodes were intraoperatively identified by the use of a handheld gamma detection tube. In four of six cases, a simultaneous intraoperative injection of PB was performed.

### Preparation of Specimens

Lymph nodes draining metastases and nondraining lymph nodes (for analytical purposes) were surgically removed and immediately taken to the laboratory on ice. In addition, one 5-mm slice of the whole metastasis (including the invasive margin) was also dissected and sent for analysis. Frequently, most of the lymph node or nodes were used for the expansion procedure. The remaining specimens underwent routine histopathological examinations with hematoxylin and eosin staining. At the laboratory, slices  $< 1$  mm were cut from the central and peripheral part of the lymph nodes for analysis by flow cytometry (FACS) and proliferation analyses. The metastasis was also analyzed by FACS, and a preparation of the whole tumor (homogenate) was used.

### Immunological Evaluation

Single cell suspensions were made from the lymph nodes and metastases by gentle pressure with a loose-fitting glass homogenizer as previously described.<sup>19</sup> Briefly,  $1 \times 10^6$  cells were washed in phosphate-buffered saline containing 2% fetal calf serum and .05%  $\text{NaN}_3$ , then stained with fluorophore conjugated antibodies toward the cell surface markers CD4, CD8, CD19, and CD56 (Becton Dickinson). Thereafter the cells were investigated with a FACSCalibur (Becton Dickinson).

For cell cultures, single cell suspensions of metastasis-draining lymph node-derived cells were resuspended in RPMI 1640 proliferation media containing 10% human AB serum (Sigma), 1% penicillin-streptomycin (Sigma), and 1% glutamine (Sigma). For preparation of the antigen source, the metastasis was homogenized by an Ultra-turrax homogenizer in 5 volumes (w/v) of  $2 \times$  phosphate-buffered saline, followed by 5 minutes' denaturation at 95°C. This tumor homogenate was then used for in vitro activation and clonal expansion of lymphocytes. The metastasis-draining lymph node-derived lymphocytes were finally dispersed into cell culture flasks, at  $2 \times 10^6$  cells/mL of proliferation media, supplemented with 100 IU of IL-2 (Proleukin, Chiron) per milliliter of culture every 3 to 4 days. Tumor homogenate was diluted to 1:10 and 1:100 and added to the cell cultures after 3 to 4 days. After 1 to 3 weeks, the cell cultures were restimulated by irradiated peripheral blood mononuclear cells from the patient. These cells were collected by Ficoll-Hypaque centrifugation<sup>19</sup> and used as antigen-presenting cells for restimulation together with further addition of tumor homogenate. To verify clonal expansion of T lymphocytes,  $\text{V}\beta$  repertoire analyses were performed in a few cases. To test for functionality, single cell suspensions were investigated for Th1 and Th2 cytokine production,  $\text{IFN-}\gamma$ , and IL-4.

After an average period of 4 weeks, expanded cells were counted, evaluated by FACS, and investigated for the exclusion of malignant cells and bacteria before they were considered ready for transfusion. Cells were washed three times in .9% saline solution (Natriumchlorid Baxter Viaflo 9 mg/mL, Baxter) containing 2% human serum albumin (Baxter) and prepared in a sterile erythrocyte transfusion bag at  $4 \times 10^6$  cells/mL.

The transfusions took place at the surgical ward as an intravenous transfusion over the course of 1 hour. Our criterion for adoptive transfer is a transfusion of lymphocytes to a patient, regardless of the number of

transferred cells. In our previous studies (M.K., unpublished data) of adoptive transfer originating from sentinel nodes, on average, 71 million clonally expanded autologous tumor-reactive lymphocytes were transfused to each patient, and in that pilot study, the disease of all 16 patients responded to therapy. We do not know the optimal number of cells to be transfused for the best or maximum immune response, but according to our experience, 39.5 million transfused cells (the average number of transfused cells in the metinel node study) may be sufficient. The explanation may be that the CD4 cells proliferate and promote division of effector T cells and memory T cells when they are stimulated by their antigen (which is derived from the tumor). The cell expansion continues in the patient.

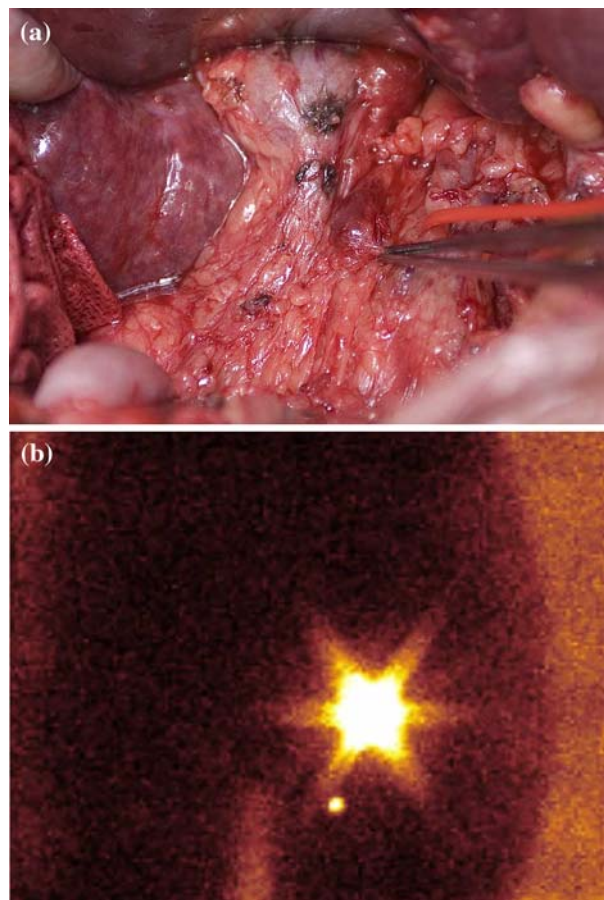
## RESULTS

### Metinel Nodes

Lymph nodes draining liver metastases, intra-abdominal recurrences, and subcutaneous metastases were identified in all 19 cases, with an average number of 2.6 nodes found per patient (range, 1–5) (Table 1). We denoted these metastasis-draining lymph nodes metinel nodes. Seventeen (40%) of the analyzed metinel nodes were positive for metastatic disease. In 4 (25%) of 16 patients where data were available, all metinel nodes were positive for metastatic disease (range, 2–5), and in 8 (50%) of 16 patients, all metinel nodes (range, 2–3) were negative for metastatic disease.

Tracer was injected around liver metastases ( $n = 9$ ), intra-abdominal recurrences ( $n = 3$ ), or close to subcutaneous metastases ( $n = 7$ ). Draining metinel nodes appeared visually blue (Fig. 1A) within 3 to 10 minutes after the injection of PB or were found to be disease positive by lymphoscintigraphy (Fig. 1B). No complications due to the lymph node mapping procedure were observed. The method seems valid for detecting the draining metinel node regardless of tumor type because the following were identified by this method: colorectal cancer ( $n = 7$ ), malignant melanoma ( $n = 4$ ), ovarian cancer ( $n = 2$ ), breast cancer ( $n = 2$ ), pancreatic cancer ( $n = 1$ ), squamous cell cancer ( $n = 1$ ), cholangiocarcinoma ( $n = 1$ ), and leiomyosarcoma ( $n = 1$ ). Thus, we conclude that lymph nodes draining liver metastases or local recurrences can readily be identified by this simple, safe, and quick procedure.





**FIG. 1.** (A) After intraoperative injection of Patent blue dye around liver metastasis in patient 18, the metinell node in the hepatoduodenal ligament is blue. (B) Preoperative percutaneous injection of  $4 \times 15$  MBq Tc-nanokolloid around ovarian cancer groin local recurrence (patient 8) demonstrates a medially and distally situated metinell node after 10 minutes.

In all cases of surgery for liver metastases, lymph nodes draining the area of the metastases were found within the liver hilum or hepatoduodenal ligament. The average number of metinell nodes from liver metastases were 2.4, and 7 (32%) of 22 of the analyzed metinell nodes were positive for metastatic disease. Two patients underwent surgery to treat intra-abdominal local recurrences from colon cancer (patients 1 and 14); resections of the recurrence and resection of the bowel en bloc were performed. One patient with pancreatic cancer (patient 9) underwent tumor-reducing surgery to treat a local intra-abdominal recurrence after a previous Whipple operation.

Four patients underwent surgery, with lymph node biopsies performed, to treat subcutaneous metastases from disseminated malignant melanoma (patients 3,

10, 11, and 16), and one patient each underwent surgery to treat subcutaneous metastases from disseminated breast cancer (patient 12), groin lymph node metastasis due to ovarian cancer (patient 8), and subcutaneous metastases related to squamous cellular carcinoma of the tongue (patient 13) (Table 1).

### Immunology

We previously demonstrated the presence of tumor-reactive T lymphocytes in primary tumor-draining sentinel nodes from patients with colon<sup>19</sup> and urinary bladder cancers.<sup>20</sup> Here, we investigated whether signs of immune recognition also occurred in metinell nodes draining metastases. Single cell suspensions were collected from identified metinell nodes and investigated by flow cytometry for the presence of  $CD4^+$ ,  $CD8^+$  T lymphocytes,  $CD19^+$  B lymphocytes, and  $CD56^+$  natural killer (NK) cells (Table 2). Most of the metinell nodes were predominated by  $CD4^+$  T helper cells, with an average  $CD4^+/CD8^+$  ratio of 2.3 (range, .1–6.6). However, five patients (patients 3, 6, 11, 12, and 19) displayed an increase in the fraction of  $CD8^+$  cytotoxic T cells. Two of these patients had malignant melanoma. The metinell nodes contained an average of 9.5% (range, .1–55)  $CD19^+$  B lymphocytes and an average of 2.1% (range, 0–18.9)  $CD56^+$  NK cells.

$CD4^+$  cells are crucial for initializing both the cellular and humoral immune response toward, for example, tumors.  $CD4^+$  cells recognize antigens expressed on major histocompatibility complex II and have the capacity to catalyze the immune response in B cells, Antigen presenting cells (APCs), and  $CD8^+$  cells.  $CD4^+$  cells have, compared with  $CD8^+$  cells, a long-term capacity of acting both as effector T cells and as memory cells.  $CD8^+$  cells are mainly effector cells and will act during a few weeks, but further recruitment of  $CD8^+$  cells is maintained by  $CD4^+$  cells. The expansion procedure aims to increase the number of  $CD4^+$  cells, and the  $CD4^+/CD8^+$  ratio can be regarded as a measurement of how well this can be achieved. The average ratio of  $CD4^+/CD8^+$  cells at the start of the procedure was 2.6 for patients who underwent successful expansions and 2.1 for patients who underwent unsuccessful expansions. Consequently, the  $CD4^+/CD8^+$  ratios were 24% higher for patients with successful expansions.

To test for recognition of tumor antigen, the number of metinell node-acquired lymphocytes from nine patients (patients 1, 2, 5, 7, 12, 14, 17, 18, and 19) were increased successfully by the addition of low

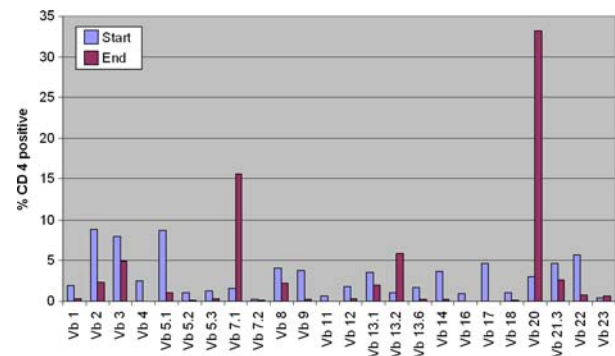
**TABLE 2.** Immunology of single cell suspensions collected from metinel nodes

Patient	Time in culture (d)	No. of cells at start (millions)	No. of cells at end (millions)	Ratio of cells start/end	Start (% gated), ratio CD4/CD8 and CD19/CD56	End, ratio CD4/CD8 and CD19/CD56	Ratio CD4/CD8 start	Ratio CD4/CD8 end
1	31	100	80	.8	24/11 and 55/-	24/16 and -/-	1.8	1.5
2	33	42	40	.95	51/15 and 13/-	24 and .12/-	3.4	1.5
3	28	-	-	-	8/39 and 1/-	-	.2	-
4	20	65.4	-	-	37/9 and -/-	-	4.1	-
5	43	130	-	1.3	47/7.1 and 28/1.3	73/22 and .09/1.7	6.6	3.3
6	6	5	-	-	.2/1.6 and .4/4	-	.125	-
7	6	5	.7	.02	16.4/6.5 and 24.2/1.6	-	2.5	-
8	52	42.6	-	-	15.9/7.6 and 9/3.4	-	2.1	-
9	15	12	-	-	-	-	-	-
10	74	166.8	5	.03	40/7 and .5/3	-	5.7	-
11	35	209	140	9.3	12.8/16.3 and 1.9/0	-	.8	-
12	31	285	2	.01	16.4/31.8 and .1/0	-	.5	-
13	24	3	-	-	-	-	-	-
14	32	30	1	.05	-	-	-	-
15	48	36	-	-	0/1 and 0/0	-	0	-
16	45	20	-	-	28.25/6.95 and 1.15/0	-	4.1	-
17	20	89	4	.04	5.8/2.6 and 4.2/2	34.2/30.4 and 7.6/20.1	2.2	1.1
18	29	67	4	.06	9.7/3.8 and 1.3/1	-	2.6	-
19	43	11	15	1.36	12.7/15.8 and 3/18.9	85/3 and .9/8.4	.8	28.3

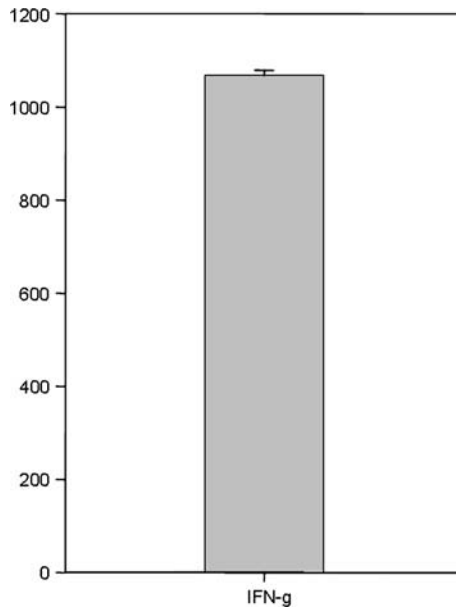
dose IL-2 and tumor homogenate. An average of  $97 \times 10^6$  cells (range,  $5-285 \times 10^6$ ) were collected, and the cells were expanded on average for 32 days before transfusion. At the time of transfusion, a mean of  $39.5 \times 10^6$  tumor-reactive T cells (range,  $.7-170 \times 10^6$ ) were returned (Table 2). In patient 7, cells were expanded and prepared for transfusion, but the patient suddenly died without receiving any cells. No side effects from transfusion of expanded T lymphocytes were seen, and the patients were discharged from the hospital on the same day of the transfusion. The expansions were successful in five of seven patients who had colorectal primary tumor; one of two in patients with ovarian cancer and breast cancer; and one patient each with cholangiocarcinoma and leiomyosarcoma. The following expansions failed in all patients: malignant melanoma (n = 4), pancreatic cancer (n = 1), and squamous cellular cancer (n = 1). An analysis of the CD4 Vβ repertoire from patient 11 was investigated by flow cytometry of metinel node-acquired lymphocytes (Fig. 2) and revealed an increase and clonal expansion of Vβ families 7.1, 13.2, and 20. In addition, analysis of the Vβ repertoire in two independently cultured metinel nodes derived from one breast cancer metastasis (patient 12) (data not shown) demonstrated clonal expansion after 12 days' short-term culture of the same T cell receptor families in both nodes (Vβ 4, Vβ 9, Vβ 20, and Vβ 21.3). We conclude that cultures of

metinel node-acquired lymphocytes expand in the presence of autologous tumor extract and IL-2.

Cells from patient 8, stimulated at the end of the expansion, demonstrated a high production of IFN-γ of >1000 pg/mL (Fig. 3) and no detectable IL-4 (data not shown), indicating a Th1 response. In an additional patient (patient 5), the stimulated IFN-γ secretion was 155 pg/mL while only a low IL-4 production of 30 pg/mL was found, again demonstrating a Th1-predominant response pattern.



**FIG. 2.** In patient 13, the T cell receptor Vβ repertoire was investigated by flow cytometry in two sentinel (nodes at the day of operation and after in vitro cell culture (43 days). Clonal expansion of Vβ families 7.1, 13.2, and 20 were detected in the CD4<sup>+</sup> T cell population.



**FIG. 3.** Amount of interferon gamma secreted into the supernatant measured by enzyme-linked immunosorbent assay. Data presented are for patient 7 after 35 days of in vitro cell culture.

According to more detailed analyses of some cases, we found that some T cells expressed Fox P3, indicating that these cells in fact were T regulatory cells.

## DISCUSSION

We show that it is possible to find the first lymph nodes draining various types of metastases by lymphatic mapping by means of dye or radioactive tracers. We have named these metastasis-draining lymph nodes “metinel nodes” to show both the analogy and difference to the well-known term “sentinel node,” which means the first node to receive lymphatic drainage from a primary tumor. In 19 studied cases, we demonstrated three different ways of identifying these nodes by injection of tracers subserosally around liver or intra-abdominal metastases, close to subcutaneous metastases, or into local lymph node metastases.

The fact that it is possible to expand the metinel node-derived lymphocytes via in vitro expansions during several weeks of time, together with our analysis that they contain lymphocytes that show clonal expansion toward tumor antigens and produce high levels of IFN- $\gamma$  in the expansions, are evidence that they contain tumor-reactive lymphocytes. These cells are mainly T-helper 1 cells that have developed an immunological response toward the metastatic

cells. We suggest that these T cells may be used in future trials of adoptive cellular therapy of disseminated solid cancer.

Studies have demonstrated that tumor growth beyond a certain size required angiogenesis<sup>21</sup> and that the amount of neovascularization peritumorally was a predictor of metastatic disease.<sup>22</sup> Far less is known about the specific factors regulating the lymphangiogenesis around a tumor and its possible importance, much as a result of the difficulty of discriminating between lymphatics and blood vessels. However, during recent years, the molecular pathways signaling for lymphangiogenesis have been described, and these studies have revealed that lymphangiogenesis is a major component of the metastatic process.

The lymphatic capillaries consist of thin-walled, low-pressure vessels that drain the interstitium. When the surrounding interstitial fluid pressure increases, the walls of the lymphatics are stretched and open to passage of cells or fluids. The lymphatic capillaries are joined into major lymphatic collecting vessels and filtered through at least one lymph node before entering the venous circulation.<sup>23</sup> After entering the node, approximately half of the lymphatic fluid continues directly into the blood before the rest drains into an efferent lymphatic vessel.<sup>24</sup>

A malignant tumor causes a peritumoral increase of lymphatic vessels mediated through VEGF. Studies have shown that high levels of the cytokine cascade of VEGF-C and VEGF-D promote the tumoral lymphangiogenesis and that inhibition of their joint receptor, VEGFR-3, suppresses the effects. Kawakami et al.<sup>25</sup> showed that high levels of VEGF-C and its receptor, VEGFR-3, correlated with increased lymph node metastases and lymphatic invasion in human colorectal cancer. White et al.<sup>26</sup> concluded that patients operated on for colon cancer had an overexpression of VEGF-D, but not of its receptor VEGFR-3, which correlated with a decrease in disease-free interval and overall survival. A study based on 110 patients with breast cancer showed that lymph vessels were present more often in metastatic axillary lymph nodes (85%) than in nonmetastatic lymph nodes (25%),<sup>18</sup> and that intranodal and perinodal lymphatic endothelial cell proliferation fractions were higher in metastatically involved lymph nodes. Taken together, all these findings support lymphangiogenesis in metastases.

Thus, a tumor causes an upregulation of lymphangiogenic factors that leads to an increase in peritumoral lymphatic vessels in both tumors and metastases. It is likely that these newly developed

lymph vessels connect to the preexisting lymphatic vessels and lymph nodes. Shed tumor cells may invade these newly formed vessels, and the dissemination of tumor cells is facilitated. The present study shows that this process can be visualized by lymphatic mapping, and the first draining lymph node from the metastasis, the metinel node, may be identified.

Animal studies showed that metastases had the capacity to metastasize. Mice inoculated with pulmonary venous blood from mice having pulmonary metastases developed disseminated cancer disease after injection into the tail vein, showing that pulmonary metastases shed viable circulating cells.<sup>16</sup> Similarly, Hoover and Ketcham<sup>15</sup> demonstrated that mice who had undergone amputation of their primary tumors and now only had pulmonary metastases experienced spread of the tumor cells specifically into the lungs after parabiosis.

In surgery for colorectal liver metastases, it is not standard to perform a biopsy of perihepatic lymph nodes. Nakamura et al.<sup>27</sup> reported a 4-year survival of 40% in node-positive patients, but the study cohort was small. Most studies identify few 5-year survivors after liver resection for colorectal liver metastases involving positive perihepatic lymph nodes.<sup>28</sup> These lymph node metastases are unlikely to be of lymphatic origin from the primary colonic tumor; instead, they may be explained by hematogenous spread to the liver followed by lymphogenic spreading from the liver metastases to the perihepatic lymph nodes.<sup>29</sup> Correct perihepatic lymphatic staging is beyond dispute, not only because the increased morbidity in patients having perihepatic lymph node metastases, but also because of the improvements in systemic therapies. In the nine cases of resected liver metastases in our study, all metinel nodes were found among perihepatic nodes within the hepatoduodenal ligament or liver hilum. Most of the liver is drained by deep hepatic lymphatics, the upper inner part of the liver drains to nodes around the end of inferior caval vein, and the lower inner part drains to hepatic nodes through the liver hilum.<sup>30</sup> The superficial part of the liver lymphatic drainage is divided into two main directions; the posterior surface drains into pericaval nodes, and the inferior, anterior, and superior surface drains into hepatic nodes through the liver hilum. In all cases of resected liver metastases, the injections of PB were performed subserosally on the inferior, anterior, or superior surface of the liver. Our identified perihepatic metinel nodes were located corresponding to the superficial lymphatic drainage of the liver.

Despite the prognostic importance of these perihepatic lymph nodes, we have only found one article in the literature describing lymphatic mapping originating from liver metastases. Kane et al.<sup>14</sup> demonstrated in a study of 11 patients with colorectal liver metastases that it was possible to perform lymphatic mapping by the intraoperative injection of isosulfan blue dye in a peritumoral and subcapsular manner. The basic premise was that the occurrence of extrahepatic metastases within the normal lymphatic drainage of the liver was considered to be remetastases from the colorectal metastases. They found blue-colored nodes in seven patients (54%), all within the liver hilum, falciform ligament, or gallbladder fossa. In three of these patients, the nodes were not detected by the surgeon before the mapping procedure. Like our results, they concluded that hepatic lymphatic mapping was safe, rapid, and simple technique to perform in humans.

The importance of lymphatic mapping in liver surgery for metastases was underlined by Grobmyer et al.,<sup>31</sup> who concluded that routine lymph node sampling had a low yield in patients without suspected perihepatic disease by computed tomographic scan or positron emission tomography, or at surgical exploration. Further, another study demonstrated that microscopic perihepatic positive lymph node disease is associated with the same poor prognosis as in macroscopic positive disease and suggests, therefore, that lymph node dissection should be systematic.<sup>32</sup>

Lymphoscintigraphy has been used to find sentinel nodes from primary tumors,<sup>33</sup> but to our knowledge, it has not been reported as a tool to locate lymph nodes draining subcutaneous metastases. The radioactive tracer facilitated the intraoperative identification of the metinel nodes by a gamma probe used as a complement to PB. In those cases, the lymphoscintigraphy was made days before surgery, and new injections of radioactive tracers were provided on the day of surgery. One to three metinel nodes were detected in our six patients.

In the late 1950s, the immunosurveillance hypothesis was introduced<sup>34</sup> supporting the fact that tumor cells possessed new antigenic potentials and provoked an immunological reaction that could eradicate a tumor completely. In the last decade, the hypothesis has been proven in mice and humans. The role of the immune system in cancer diseases is demonstrated by immunodeficient patients having both an overrepresentation of virus-induced malignancies and an increased probability of developing cancer of nonviral cause. Cardiac transplant recipients have, for exam-



ple, been shown to have a 25-fold higher prevalence of lung tumors than the general population.<sup>35</sup> Much data also supports the fact that both the cellular and the humoral immune systems develop immune responses against tumors. Bevacizumab, a monoclonal antibody against VEGF, functions as an inhibitor of angiogenesis, inhibits growth of human tumor cells in mice, and prolongs the overall median survival in human metastatic colorectal cancer.<sup>36</sup> The presence of tumor-reactive lymphocytes in sentinel nodes<sup>19,20</sup> is an example of the function of the cellular immune system and a positive prognostic factor for survival in colorectal and ovarian cancer.<sup>37–39</sup>

In our earlier study, we made a single cell suspension of the lymphocytes from sentinel nodes. They were expanded in vitro, stimulated by tumor homogenate, IL-2, and antigen-presenting cells. In the present expansions, we proved it was possible to find tumor-reactive lymphocytes in metinel nodes and to perform adoptive immunotherapy based on them. The preliminary results seems promising, with total or partial regression of some liver and lung metastases (M.K., unpublished data). In this study, the expansions were performed in exactly the same way as in our previous studies, except that the source of the lymphocytes was derived from lymph nodes draining metastases—that is, metinel nodes. The fact that we succeeded in nine cases in proliferating the lymphocytes via in vitro expansions over more than a month is evidence for the presence of tumor-reactive lymphocytes. Because the expansions were continuously stimulated with autologous tumor homogenate and antigen-presenting cells together with IL, only lymphocytes that were a priori stimulated by antigens derived from the tumor could proliferate and survive for such a long time. Figure 2 demonstrates the V $\beta$  repertoire in CD4-positive cells in two metinel nodes in patient 11, thus showing which types of T-helper cell receptors were found at the end of expansion. The figure shows clonal expansion of V $\beta$  7.1, 13.2, and 20, demonstrating the presence of tumor-reactive lymphocytes toward three different types of tumor antigens.

These collective facts point out the presence of tumor-reactive type 1 T-helper lymphocytes in metinel nodes. T helper lymphocytes play a central role in initiating the adoptive immune defense. In 9 of 19 patients, the cells survived until the time for transfusion, and 8 patients underwent intravenous adoptive autologous T cell transfusion. Approximately half of all patients who underwent the expansion procedure died as a result of a combination of too few cells at the start and the initial presence of

immunosuppressive factors that not could be overcome. Six of eight patients who received transfusions are still alive, although the follow-up time varies (Table 1). Our results are encouraging because the prognosis in these type of cases is usually poor.

In this study, we have shown that it is possible to find the draining lymph nodes from different types of metastases. We named these nodes “metinel nodes,” and they contain tumor-reactive lymphocytes, preferentially T-helper cells with Th1 response. We have also demonstrated that it is possible to proliferate these cells in vitro and, if the expansion procedure is successful, to use the cells for adoptive immunotherapy.

---

#### ACKNOWLEDGMENTS

This work was supported by the Swedish Cancer Society, the Cancer and Allergy Society, the Hedlunds Foundation, the Lundberg Foundation, Gustav V Foundation, the Selander Foundation, and the Söderbergs Foundation. O.W. and M.T. are founders and minority shareholders of Sentoclone AB.

---

#### OPEN ACCESS

This article is distributed under the terms of the Creative Commons Attribution Noncommercial License which permits any noncommercial use, distribution, and reproduction in any medium, provided the original author(s) and source are credited.

---

#### REFERENCES

1. Parkin DM, Bray F, Ferlay J, et al. Global cancer statistics, 2002. *CA Cancer J Clin* 2005; 55:74–108.
2. Kamangar F, Dores GM, Anderson WF. Patterns of cancer incidence, mortality, and prevalence across five continents: defining priorities to reduce cancer disparities in different geographic regions of the world. *J Clin Oncol* 2006; 24:2137–50.
3. Nathanson SD. Insights into the mechanisms of lymph node metastasis. *Cancer* 2003; 98:413–23.
4. Lyman GH, Giuliano AE, Somerfield MR, et al. American Society of Clinical Oncology guideline recommendations for sentinel lymph node biopsy in early-stage breast cancer. *J Clin Oncol* 2005; 23:7703–20.
5. Thompson JF, Scolyer RA, Kefford RF. Cutaneous melanoma. *Lancet* 2005; 365:687–701.
6. Dahl K, Westlin J, Kraaz W, et al. Identification of sentinel nodes in patients with colon cancer. *Eur J Surg Oncol* 2005; 31:381–5.
7. Negishi H, Takeda M, Fujimoto T, et al. Lymphatic mapping and sentinel node identification as related to the primary sites of lymph node metastasis in early stage ovarian cancer. *Gynecol Oncol* 2004; 94:161–6.

8. Ohta T, Kitagawa H, Kayahara M, et al. Sentinel lymph node navigation surgery for pancreatic head cancers. *Oncol Rep* 2003; 10:315–9.
9. Sherif A, De La Torre M, Malmstrom PU, et al. Lymphatic mapping and detection of sentinel nodes in patients with bladder cancer. *J Urol* 2001; 166:812–5.
10. Sherif A, Garske U, De la Torre M, et al. Hybrid SPECT-CT: an additional technique for sentinel node detection of patients with invasive bladder cancer. *Eur Urol* 2006; 50:83–91.
11. Alitalo K, Mohla S, Ruoslahti E. Lymphangiogenesis and cancer: meeting report. *Cancer Res* 2004; 64:9225–9.
12. Padera TP, Kadambi A, di Tomaso E, et al. Lymphatic metastasis in the absence of functional intratumor lymphatics. *Science* 2002; 296:1883–6.
13. Poste G, Fidler IJ. The pathogenesis of cancer metastasis. *Nature* 1980; 283:139–46.
14. Kane JM 3rd, Kahlenberg MS, Rodriguez-Bigas MA, et al. Intraoperative hepatic lymphatic mapping in patients with liver metastases from colorectal carcinoma. *Am Surg* 2002; 68:745–50.
15. Hoover HC Jr, Ketcham AS. Metastasis of metastases. *Am J Surg* 1975; 130:405–11.
16. Ketcham AS, Ryan JJ, Wexler H. The shredding of viable circulating tumor cells by pulmonary metastases in mice. *Ann Surg* 1969; 169:297–9.
17. Weiss L, Holmes JC, Ward PM. Do metastases arise from pre-existing subpopulations of cancer cells? *Br J Cancer* 1983; 47:81–9.
18. Van den Eynden GG, Van der Auwera I, Van Laere SJ, et al. Induction of lymphangiogenesis in and around axillary lymph node metastases of patients with breast cancer. *Br J Cancer* 2006; 95:1362–6.
19. Marits P, Karlsson M, Dahl K, et al. Sentinel node lymphocytes: tumour reactive lymphocytes identified intraoperatively for the use in immunotherapy of colon cancer. *Br J Cancer* 2006; 94:1478–84.
20. Marits P, Karlsson M, Sherif A, et al. Detection of immune responses against urinary bladder cancer in sentinel lymph nodes. *Eur Urol* 2006; 49:59–70.
21. Folkman J. Tumor angiogenesis: therapeutic implications. *N Engl J Med* 1971; 285:1182–6.
22. Weidner N, Semple JP, Welch WR, et al. Tumor angiogenesis and metastasis—correlation in invasive breast carcinoma. *N Engl J Med* 1991; 324:1–8.
23. Baldwin ME, Stacker SA, Achen MG. Molecular control of lymphangiogenesis. *Bioessays* 2002; 24:1030–40.
24. Renkin EM. Some consequences of capillary permeability to macromolecules: Starling's hypothesis reconsidered. *Am J Physiol* 1986; 250:H706–10.
25. Kawakami M, Furuhashi T, Kimura Y, et al. Quantification of vascular endothelial growth factor-C and its receptor-3 messenger RNA with real-time quantitative polymerase chain reaction as a predictor of lymph node metastasis in human colorectal cancer. *Surgery* 2003; 133:300–8.
26. White JD, Hewett PW, Kosuge D, et al. Vascular endothelial growth factor-D expression is an independent prognostic marker for survival in colorectal carcinoma. *Cancer Res* 2002; 62:1669–75.
27. Nakamura S, Yokoi Y, Suzuki S, et al. Results of extensive surgery for liver metastases in colorectal carcinoma. *Br J Surg* 1992; 79:35–8.
28. Rodgers MS, McCall JL. Surgery for colorectal liver metastases with hepatic lymph node involvement: a systematic review. *Br J Surg* 2000; 87:1142–55.
29. August DA, Sugarbaker PH, Schneider PD. Lymphatic dissemination of hepatic metastases. Implications for the follow-up and treatment of patients with colorectal cancer. *Cancer* 1985; 55:1490–4.
30. Standring S. Gray's Anatomy 39th ed. London: Churchill Livingstone, Elsevier; 2005 pp 1221–2.
31. Grobmyer SR, Wang L, Gonen M, et al. Perihepatic lymph node assessment in patients undergoing partial hepatectomy for malignancy. *Ann Surg* 2006; 244:260–4.
32. Laurent C, Sa Cunha A, Rullier E, et al. Impact of microscopic hepatic lymph node involvement on survival after resection of colorectal liver metastasis. *J Am Coll Surg* 2004; 198:884–91.
33. Barrett T, Choyke PL, Kobayashi H. Imaging of the lymphatic system: new horizons. *Contrast Media Mol Imaging* 2006; 1:230–45.
34. Burnet FM. The concept of immunological surveillance. *Prog Exp Tumor Res* 1970; 13:1–27.
35. Pham SM, Kormos RL, Landreneau RJ, et al. Solid tumors after heart transplantation: lethality of lung cancer. *Ann Thorac Surg* 1995; 60:1623–6.
36. Thornton AD, Ravn P, Winslet M, et al. Angiogenesis inhibition with bevacizumab and the surgical management of colorectal cancer. *Br J Surg* 2006; 93:1456–63.
37. Pages F, Berger A, Camus M, et al. Effector memory T cells, early metastasis, and survival in colorectal cancer. *N Engl J Med* 2005; 353:2654–66.
38. Zhang L, Conejo-Garcia JR, Katsaros D, et al. Intratumoral T cells, recurrence, and survival in epithelial ovarian cancer. *N Engl J Med* 2003; 348:203–13.
39. Galon J, Costes A, Sanchez-Cabo F, et al. Type, density, and location of immune cells within human colorectal tumors predict clinical outcome. *Science* 2006; 313:1960–4.