

POSTER PRESENTATION

Open Access

Accuracy and precision of chronic myocardial infarct characterization with native T₁ mapping at 3T

Avinash Kali*, Ivan Cokic, Hsin-Jung Yang, Behzad Sharif, Rohan Dharmakumar

From 18th Annual SCMR Scientific Sessions
Nice, France. 4-7 February 2015

Background

Native T₁-mapping at 3T has been shown to reliably characterize chronic myocardial infarctions (MIs). In this study, we evaluated the accuracy and precision of different thresholding techniques and visual delineation for characterizing chronic MIs on native T₁ maps at 3T.

Methods

Canines (n=23) underwent CMR at 4 months following MI. Native T₁ maps (MOLLI; 8 TIs with 2 inversion blocks of 3+5 images; minimum TI=110ms; ΔTI=80ms; TR/TE=2.2/1.1ms) and Late Gadolinium Enhancement images (LGE; IR-prepared FLASH; TI optimized to null remote myocardium; TR/TE=3.5/1.75ms) were acquired at 3T. Infarct size and transmuralty measured using Mean + 2 standard deviations (SD), Mean+3SD, Mean+4SD, Mean+5SD, Mean+6SD, Otsu's, and visual delineation methods were compared against the Mean+5SD LGE measurements, and their relative diagnostic performance was evaluated.

Results

Relative to LGE images, mean infarct size and transmuralty measured from native T₁ maps were significantly over-estimated by Mean+2SD, Mean+3SD, and Mean+4SD techniques (p<0.001, for all cases). Mean+6SD criterion and visual delineation significantly underestimated infarct size (p<0.001 for both cases) and transmuralty (p=0.01 for Mean+6SD; p<0.001 for visual) on native T₁ maps. Otsu's technique showed no difference for measuring infarct size on native T₁ maps compared to LGE images (p=0.27), but it over-estimated the infarct transmuralty (p<0.001). Mean+5SD criterion

showed no difference for measuring either infarct size (p=0.61) or transmuralty (p=0.81) on T₁ maps relative to LGE images. Mean CNR of LGE images was nearly 4-fold higher than that of native T₁ maps (p<0.001). Mean+5SD criterion for detecting chronic MIs on native T₁ maps at 3T showed the strongest diagnostic performance (area-under-curve=0.99, p<0.001), while visual delineation showed the weakest diagnostic performance (area-under-curve=0.84, p<0.001).

Conclusions

Threshold-based analysis using Mean+5SD criterion can accurately and precisely estimate the size, location and transmuralty of chronic MIs on native T₁ maps as reliably as LGE at 3T.

Funding

American Heart Association (13PRE17210049) and National Heart, Lung, And Blood Institute (HL091989).

Published: 3 February 2015

doi:10.1186/1532-429X-17-S1-P166

Cite this article as: Kali et al.: Accuracy and precision of chronic myocardial infarct characterization with native T₁ mapping at 3T. *Journal of Cardiovascular Magnetic Resonance* 2015 **17**(Suppl 1):P166.

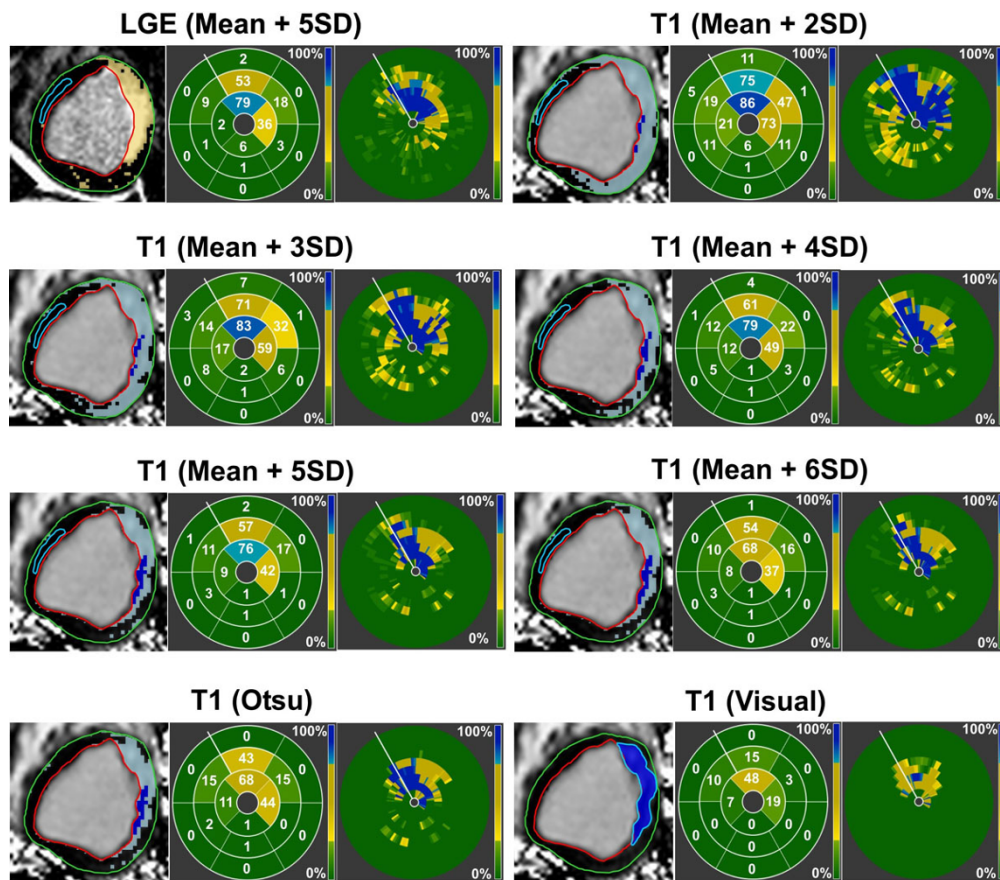


Figure 1 Infarcted myocardium (highlighted pixels) detected using the Mean+5SD criterion on LGE images, and different thresholding criteria and visual delineation techniques on T₁ maps are shown. Relative to LGE images, significant over-estimation in the spatial extent, AHA-segmental infarct size, and transmuralty could be observed with Mean+2SD and Mean+3SD techniques on T₁ maps. Native T₁ maps showed closer agreement to LGE images when Mean+4SD, Mean+5SD, Mean+6SD, and Otsu's techniques were used. Visual delineation significantly under-estimated the spatial extent and transmuralty of the infarction on T₁ maps.

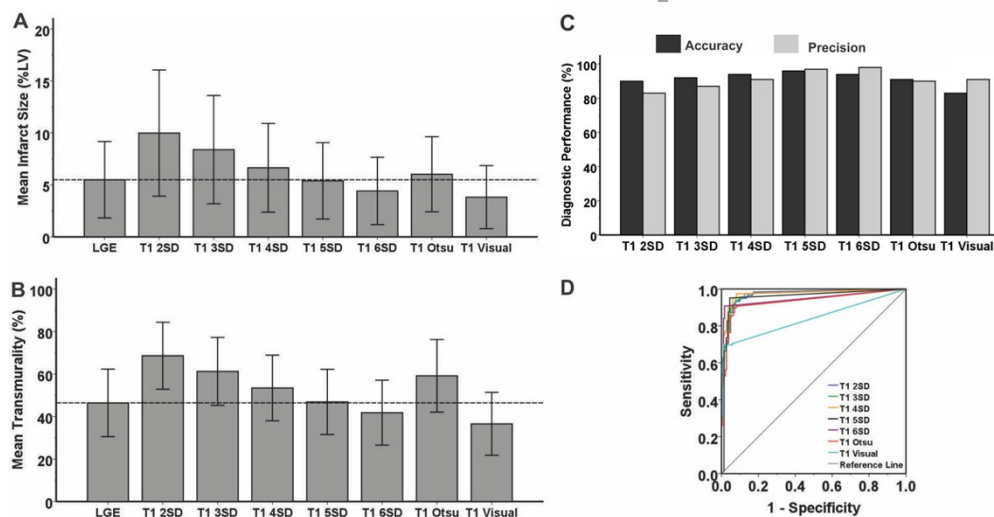


Figure 2 Bar plots compare the mean infarct size (A) and transmuralty (B) measured using different thresholding and visual delineation techniques on native T₁ maps to those measured on LGE images using Mean+5SD criterion. Bar plots comparing the accuracy and precision of different thresholding and visual delineation techniques to detect chronic MI are also shown (C). Of all the techniques used for infarct characterization on T₁ maps, Mean+5SD criterion showed the best agreement to LGE images. ROC analysis (D) showed the strongest diagnostic performance for Mean+5SD technique, and the weakest diagnostic performance for visual delineation.