

Case report

Open Access

Choroidal melanoma metastasizing to maxillofacial bones

Manoj Pandey*^{1,4}, Om Prakash⁵, Anitha Mathews², Nileena Nayak² and Krishnankutty Ramachandran³

Address: ¹Division of Surgical Oncology, Regional Cancer Centre, Trivandrum, Kerala, India, ²Pathology, Regional Cancer Centre, Trivandrum, Kerala, India, ³Imagiology, Regional Cancer Centre, Trivandrum, Kerala, India, ⁴Surgical Oncology, Institute of Medical Sciences, Banaras Hindu University, Varanasi, India and ⁵Oral and Maxillofacial Surgery, Government Dental College, Thiruvananthapuram, India

Email: Manoj Pandey* - manojpandey@vsnl.com; Om Prakash - omprakash3@rediffmail.com; Anitha Mathews - Anitha@rcctvm.org; Nileena Nayak - neelina@rcctvm.org; Krishnankutty Ramachandran - ramachandran@rcctvm.org

* Corresponding author

Published: 8 March 2007

Received: 26 December 2006

Accepted: 8 March 2007

World Journal of Surgical Oncology 2007, 5:30 doi:10.1186/1477-7819-5-30

This article is available from: <http://www.wjso.com/content/5/1/30>

© 2007 Pandey et al; licensee BioMed Central Ltd.

This is an Open Access article distributed under the terms of the Creative Commons Attribution License (<http://creativecommons.org/licenses/by/2.0>), which permits unrestricted use, distribution, and reproduction in any medium, provided the original work is properly cited.

Abstract

Background: Melanomas are malignant neoplasm of melanocytic origin, commonly seen on skin and various mucous membranes. Melanomas are the commonest intraocular malignant tumour in the adults.

Case presentation: A 50-year-old female presented with complains of painless progressive swelling in right cheek region of two months duration. Examination revealed a 6 × 4 cm bony hard swelling in right zygomatic region near and below lateral canthus of right eye with loss of vision. Investigations revealed it to be a choroidal melanoma metastasizing to the zygomatic bone. Patient was successfully treated by surgery.

Conclusion: Choroidal melanoma, which commonly metastasizes to liver and lungs, never involves the lymph nodes and metastasis to facial bones is rare. Here we report a case of choroidal melanoma metastasizing to maxillofacial bones.

Background

Choroidal melanoma is the most common primary intraocular malignant tumour [1]. They arise from uveal melanocytes residing in the uveal stroma and originating from the neural crest [2]. Choroidal melanomas are quite different from their cutaneous counterparts with regards to presentation, metastatic pattern and treatment. The incidence of intraocular melanoma is less than 1 per 100000 [3]. Spread to the liver is the most frequent while metastases [4] to other sites (lung [5], heart [6,7], gastrointestinal tract, lymph nodes [8], pancreas, skin, central nervous system [9], bones, spleen, adrenal [10], kidneys, ovaries [11], thyroid [12], contralateral choroids [13] breast [14]) generally occur in association with liver

metastases [2]. Lymphatic spread has not been demonstrated, consistent with the absence of lymphatics in the choroid. To our knowledge choroidal melanoma metastasizing to the maxillofacial bones and presented with malar swelling is never been reported before.

Case presentation

A 50-year-old female presented with complains of painless progressive swelling in right cheek region of two months duration. Examination revealed a 6 × 4 cm bony hard swelling in right zygomatic region near and below lateral canthus of right eye (Figure 1) Roentgenogram of the paranasal sinuses showed a lesion arising from right maxilla and right zygo. Computerized tomographic

(CT) scan revealed two separate masses one in right orbit and other infiltrating zygoma and maxilla (Figure 2), radiographic picture was suggestive of osteogenic sarcoma or Ewing's sarcoma. A fine needle aspiration was carried out that showed typical polygonal and spindle cells with moderate amount of cytoplasm and vesicular nuclei with nucleoli, many with intracellular pigment; seen singly and clusters, the picture was suggestive of malignant melanoma (Figure 3). The ophthalmologic consultation revealed that there was no useful vision in the right eye. A B-scan of the right eye showed an organized mass within the vitreous cavity indicating vitreous haemorrhage (figure 4). A detailed clinical examination failed to show any other melanocytic lesion on skin and other mucus membranes.

With a provisional diagnosis of melanoma of the maxilla and zygoma with vitreous haemorrhage and no useful vision in right eye a wide excision of the lesion including

anterolateral maxillectomy, zygomectomy, and removal of superolateral wall and floor of orbit with en bloc exenteration of the right eyeball was carried out (Figure 5). Histopathological examination of the resected eyeball specimen showed a neoplasm in choroid, filling posterior chamber with no extraocular extensions, composed of sheets, nests and cords of polygonal cells and vesicular nuclei. Prominent nucleoli and eosinophilic cytoplasm containing abundant melanin pigment were noted (figure 6). Similar tumours were seen in the extra ocular soft tissue and resected maxilla and zygomatic bones. A final diagnosis of choroidal melanoma metastasizing to maxillofacial bones was made. Differential diagnosis of primary bone melanoma with metastasis to choroids was kept.

Surgical excision was followed by 40 Gy./15 fractions of radiotherapy to right face using lateral portal. Patient is on regular follow-up two years after surgery and is free of any local or systemic recurrences.



Figure 1
Clinical photograph showing swelling in right zygomatic region.

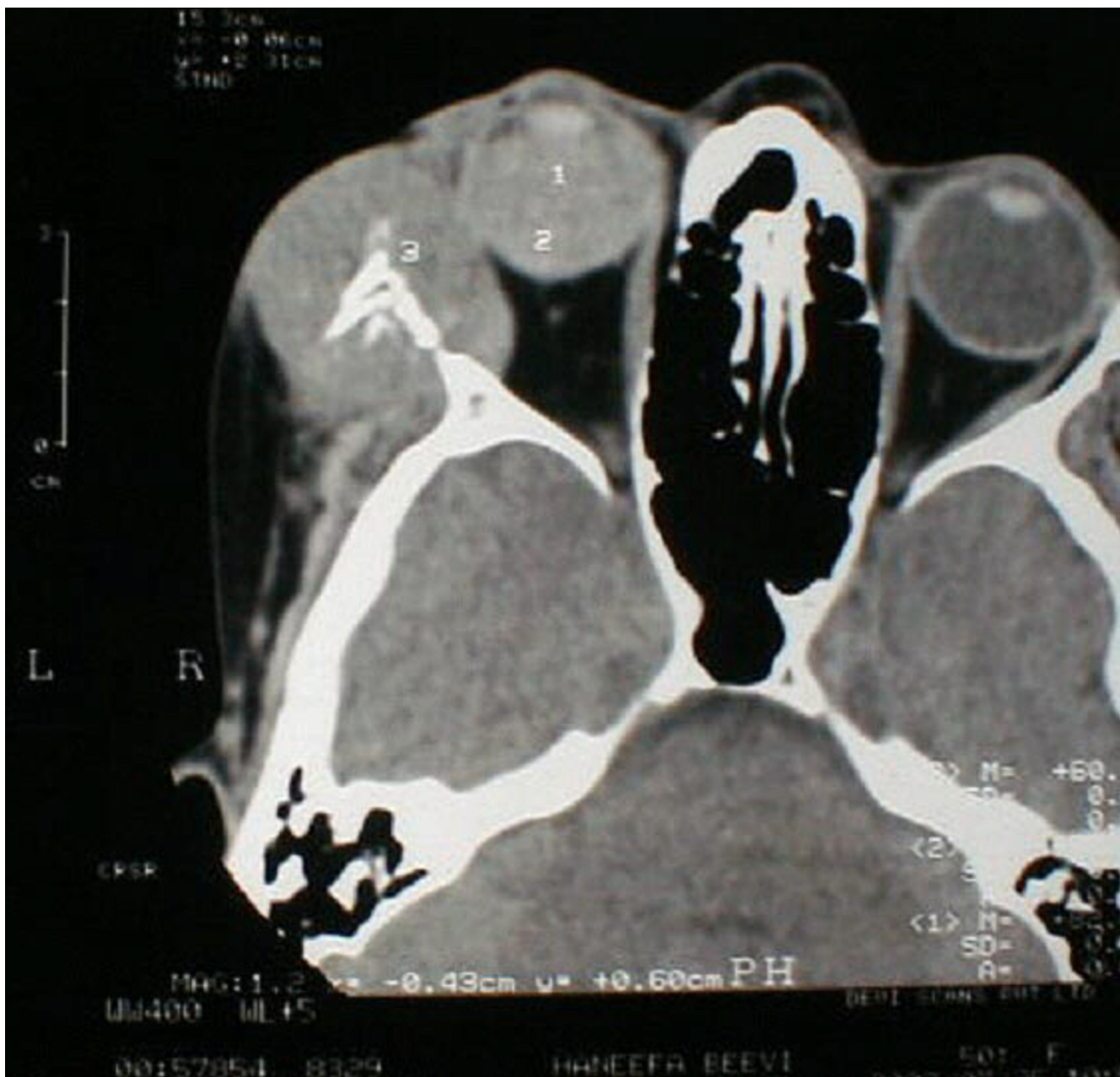

Figure 2
Computed tomographic scan showing two separate lesions one in right orbit and other in right zygoma, zygomatic process of maxilla.

Discussion

Malignant neoplasms of melanocytic origin, malignant melanoma is rare in soft tissue and bone. In eyes it may involve choroids, ciliary body, retina or conjunctiva [15-17]. Choroidal melanomas are commonly asymptomatic and are often discovered during routine ophthalmic examination however; in some cases it may produce symptoms like loss of vision, photopsias and visual field

defects [18]. Intraosseous malignant melanoma on the other hand is extremely rare [15].

Diagnosis of choroidal melanoma is based on ophthalmoscopy, fluorescent angiography, scleral transillumination, B-scan ultrasonography, and sequential diagnostic examination [19]. Tumour markers like TA-90 IC, Melan A, HMB-45, S-100 add to diagnostic accuracy [20]. The

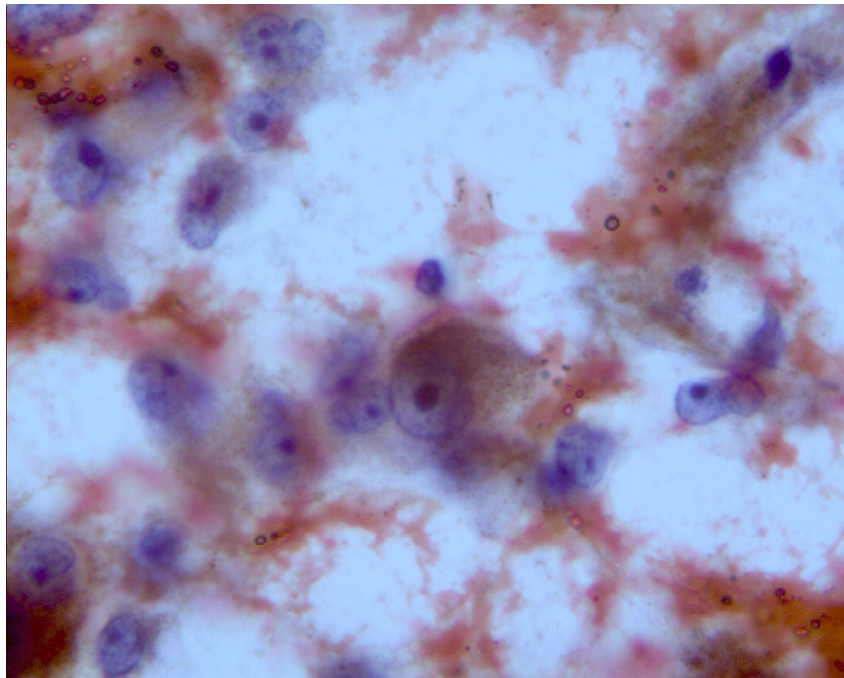


Figure 3
Photomicrograph of FNAC showing typical polygonal and spindle cells with moderate amount of cytoplasm and vesicular nuclei with nucleoli (Haematoxylin & Eosin original magnification $\times 100$).

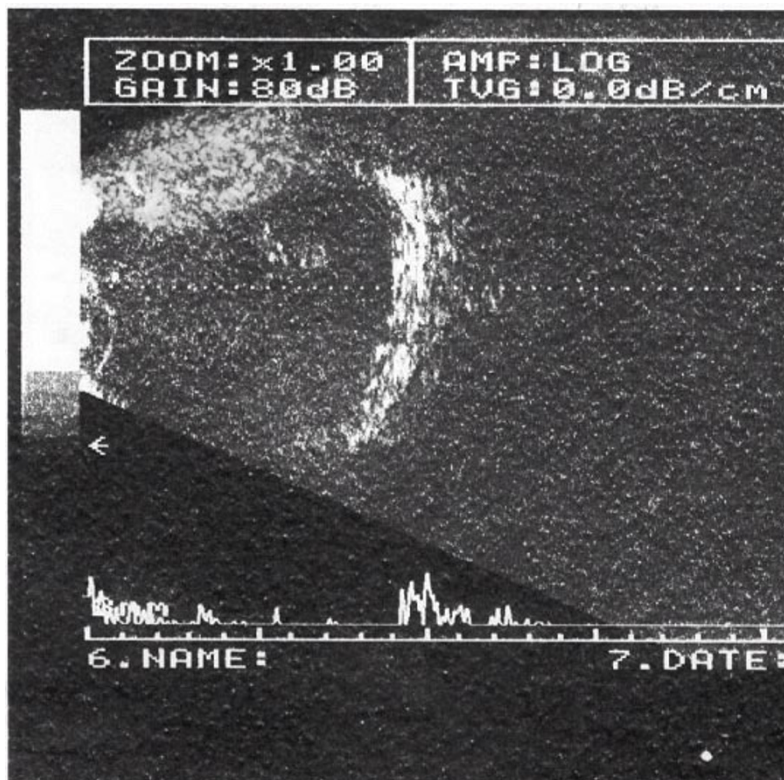


Figure 4
B-scan of the right eye showing an organized mass within the vitreous cavity suggestive of vitreous haemorrhage.

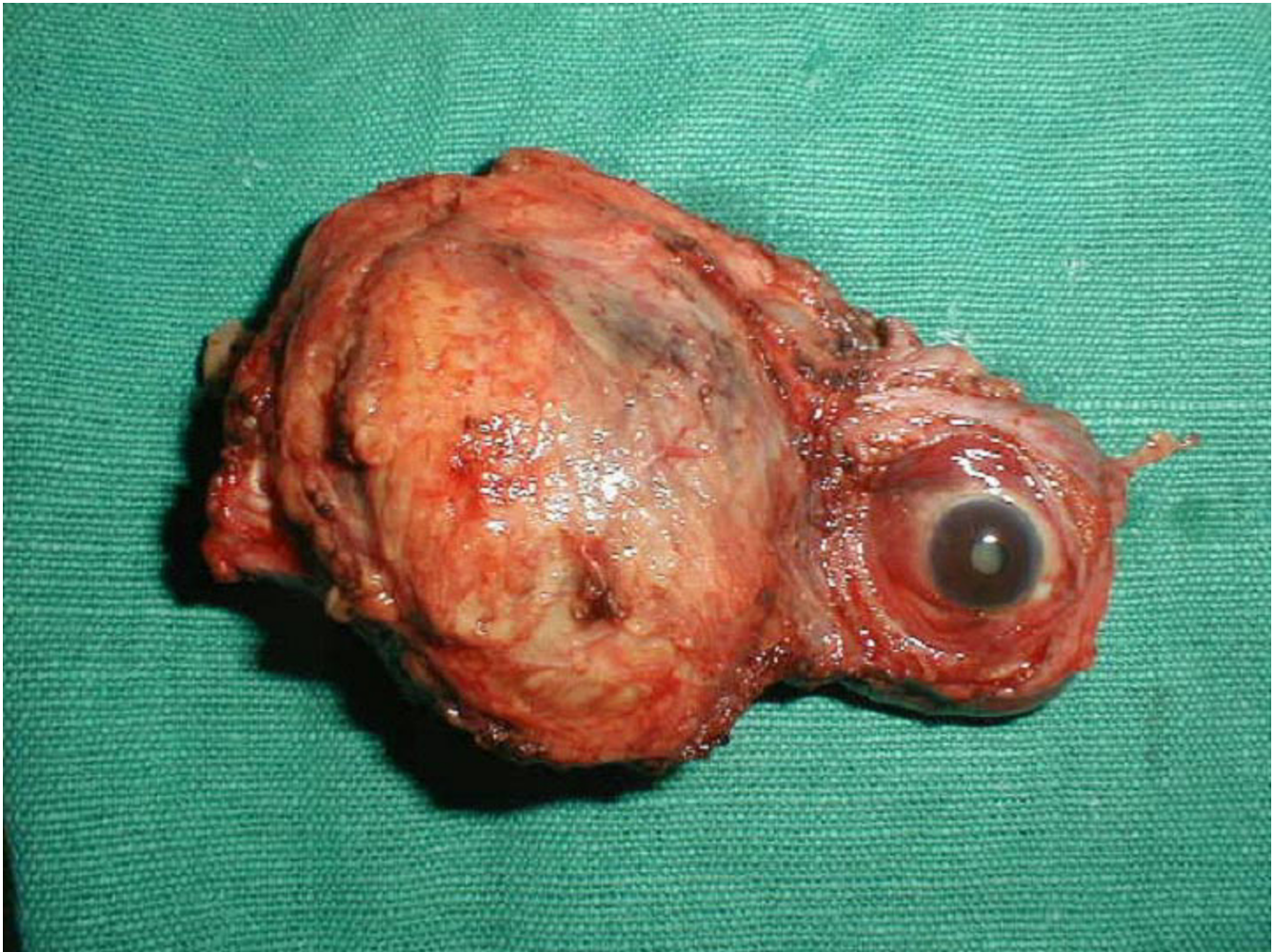

Figure 5
Photograph showing resected tumour with eyeball exenteration.

classic signs of melanoma seen with B-mode ultrasonography include an acoustically silent zone within the melanoma, choroidal excavation and acoustic shadowing of the orbit [21].

The treatment of choroidal melanoma includes local radiation with charged particles or episcleral plaque brachytherapy, tumour resection, enucleation and hyperthermia [22]. Transpapillary thermotherapy (TTT) is new treatment for small melanomas and is capable and causing necrosis of tumour up to 3.0 mm thickness [23]. Large melanomas (>10 mm in thickness or >1125 cm² in basal area) are usually managed with enucleation [24].

When malignant melanoma is encountered in the bone three possibilities are considered for its origin 1) skeletal metastasis 2) direct bony invasion 3) primary clear cell sarcoma. Out of these a skeletal metastasis of malignant

melanoma is most frequent cause. The other organs involved in case of metastasis are lungs, liver and brain [15]. Clear cell sarcoma, or malignant melanoma of soft parts can invade the bone along the course of attachments of tendons and ligaments; however, this pattern of direct invasion has been considered to be exceedingly rare [17,25]. Primary clear cell carcinoma arising from bone itself is also very rare. Direct bony invasion did not occur in this case since the lesions were 2 separate masses demonstrated on CT scan.

Malignant melanoma of bone has a variable and unpredictable course with high rate of recurrence after excision. Most authors recommend complete radical excision of the tumour along with excision of regional lymph nodes. Adjuvant chemotherapy and radiotherapy may be of benefit as well. Despite treatment, the overall prognosis is

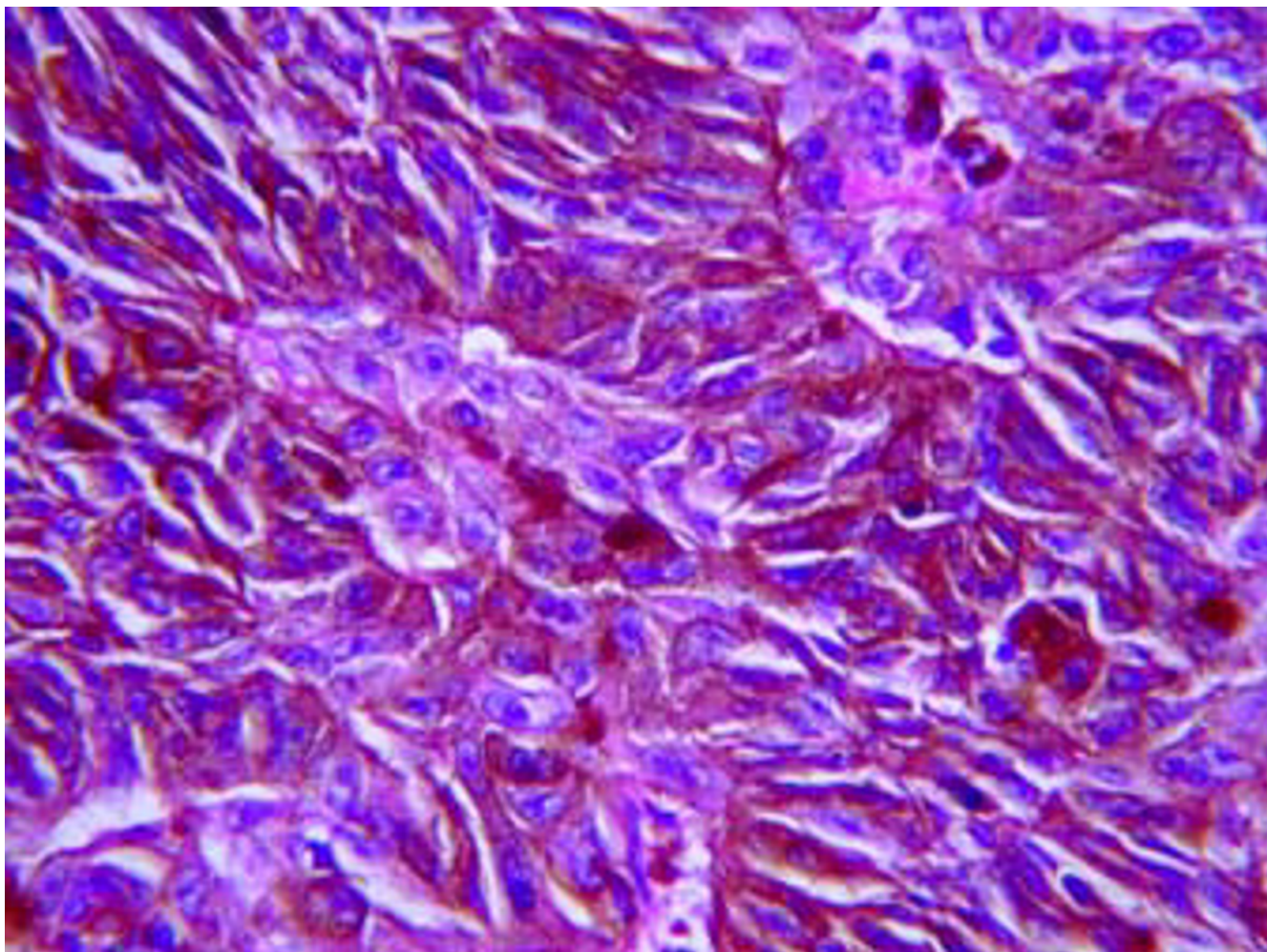


Figure 6

Photomicrograph showing tumor composed of sheets, nests and cords of polygonal cells and vesicular nuclei. Prominent nucleoli and eosinophilic cytoplasm containing abundant melanin pigment (Hematoxylin & Eosin original magnification $\times 40$).

poor and death usually access because of wide spread dissemination of disease [26].

Conclusion

Unlike cutaneous melanoma, malignant melanoma of the choroids does not metastasize to lymph nodes because they do not have lymphatic drainage however, they normally metastasize to liver, lungs or brain. Unusual metastasis poses a diagnostic and therapeutic challenge. The uniqueness of the case reported is its metastasis to maxillofacial bones (maxilla and zygoma) without involvement of lungs, liver or brain, which to our knowledge has not been documented earlier.

Competing interests

The author(s) declare that they have no competing interests.

Authors' contributions

MP: conceived the idea, participated in manuscript preparation and edited the final version

OP: wrote the draft manuscript and did the literature search

NN and AM: performed the pathology and prepared the photomicrograph

KR: performed the radiology and contributed to drafting the manuscript.

Acknowledgements

Written consent was obtained from the patient for publication of this case report.

References

- Albert DM, Jakobiel FA, Azar DT, Gragoudos ES, (Eds): *Principles of practice of ophthalmology* W.B. Saunders, New York; 1999.
- Avery RB, Mehta MP, Auchtung RM, Albert DM: **Intraocular melanoma.** In *Cancer Principles and practice of oncology* 7th edition. Edited by: DeVita VT Jr, Hellman S, Rosenberg SA. Lippincott Williams & Wilkins Publishers, Philadelphia; 2005.
- Inskip PD, Devesa SS, Fraumeni JF: **Trends in the incidence of ocular melanoma in the United States, 1974–1998.** *Cancer Causes Control* 2003, **14**:251-257.
- Bedikian AY, Legha SS, Mavligit G, Carrasco CH, Khorana S, Plager C, Papadopoulos N, Benjamin RS: **Treatment of uveal melanoma metastatic to the liver: a review of the M. D. Anderson Cancer Center experience and prognostic factors.** *Cancer* 1995, **76**:1665-1670.
- Tishler M, Greif J, Topilsky M: **Solitary pulmonary metastasis of choroidal malignant melanoma simulating primary lung cancer.** *Eur J Respir Dis* 1986, **68**:215-217.
- Gaudree L, Chabrun A, Corbi P, Levillain P, Herpin D: **Intracardiac metastasis of malignant melanoma. Literature review and case report.** *Arch Mal Coeur Vaiss* 2000, **93**:1339-1342.
- Ruiz RS, El-Harazi S, Albert DM, Bryar PJ: **Cardiac metastasis of choroidal melanoma.** *Arch Ophthalmol* 1999, **117**:1558-1559.
- Dithmar S, Diaz CE, Grossniklaus HE: **Intraocular melanoma spread to regional lymph nodes: report of two cases.** *Retina* 2000, **20**:76-79.
- Achtopoulos AK, Mitsos AP, Detorakis ET, Georgakoulis NV, Drakonaki EE, Kozobolis : **Plate isolated brain metastasis following enucleation for choroidal melanoma.** *Ophthalmic Surg Lasers Imaging* 2005, **36**:151-154.
- Vitri P, Caravati C, Guzzetti S, De Angelis S, Buzzi G, Gornati R: **Adrenal metastasis of choroidal melanoma: a case report.** *Ann Ital Chir* 1994, **65**:537-541.
- Santeusano G, Ventura L, Mauriello A, Carosi M, Spagnoli LG, Maturo P, Terranova L, Romanini C: **Isolated ovarian metastasis from a spindle cell malignant melanoma of the choroid 14 years after enucleation: prognostic implication of the keratin immunophenotype.** *Appl Immunohistochem Mol Morphol* 2000, **8**:329-333.
- Gherardi G, Scherini P, Ambrosi S: **Occult thyroid metastasis from untreated uveal melanoma.** *Arch Ophthalmol* 1985, **103**:689-691.
- Singh AD, Shields JA, Shields CL, Sato T: **Choroidal melanoma metastatic to the contralateral choroid.** *Am J Ophthalmol* 2001, **132**:941-943.
- Demirci H, Shields CL, Shields JA, Eagle RC Jr, Honavar SG: **Bilateral breast metastases from choroidal melanoma.** *Am J Ophthalmol* 2001, **131**:521-523.
- Inaoka T, Takahashi K, Tandai S, Miyokawa N, Abe Y, Matsuno T, Aburano T: **Primary clear cell sarcoma (malignant melanoma) in the right radius.** *Skeletal Radiol* 2003, **32**:594-597. Epub 2003 Aug 5
- Manolidis S, Donald PJ: **Malignant musocal melanoma of head and neck: review of the literature and report of 14 patients.** *Cancer* 1997, **80**:1373-1386.
- Cheny EB, Enzinger FM: **Malignant melanoma of soft parts a reassessment of clear cell sarcoma.** *Am J Surg Pathol* 1983, **7**:405-413.
- Garcia-Valenzuela E: **Melanoma Choroidal.** [<http://www.emedicine.com/oph/topic403.htm>]. [accessed October 30, 2005]
- Albert DM: **The ocular melanoma story III Edward Jackson Memorial lecture: part II.** *Am J Ophthalmol* 1997, **123**:729-734.
- Kelley MC, Jones RC, Gupta RK, Yee R, Stern S, Wanek L, Morton DL: **Tumor-associated antigen TA-90 immune complex assay predicts subclinical metastasis and survival for patients with early stage melanoma.** *Cancer* 1998, **83**:1355-1361.
- Char DH, Stone RD, Irvine AR, Crawford JB, Hilton GF, Lonn LI, Schwartz A: **Diagnostic modalities in choroidal melanoma.** *Am J Ophthalmol* 1980, **89**:223-230.
- Shields JA, Shields CL, Donors LA: **Management of post uveal melanoma.** *Ophthalmology* 1991, **36**:161-195.
- Godfrey DG, Waldron RG, Capone A: **Transpupillary thermotherapy for small choroidal melanoma.** *Am J Ophthalmology* 1999, **128**:88-93.
- Collaborative ocular melanoma study group: **The collaborative ocular melanoma study (COMS) randomized trial of pre-enucleated radiation of large choroidal melanoma: I. Characteristic of patients enrolled and not enrolled. COMS report No. 9.** *Am J Ophthalmol* 1998, **125**:767-778.
- Deenik W, Mooi WJ, Rutgers EJ, Peterse JL, Hart AA, Kroon BB: **Clear Cell sarcoma (Malignant melanoma) of soft parts. A clinico pathologic study of 30 cases.** *Cancer* 1999, **86**:969-975.
- Lucas DR, Nascimento AG, Sim FH: **Clear cell sarcoma of soft tissues: Mayo clinic experience with 35 cases.** *Am J Surgical Pathol* 1992, **16**:1197-1204.

Publish with **BioMed Central** and every scientist can read your work free of charge

"BioMed Central will be the most significant development for disseminating the results of biomedical research in our lifetime."

Sir Paul Nurse, Cancer Research UK

Your research papers will be:

- available free of charge to the entire biomedical community
- peer reviewed and published immediately upon acceptance
- cited in PubMed and archived on PubMed Central
- yours — you keep the copyright

Submit your manuscript here:
http://www.biomedcentral.com/info/publishing_adv.asp

