

# Surgical Hip Dislocation Is a Reliable Approach for Treatment of Femoral Head Fractures

Alessandro Massè MD, Alessandro Aprato MD, Caterina Alluto MD,  
Marco Favuto MD, Reinhold Ganz MD

Published online: 21 May 2015

© The Association of Bone and Joint Surgeons® 2015

## Abstract

**Background** Femoral head fractures are rare injuries; incongruity and instability are indications for surgical intervention. Anterior, posterior, and transtrochanteric surgical approaches have been proposed, but the exposure is limited with classical approaches. Surgical hip dislocation allows for a 360° view of the head and may facilitate a reduction in selected head fractures, but to our knowledge, few studies have reported on the results with this technique.

---

Each author certifies that he or she, or a member of his or her immediate family, has no funding or commercial associations (eg, consultancies, stock ownership, equity interest, patent/licensing arrangements, etc) that might pose a conflict of interest in connection with the submitted article.

All ICMJE Conflict of Interest Forms for authors and *Clinical Orthopaedics and Related Research*® editors and board members are on file with the publication and can be viewed on request.

Each author certifies that his or her institution approved the human protocol for this investigation, that all investigations were conducted in conformity with ethical principles of research, and that informed consent for participation in the study was obtained.

This study was performed in the Orthopaedic Department, San Luigi Hospital of Orbassano, University of Turin, Turin, Italy.

---

**Electronic supplementary material** The online version of this article (doi:10.1007/s11999-015-4352-4) contains supplementary material, which is available to authorized users.

---

A. Massè, A. Aprato (✉), C. Alluto, M. Favuto  
Orthopaedic Department, University of Turin,  
Viale 25 aprile 137 int 6, 10133 Turin, Italy  
e-mail: ale\_aprato@hotmail.com

A. Massè, A. Aprato, C. Alluto, M. Favuto  
San Luigi Hospital of Orbassano, Turin, Italy

R. Ganz  
Department of Orthopaedic Surgery, University of Berne,  
Berne, Switzerland

We therefore report on the (1) quality of fracture reduction; (2) modified Harris hip score at a minimum of 2 years (mean, 6 years, range, 26–122 months); and (3) frequency of complications, including avascular necrosis (AVN), arthritis development, and heterotopic ossification, in a case series of patients with femoral head fractures treated with this approach.

**Description of Technique** The procedure involves digastric trochanteric flip osteotomy and safe dislocation of the femoral head, preserving its vessels. Using this technique we are able to reduce all displaced femoral head fractures under direct view. Definitive fixation is performed through this approach with 2.7-mm nonabsorbable screws. The same technique may be used also for Pipkin IV fractures to fix transverse, T-type, posterior wall, or posterior column acetabular fracture.

**Methods** Between 2004 and 2011, we used this approach to manage all displaced femoral head fractures in patients younger than 55 years old. A total of 17 patients were thus treated; of those three were lost to followup before 2 years, and one was excluded from study because of severe preoperative neurological impairment, leaving 13 for analysis here. Patient demographic, injury, and surgical variables as well as complications were recorded and retrospectively evaluated. Radiographic outcome was scored according to Matta's criteria on postoperative radiographs. Outcomes were evaluated with the modified Harris hip score. Minimum followup was 24 months (mean, 77 months; SD, 32.8 months).

**Results** Fracture reduction was anatomic in eight hips and imperfect in five. Mean clinical score was 82 points (SD, 7.7). One patient developed symptomatic femoral head AVN and underwent total hip arthroplasty 4 years after the index procedure; no other patient underwent arthroplasty. Besides this patient, signs of arthritis (Grade I according to

Tönnis classification) were found in one patient and heterotopic ossification was recorded in two patients, but neither was symptomatic.

**Conclusions** Our experience with surgical dislocation shows clinical results comparable to previously reported outcomes in femoral head fractures treated with common approaches; we also present a similar rate of AVN and a lower rate of posttraumatic arthritis, but a higher risk of heterotopic ossification. Further case-control studies are necessary to confirm these statements.

**Level of Evidence** Level IV, therapeutic study.

## Introduction

Femoral head fractures are rare injuries [1, 9] and, in the absence of randomized controlled data, absolute recommendations for definitive management are difficult to make. Areas of controversy include choice of surgical procedure (which femoral head fragments should be fixed and what influence does an associated acetabular fracture have on this decision) and choice of surgical approach.

There is a general consensus, however, that the majority of these injuries should be treated operatively. Choice of surgical intervention and reconstructive options are influenced by patient and fracture considerations. Patient factors include physiological age, level of activity, bone quality, and associated comorbidities [9]. Regarding fracture patterns, it is generally accepted that Pipkin II, III, and IV fractures should be managed by open reduction and internal fixation in young, active patients [1], whereas treatment of Pipkin I fractures is surgery when the femoral head fragment is displaced [23, 24]. Anterior, posterior, and transtrochanteric surgical approaches have been proposed but the exposure is limited with classical approaches. Few studies have reported on the results using approaches that provide full exposure of the femoral head but spare the blood supply to the femoral head.

We therefore report our experience with the use of surgical hip dislocation for treatment of displaced femoral head fractures. In addition to a description of the surgical technique, we report on the (1) quality of fracture reduction; (2) modified Harris hip score at a minimum of 2 years (mean, 77 months; SD, 32.8 months); and (3) frequency of complications, including avascular necrosis, arthritis development, and heterotopic ossification.

## Surgical Technique

A Kocher-Langenbeck approach was used for Type IV fractures to provide better exposure of the concomitant acetabular fracture; however, for Type I and II fractures,

the Gibson approach was used to preserve more of the gluteus maximus muscle.

In all patients, we performed a trochanteric osteotomy with the osteotomized fragment maintaining the insertion of the gluteus medius, vastus lateralis, and long tendon of the gluteus minimus muscles. To ensure that the major part of the piriformis tendon remains on the stable part of the greater trochanter, we initially kept a small part of the most posterior portion of the gluteus medius tendon attached to the trochanter and sharply cut it after osteotomy. We then dissected the superior border of the piriformis tendon near the trochanteric insertion and isolated the interval between the gluteus minimus and the piriformis muscles. This interval is safe regarding the risk of damage to the deep branch of the medial circumflex artery.

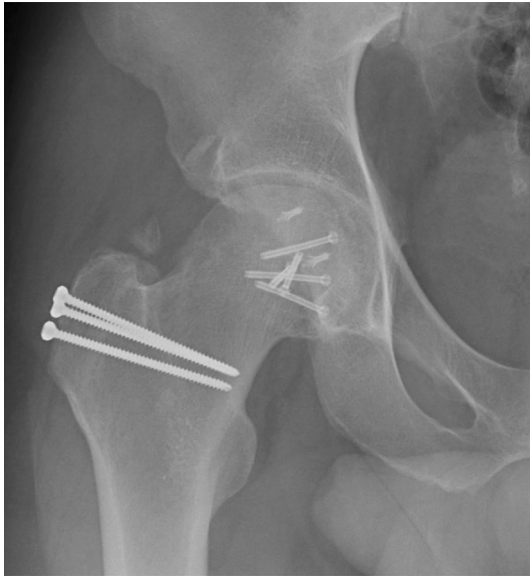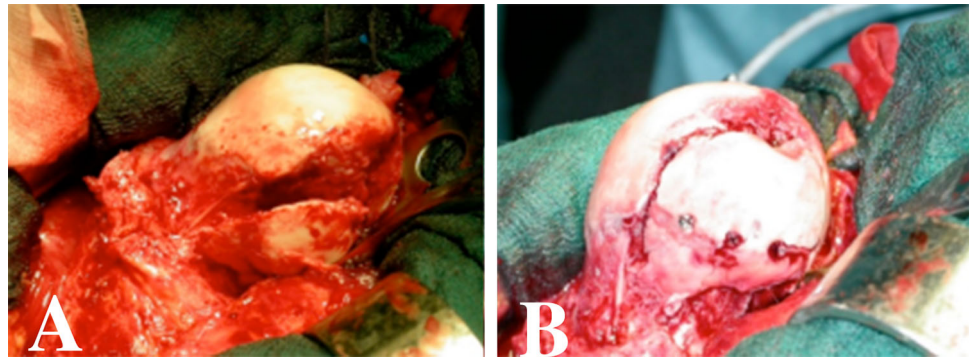
We flipped the osteotomized trochanteric fragment and slid it anteriorly after releasing the origin of the gluteus minimus. Débridement of the gluteus minimus may also be performed at the time of anterior displacement of the fragment because gluteus minimus injuries are very common in acetabular fractures. We performed a Z-shaped anterosuperior capsulotomy when the capsule was intact or completed it if there was a partial capsular rupture. We then dislocated the femoral head and inspected the acetabulum. We recommend caution at the time of dislocation: in Type III fracture, femoral neck fixation should be temporarily performed with two Kirschner wires before head dislocation; in Type I fracture, the inferior fragment may still be attached to the ligamentum teres and/or still connected to the inferior retinaculum. Avoiding iatrogenic lesion to the inferior retinaculum is mandatory to reduce the risk of avascular necrosis (AVN) and section of the ligamentum teres should be carefully performed with curved scissors.

In cases of Type IV fractures, we relocated the femoral head, débrided muscle tissue, and exposed the posterior wall and column. After elevation of the impacted fragments, we performed a direct reduction maneuver based on the fracture type (Video 1 [Supplemental materials are available with the online version of CORR<sup>®</sup>]). For a transverse fracture/transverse plus posterior wall fracture, fracture reduction can be achieved with several techniques as previously described [15, 20].

To treat the femoral head fracture, we placed 2.7-mm nonabsorbable screws under direct vision (Fig. 1) with specific attention to avoidance of weightbearing zones and screw protrusion. We then reduced the femoral head within the acetabulum and fixed the trochanteric fragment with two or three screws [20] (Fig. 2).

Patients were instructed to avoid active hip abduction and passive hip adduction for 1 month and to avoid weightbearing on the affected side for 3 months. All patients received heterotopic ossification prophylaxis with 25 mg indomethacin three times a day for 30 days.

**Fig. 1A–B** Intraoperative views of Pipkin Type II fracture before (A) and after (B) reduction and fixation with screws are shown.



**Fig. 2** Postoperative radiographic view of trochanteric fixation with screws is shown.

### Patients and Methods

Between 2004 and 2011, we used this approach selectively to manage displaced femoral head fractures. During the period in question, of 20 patients who presented with femoral head fractures, we surgically treated 17 patients younger than 55 years old using this approach (Table 1) because three patients were older and have been treated with THA. We included all displaced Type II, III, and IV fractures according to the Pipkin classification [19] and Type I fractures if displaced by more than 3 mm (evaluated on CT scan). One patient was lost to followup, and one was excluded from this study for severe preoperative neurologic impairment. Two patients were excluded because of followup of less than 2 years, leaving a total of 13 patients as the study population.

All patients underwent a preoperative CT scan and all fractures were treated by a single surgeon (AM). Patient age at surgery, sex, side of injury, operative time, and postoperative complications were recorded in a custom-

made database. Patients were asked to give their informed consent to the use of an unconventional approach when eligible according to the selection criteria. The study was approved by the local ethical committee.

Minimum followup was 24 months (mean, 77 months; SD, 32.8 months). Thus, we had five Pipkin I, two Pipkin II, and six Pipkin IV fractures.

The surgeon involved had experience with this approach for other indications, including 40 hips with femoroacetabular impingement, 21 with slipped capital epiphysis [14], and 43 with isolated acetabular fractures [15]. Concomitant acetabular fixation was performed in Type IV fractures. The mean surgical time was 121 minutes (SD, 35) for Type I or II fractures and 195 minutes (SD, 42) for Type IV fractures including anesthetic time; the mean incision to suture time was 95 minutes (SD, 54) for Type I or II and 156 minutes (SD, 39) for Type IV fractures. Mean estimated blood loss were 1334 mL (SD, 623) in the isolated femoral head fractures and 1557 mL (SD, 748) in head and acetabulum fractures. Two patients received homologous blood in the operating room.

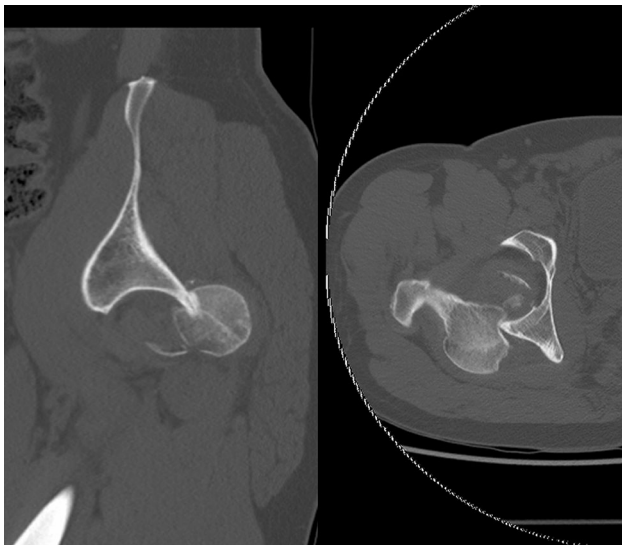
Surgical reports were reviewed to describe integrity of the Weitbrecht ligament and the presence of cartilage damage, multiple fragments, and/or labral tear. Intraoperative lack of congruence was also recorded. All Pipkin Type I and Type II fractures presented an intact Weitbrecht ligamentum; in Type IV fractures, four of six patients presented an intact ligamentum. A labral tear was found in four patients. Multiple fragments with limited dimensions were found in eight hips. Intraoperatively, we found an anterior impaction of the head in nine patients (Fig. 3) and bone loss (defined as a partial incongruence between femoral head fragments) was intraoperatively reported in 10 hips (Fig. 4).

The reduction of the fracture was evaluated according to Matta's criteria [16] by measuring the residual postoperative displacements on the two plain radiographs (AP and lateral views). For each of these radiographs, the maximum displacement seen at any of the normal radiographic lines of the acetabulum or the femoral head was recorded in millimeters, and the highest of the three values was used to

**Table 1.** Population data

Patient	Sex	Age (years)	Fracture type	Followup (months)
1	M	23	Pipkin I	122
2	M	22	Pipkin I	118
3	M	31	Pipkin IV + transverse fracture	115
4	M	25	Pipkin IV + transverse and posterior wall fracture	108
5	M	24	Pipkin I	95
6	F	22	Pipkin II	95
7	M	35	Pipkin IV + posterior wall fracture	77
8	M	47	Pipkin IV + posterior wall fracture	75
9	M	32	Pipkin IV + posterior wall fracture	47
10	M	38	Pipkin IV + posterior wall fracture	46
11	F	47	Pipkin I	41
12	M	54	Pipkin I	39
13	M	42	Pipkin II	26

M = male; F = female.

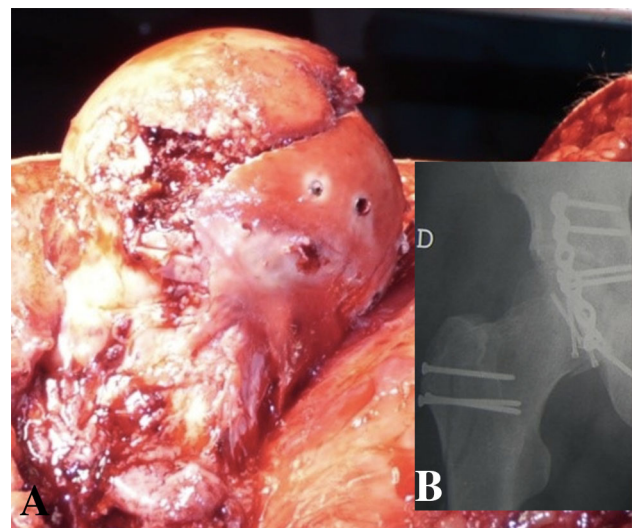


**Fig. 3** CT scan slice shows the Hill-Sachs-like osteochondral lesion.

grade the reduction according to one of three categories: anatomical (0–1 mm of displacement), imperfect (2–3 mm), or poor (more than 3 mm).

Patients were retrospectively reviewed for the purpose of this study and outcome was evaluated with the modified Harris hip score by an orthopaedic surgeon independent from the pelvic team and blinded to surgical findings (CA) [10, 18].

The presence of heterotopic ossification was recorded and graded according to the Brooker classification [3]. Radiographs taken at the last followup were evaluated and classified according to the Tönnis classification [26].



**Fig. 4A–B** Intraoperative view (A) shows a partial incongruent reduction and its postoperative radiographic appearance (B).

## Results

Fracture reduction was radiographically defined as anatomic in eight hips and imperfect in five. The mean residual fracture displacement was 1.3 mm (SD, 1.15).

The mean clinical score was 82 points (SD, 8). Excellent results (defined as a modified Harris hip score higher than 80 points) were achieved in 11 of the 13 patients; one fair and one poor result occurred in the other two patients. One patient developed symptomatic AVN of the femoral head and underwent THA at 4 years. Besides this patient, no other patient underwent arthroplasty.

Heterotopic ossification was recorded in two patients, classified as Stage II and III according to the Brooker classification. Neither of these patients reported symptoms from the heterotopic ossification. No case of infection occurred.

On the radiographs taken at the last followup, signs of arthritis (Grade I according to the Tönnis classification) were found in one patient; the patient who underwent arthroplasty was classified as Grade 3, whereas all other patients were classified as Grade 0.

## Discussion

Femoral head fractures are rare injuries, but the general consensus is that operative fixation is warranted. However, controversy exists about the choice of surgical approach for femoral head fractures. Anterolateral (Watson-Jones), anterior (Smith-Petersen), and posterolateral (Kocher-Langenbeck) approaches are the most used in the literature [9]. The exposure is limited with classical approaches. Few studies have reported on the results using approaches such as surgical dislocation that provide full exposure of the femoral head but spare the blood supply to the femoral head [7, 11, 17, 22]. We therefore report our experience with the use of surgical hip dislocation for treatment of displaced femoral head fractures. In addition to a description of surgical technique, we report on the (1) quality of fracture reduction; (2) modified Harris hip score at a minimum of 2 years (mean, 6 years, range, 26–122 months); and (3) frequency of complications, including AVN, arthritis development, and heterotopic ossification.

This study had a number of limitations. First, this study comprised a single center and was single surgeon-based. Thus, there is concern about the reproducibility of this technique; the surgeon who performed all surgeries has been trained to perform the technique and has experience either in acetabular and femoral head fracture treatment through standard approaches or nontraumatic hip disease treatment through surgical dislocation. Our results may not be reproduced by centers without high volumes of acetabular fractures and/or with less experience in this technique for nontraumatic diseases. Other limitations are the small number of enrolled patients and the absence of a control group. There is a possibility for selection bias, but our criteria for inclusion were not markedly different from those in previous studies. Furthermore, one patient has been lost to followup and even a single patient could negatively influence the rate of complications. We used the modified Harris hip score, which has been criticized in the literature for its ceiling effect [2, 27]. Other scoring instruments such as the WOMAC or Hip disability and Osteoarthritis Outcome Score may be more applicable in

these patients. However, we chose the Harris hip score here because it is used extensively worldwide, is familiar, and because no clinical score has been validated for femoral head fracture fixation. Because a specific tool to evaluate the reduction of femoral head fractures has not been described in the orthopaedic literature, we used the Matta classification. This instrument has been described to evaluate acetabular fracture and shows a good correlation with posttraumatic arthritis development [13] but has not been validated for femoral head fractures and may not correlate with posttraumatic arthritis. AVN could also be present in more patients, who were not identified because postoperative MRI was not always performed. Finally, our technique itself also has some limitations, and these deserve comment. Importantly, surgical dislocation presents the risk of detachment of the inferior fragment from the inferior vessels. Another major limitation of this approach may be the lateral decubitus position in femoral head fracture associated with transverse acetabular fracture: Collinge et al. [5] demonstrated a trend toward higher radiographic residual fracture displacement in patients with transversely oriented acetabular fractures reduced and stabilized through the Kocher-Langenbeck approach in the lateral position compared with those positioned prone.

We achieved an anatomic reduction in eight of 13 patients; unfortunately, previous studies with the same technique did score the reduction but performed the radiographic evaluation inside the Thompson-Epstein score [25]. Radiographic criteria of this classification are not based on the reduction performance but mostly on the arthritic features of the hip.

Furthermore, these studies did not specifically mention associated traumatic osteochondral lesions; we found a high proportion of those injuries, which were not readily detectable on standard radiographs. For example, a Hill-Sachs-like lesion is commonly reported in femoral head fractures [12] and often is not visible on plain radiographs [4]. This may explain the lack of correlation between unsatisfying intraoperative findings and apparently excellent reductions noted on early radiographs. The amount of residual fracture displacement may not correlate with clinical outcomes, although every effort should be made to obtain the best possible reduction. Further study should focus on assessing the role of residual osteochondral incongruity on arthritis development in the long term.

Because of the rarity of femoral head fractures, few series are available in the literature for direct comparison (Table 2). In addition, clinical outcomes are reported with a variety of scoring instruments. Henle et al. [11] reported on 12 patients using the Merle d'Aubigne and Postel score. At 31.1 months, 10 patients had good outcomes and two were considered poor. Similarly, at 47 months, Solberg et al. [22] reported on 12 patients with Pipkin IV fractures

**Table 2.** Comparison of published clinical results

Study	Number of patients	Type of fracture (Pipkin)	Followup (months)	Outcome (Merle d'Aubigne and Postel)	Outcome (Thompson and Epstein)	Outcome (modified Harris hip score)	HO	AVN	
Henle et al. [11]	12	1 Type I	31	10 good or excellent	10 good or excellent	-	5	2	
		3 Type II		2 poor	2 poor				
		8 Type IV							
Solberg et al. [22]	12	12 Type IV	47	10 good or excellent 1 fair	10 good or excellent 1 fair	-	4	1	
				1 poor	1 poor				
Mostafa et al. [17]	11 Kocher-Langenbeck approach (group A) 12 surgical hip dislocation (group B)	5 Type I	31	9 good or excellent; 2 poor (Group A)	8 good or excellent; 1 fair; 2 poor (Group A)	-	2	Group A Group A	
		18 Type II		10 good or excellent; 1 fair; 1 poor (Group B)	10 good or excellent; 1 fair; 1 poor (Group B)	1			4
						Group B Group B			
Present study	13	5 Type I	75	-	-	11 excellent; 1 fair; 1 poor	2	1	
		2 Type II							
		6 Type IV							

HO = heterotopic ossification; AVN = avascular necrosis of the femoral head.

and noted good or excellent scores in 10. Results reported in these studies are comparable to ours suggesting that good outcomes are similar at 3 [11], 4 [22], and 6 years (present study). In a systematic review of 26 papers reporting on 405 femoral head fractures, Giannoudis et al. [8] reported that clinical outcomes, defined as good or excellent results according to Thompson-Epstein criteria [25], were better with a lateral approach than with either an anterior or posterior approach with 11% of patients undergoing fixation through a variety of lateral approaches obtaining a poor or bad result compared with 35% and 51%, respectively. These outcomes were reported at 55.6 months but are difficult to compare with our results because this review grouped together the lateral approach with and without surgical dislocation.

The rarity of femoral head fractures also provides obstacles to long-term followup, because the majority of cases are treated as isolated instances. Complications of note include AVN, progression to arthritis, and heterotopic ossification. The rate of AVN in our series was 7.7% and this is consistent with the reported literature: in their systematic review, Giannoudis et al. [8] calculated an AVN rate of 11.8% (48 of 405) at a mean followup of 59.7 months. Although our rate is lower, our followup was shorter. In our study, only one patient showed signs of arthritis (Tönnis Grade I) at 77 months of followup, which is in line with Giannoudis et al.'s review [8], in which posttraumatic arthritis showed a 20- and 30-times higher incidence when an anterior or posterior approach was used, respectively, versus a trochanteric flip osteotomy. In our case series no infection occurred, although the latter has been described as the most common complication (rate 3.2%) in surgically treated femoral head fractures. In the Giannoudis et al. review [8], the heterotopic ossification (including all Brooker grades) rate was 16.8% (68 of 405), but with the numbers available, no difference could be seen between surgical approaches. Our results confirm the heterotopic ossification rate is high with surgical dislocation (15.3%) and suggest that heterotopic ossification should be always considered when this technique is used.

In this study, the lateral and posterolateral approaches with trochanteric flip osteotomy allowed 360° exposure and repair of both lesions in Pipkin IV fractures [7, 11, 17, 22]. This approach has been previously used to treat a variety of nontraumatic hip pathologies [6, 21] and for selected types of acetabular fractures [15]. We recommend consideration of this technique for surgeons treating a high volume of acetabular fractures because the full exposure of the femoral head and the subsequent advantages in the reduction may be useful for challenging cases such as Pipkin III and IV fractures. On the other hand, future studies are required to compare this approach with others in terms of outcome scores and complications with a higher

level of evidence. Those studies should define if this technique should be used only for difficult cases or if it should be used as routine for displaced fractures of the femoral head.

## References

- Alonso JE, Volgas DA, Giordano V, Stannard JP. A review of the treatment of hip dislocations associated with acetabular fractures. *Clin Orthop Relat Res.* 2000;377:32–43.
- Aprato A, Jayasekera N, Villar RN. Does the modified Harris hip score reflect patient satisfaction after hip arthroscopy? *Am J Sports Med.* 2012;40:2557–2560.
- Brooker A, Bowerman J, Robinson R, Riley LH. Ectopic ossification following total hip replacement: incidence and a method of classification. *J Bone Joint Surg Am.* 1955;55:1629–1632.
- Brooks RA, Ribbans WJ. Diagnosis and imaging studies of traumatic hip dislocations in the adult. *Clin Orthop Relat Res.* 2000;377:15–23.
- Collinge C, Archdeacon M, Sagi HC. Quality of radiographic reduction and perioperative complications for transverse acetabular fractures treated by the Kocher-Langenbeck approach: prone versus lateral position. *J Orthop Trauma.* 2011;25:538–542.
- Ganz R, Gill TJ, Gautier E, Ganz K, Krugel N, Berlemann U. Surgical dislocation of the adult hip a technique with full access to the femoral head and acetabulum without the risk of avascular necrosis. *J Bone Joint Surg Br.* 2001;83:1119–1124.
- Gardner MJ, Suk M, Pearle A, Buly RL, Helfet DL, Lorich DG. Surgical dislocation of the hip for fractures of the femoral head. *J Orthop Trauma.* 2005;19:334–342.
- Giannoudis PV, Kontakis G, Christoforakis Z, Akula M, Tosounidis T, Koutras C. Management, complications and clinical results of femoral head fractures. *Injury.* 2009;40:1245–1251.
- Gillespie P, Aprato A, Bircher M. Hip dislocation and femoral head fractures. In: Bentley G, ed. *European Surgical Orthopaedics and Traumatology: the Efort Textbook.* Berlin, Heidelberg, Germany: Springer; 2014:2179–2202.
- Harris WH. Traumatic arthritis of the hip after dislocation and acetabular fractures: treatment by mold arthroplasty. An end-result study using a new method of result evaluation. *J Bone Joint Surg Am.* 1969;51:737–755.
- Henle P, Kloen P, Siebenrock KA. Femoral head injuries: which treatment strategy can be recommended? *Injury Int J Care Injured.* 2007;38:478–488.
- Laorr A, Greenspan A, Anderson MW, Moehring HD, McKinley T. Traumatic hip dislocation: early MRI findings. *Skeletal Radiol.* 1995;24:239–245.
- Lichte P, Sellei RM, Kobbe P, Dombroski DG, Gänsslen A, Pape HC. Predictors of poor outcome after both column acetabular fractures: a 30-year retrospective cohort study. *Patient Saf Surg.* 2013 Mar 19 [Epub ahead of print].
- Massè A, Aprato A, Grappiolo G, Turchetto L, Campacci A, Ganz R. Surgical hip dislocation for anatomic reorientation of slipped capital femoral epiphysis: preliminary results. *Hip Int.* 2012;22:137–144.
- Massè A, Aprato A, Rollero L, Bersano A, Ganz R. Surgical dislocation technique for the treatment of acetabular fractures. *Clin Orthop Relat Res.* 2013;471:4056–4064.
- Matta JM. Fractures of the acetabulum: accuracy of reduction and clinical results in patients managed operatively within three weeks after the injury. *J Bone Joint Surg Am.* 1996;78:1632–1645.

17. Mostafa MF, El-Adl W, El-Sayed MA. Operative treatment of displaced Pipkin type I and II femoral head fractures. *Arch Orthop Trauma Surg.* 2014;134:637–644.
18. Ovre S, Sandvik L, Madsen JE, Roise O. Modification of the Harris hip score in acetabular fracture treatment. *Injury.* 2007;38:344–349.
19. Pipkin G. Treatment of Grade IV fracture-dislocation of the hip. A review. *J Bone Joint Surg Am.* 1957;39:1027–1197.
20. Siebenrock KA, Gautier E, Woo AK, Ganz R. Surgical dislocation of the femoral head for joint débridement and accurate reduction of fractures of the acetabulum. *J Orthop Trauma.* 2002;16:543–552.
21. Sink EL, Beaulé PE, Sucato D, Kim YJ, Millis MB, Dayton M, Trousdale RT, Sierra RJ, Zaltz I, Schoenecker P, Monreal A, Clohisy J. Multicentre study of complications following surgical dislocation of the hip. *J Bone Joint Surg Am.* 2011;93:1132–1136.
22. Solberg BD, Moon CN, Franco DP. Use of a trochanteric flip osteotomy improves outcomes in Pipkin IV fractures. *Clin Orthop Relat Res.* 2009;467:929–933.
23. Stannard JP, Harris HW, Volgas DA, Alonso JE. Functional outcome of patients with femoral head fractures associated with hip dislocations. *Clin Orthop Relat Res.* 2000;377:44–56.
24. Swiontkowski MF, Thorpe M, Seiler JG, Hansen ST. Operative management of displaced femoral head fractures: case matched comparison of anterior versus posterior approaches for Pipkin I and Pipkin II fractures. *J Orthop Trauma.* 1992;6:437–442.
25. Thompson VP, Epstein HC. Traumatic dislocation of the hip; a survey of two hundred and four cases covering a period of twenty-one years. *J Bone Joint Surg Am.* 1951;33:746–748.
26. Tönnis D. Normal values of the hip joint for the evaluation of X-rays in children and adults. *Clin Orthop Relat Res.* 1976;119:39–47.
27. Wamper KE, Sierevelt IN, Poolman RW, Bhandari M, Haverkamp D. The Harris hip score: do ceiling effects limit its usefulness in orthopedics? *Acta Orthop.* 2010;81:703–707.