



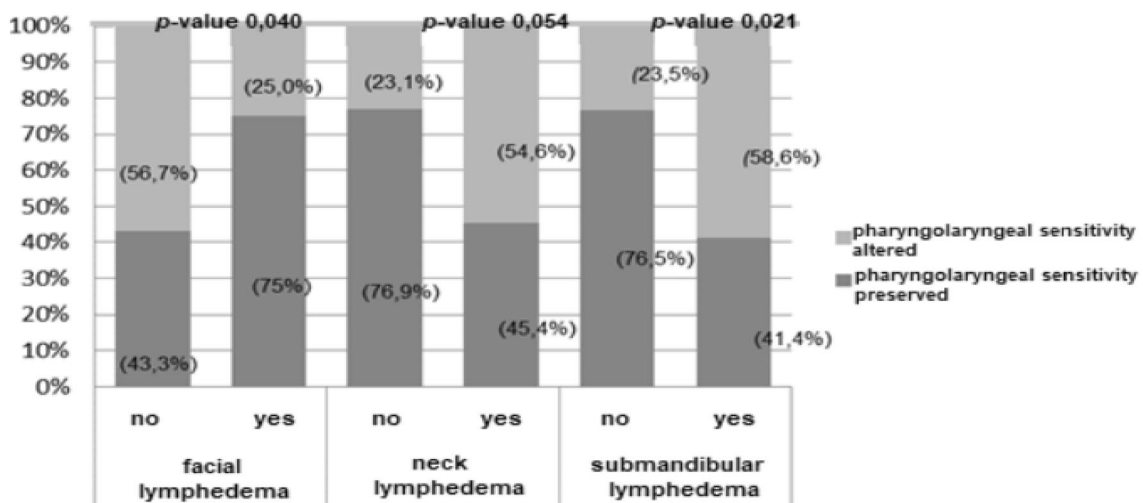
Correction to: Cervicofacial and Pharyngolaryngeal Lymphedema and Deglutition After Head and Neck Cancer Treatment

Débora dos Santos Queija¹ · Rogério Aparecido Deditis² · Lica Arakawa-Sugueno¹ · Mario Augusto Ferrari de Castro³ · Bruna Mello Chamma⁴ · Marco Aurélio Vamondes Kulcsar^{2,5} · Leandro Luongo de Matos²

Published online: 10 October 2019
© Springer Science+Business Media, LLC, part of Springer Nature 2019

Correction to: Dysphagia
<https://doi.org/10.1007/s00455-019-10053-6>

The original version of this article unfortunately contained a mistake. Figure 2 was repeated in Fig. 3.
The corrected Fig. 3 is placed below.



Legend: p- value obtained by the Chi-square test, * p-value obtained by Fisher's exact test.

Fig. 3 Association between pharyngolaryngeal sensitivity and external lymphedema. *p* value obtained by the χ^2 test, **p* value obtained by Fisher's exact test

The original article can be found online at <https://doi.org/10.1007/s00455-019-10053-6>.

✉ Débora dos Santos Queija
dqueija@uol.com.br

¹ São Paulo Medical School, University of São Paulo, São Paulo, SP, Brazil

² Department of Head and Neck Surgery, São Paulo Medical School, University of São Paulo, São Paulo, SP, Brazil

³ Medical School, University Metropolitana of Santos, Santos, SP, Brazil

⁴ Mogi das Cruzes University, Mogi das Cruzes, SP, Brazil

⁵ São Paulo State Cancer Institute, São Paulo, SP, Brazil

Publisher's Note Springer Nature remains neutral with regard to jurisdictional claims in published maps and institutional affiliations.

Débora dos Santos Queija SLP, PhD

Rogério Aparecido Deditis MD, PhD

Lica Arakawa-Sugueno SLP, PhD

Mario Augusto Ferrari de Castro MD, PhD

Bruna Mello Chamma Pt

Marco Aurélio Vamondes Kulcsar MD, PhD

Leandro Luongo de Matos MD, PhD