



Correction to: COVID-19 and eosinophilic granulomatosis with polyangiitis or COVID-19 mimicking eosinophilic granulomatosis with polyangiitis?

Bahar Özdemir¹ · Abdulsamet Erden¹ · Serdar Can Güven¹ · Berkan Armagan¹ · Hakan Apaydin¹ · Özlem Karakas¹ · Ahmet Gokhan Akdag² · İhsan Ates³ · Orhan Kucuksahin⁴ · Ahmet Omma¹

Published online: 22 July 2021
© Springer-Verlag GmbH Germany, part of Springer Nature 2021

Correction to:
Rheumatology International (2021) 41:1515–1521
<https://doi.org/10.1007/s00296-021-04896-2>

In the first box of figure 1, we used the Turkish word "veya" instead of its English equivalent "or" twice by mistake. The

correction Fig. 1 is as given below:

The original article has been corrected.

The original article can be found online at <https://doi.org/10.1007/s00296-021-04896-2>.

✉ Bahar Özdemir
bharozdemir@gmail.com

Abdulsamet Erden
drsameterden@gmail.com

Serdar Can Güven
drserdarguven@gmail.com

Berkan Armagan
berkanarmagan@gmail.com

Hakan Apaydin
drhakanapaydin@gmail.com

Özlem Karakas
ozlem01us@yahoo.com

Ahmet Gokhan Akdag
agokhanakdag@gmail.com

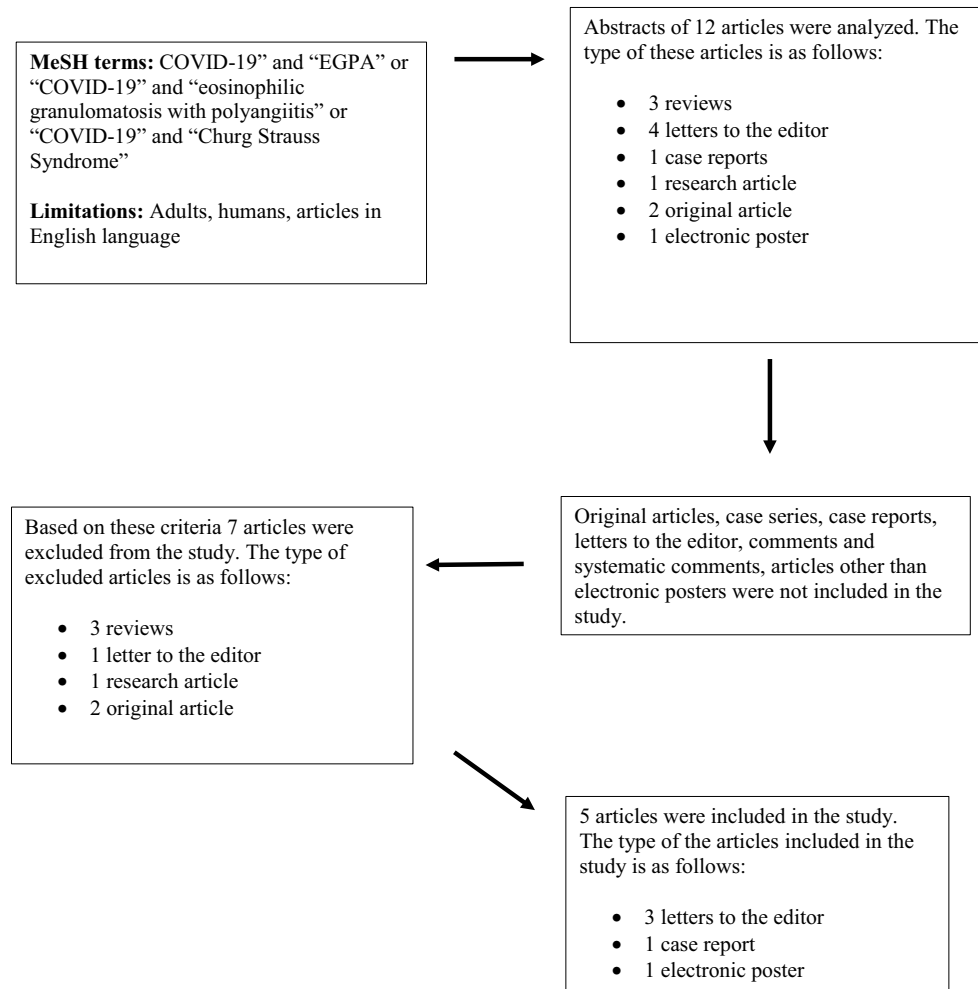
İhsan Ates
dr.ihsanates@hotmail.com

Orhan Kucuksahin
orhankcs@gmail.com

Ahmet Omma
ahmetomma@gmail.com

- ¹ Division of Rheumatology, Department of Internal Medicine, Ankara City Hospital, Ankara 06100, Turkey
- ² Division of Intensive Care, Department of Internal Medicine, Ankara City Hospital, Ankara, Turkey
- ³ Department of Internal Medicine, Ankara City Hospital, Ankara, Turkey
- ⁴ Division of Rheumatology, Department of Internal Medicine, Ankara City Hospital, Yıldırım Beyazıt University, Ankara, Turkey

Fig. 1 Flow chart demonstrating the article evaluation process for recruitment



Publisher’s Note Springer Nature remains neutral with regard to jurisdictional claims in published maps and institutional affiliations.