



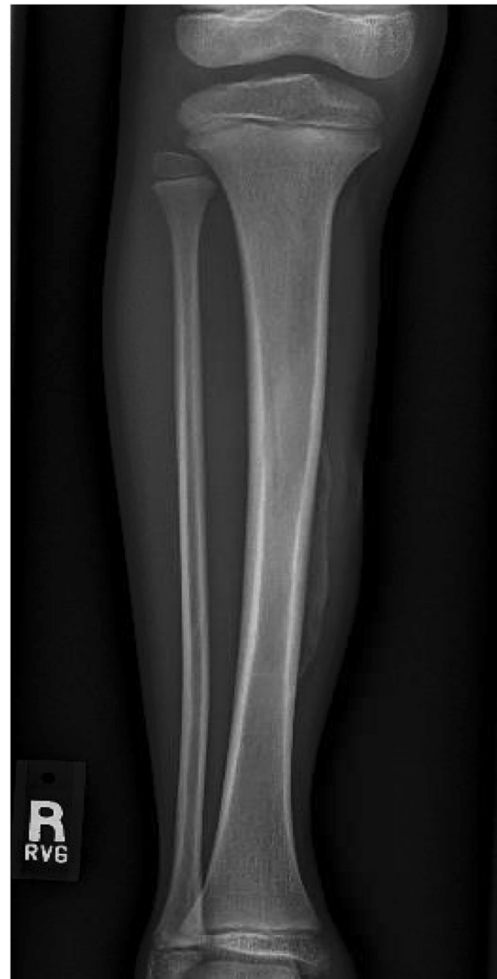Test Yourself: Question: “Painless right leg swelling”

K. Aaron Shaw^{1,2} · Joshua S. Murphy^{1,2} · Kelley W. Marshall^{1,2}

Published online: 25 January 2019
© ISS 2019

Brief history

8-year-old male with diagnosis of neurofibromatosis type 1, presents with 1-week history of atraumatic, painless, right leg swelling to anteromedial aspect of tibia (Figs. 1, 2, 3 and 4).



The diagnosis can be found at <https://doi.org/10.1007/s00256-019-3147-1>

✉ K. Aaron Shaw
kenneth.a.shaw34.mil@mail.mil

¹ Dwight D. Eisenhower Army Medical Center, Department of Orthopaedic Surgery, 300 East Hospital Road, Fort Gordon, GA 30905, USA

² Children’s Healthcare of Atlanta, Scottish Rite Campus, Atlanta, GA, USA

Fig. 1 Anteroposterior plain radiograph of right leg

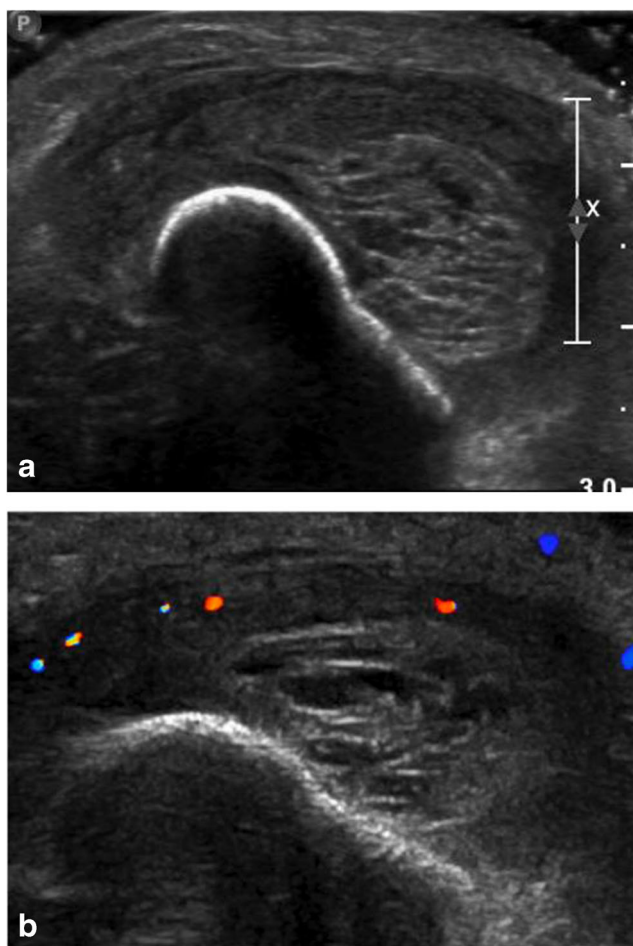


Fig. 2 Axial (a) grayscale and (b) color Doppler ultrasound images of the right leg centered over the area of maximal swelling

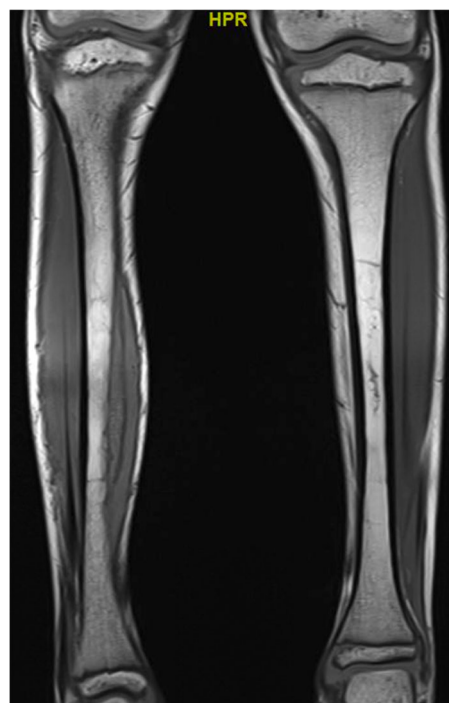


Fig. 3 T1 weighted, coronal MRI image without contrast of bilateral legs

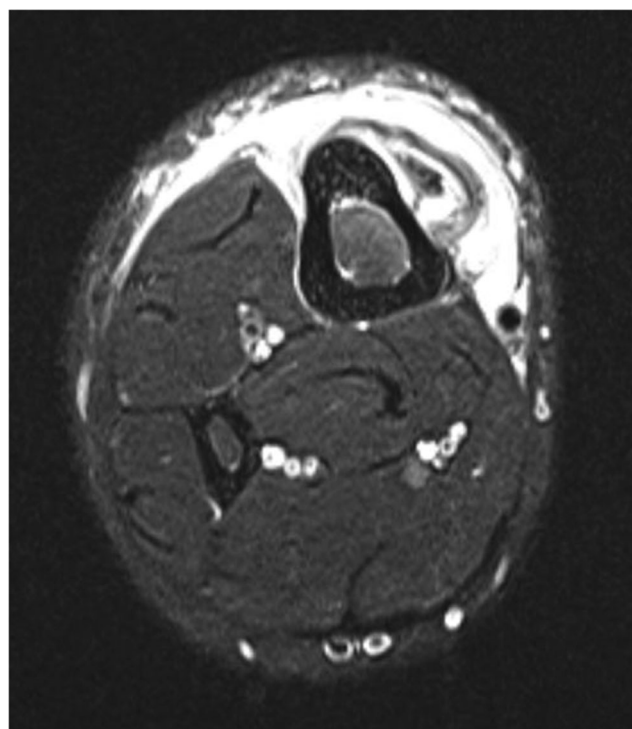


Fig. 4 Axial T2-weighted, fat-suppressed MRI image through the area of maximal swelling of the right leg

Compliance with ethical standards

Conflict of interest Each author certifies that he or she has no commercial associations that might pose a conflict of interest in connection with the submitted article.

The opinions or assertions contained herein are the private views of the authors and are not to be construed as official or reflecting the views of

the Department of Defense or US Government. The authors are employees of the US government. This work was prepared as part of their official duties and, as such there is no copyright to be transferred.

Publisher's note Springer Nature remains neutral with regard to jurisdictional claims in published maps and institutional affiliations.