



Painful right elbow mass

Veronica Attard¹  · Asif Saifuddin¹

Published online: 19 December 2018
© ISS 2018

History

A 74-year-old female presented with a 2-week history of a firm mass along the medial aspect of her right elbow. She reported painful sensorimotor neuropathy of the right hand. She was receiving treatment for hypothyroidism and mild renal impairment but her past medical history was otherwise unremarkable. MRI, US, and an US-guided needle biopsy were performed (Figs. 1, 2, and 3).

Authors' contributions VA wrote the manuscript. All authors reviewed the final manuscript.

Compliance with ethical standards

Conflict of interest The authors declare that they have no conflict of interest.

The diagnosis can be found at <https://doi.org/10.1007/s00256-018-3126-y>

✉ Veronica Attard
veronica2687@gmail.com

¹ Radiology Department, Royal National Orthopaedic Hospital, Stanmore, UK

Fig. 1 **a** Coronal T1W SE, **b** sagittal T2W FSE, and **c** axial fat-suppressed PDW FSE MR images

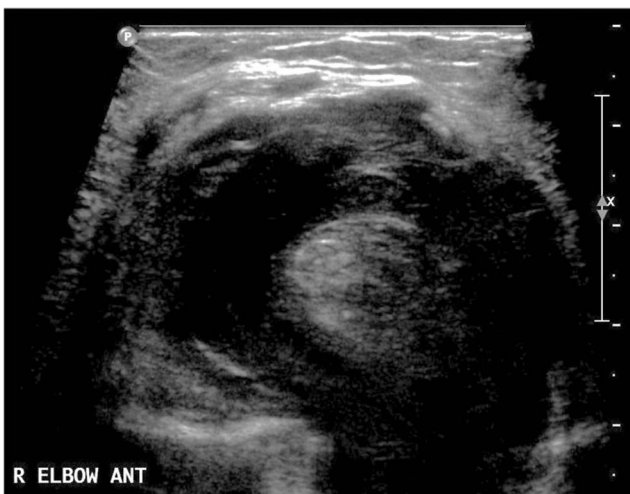
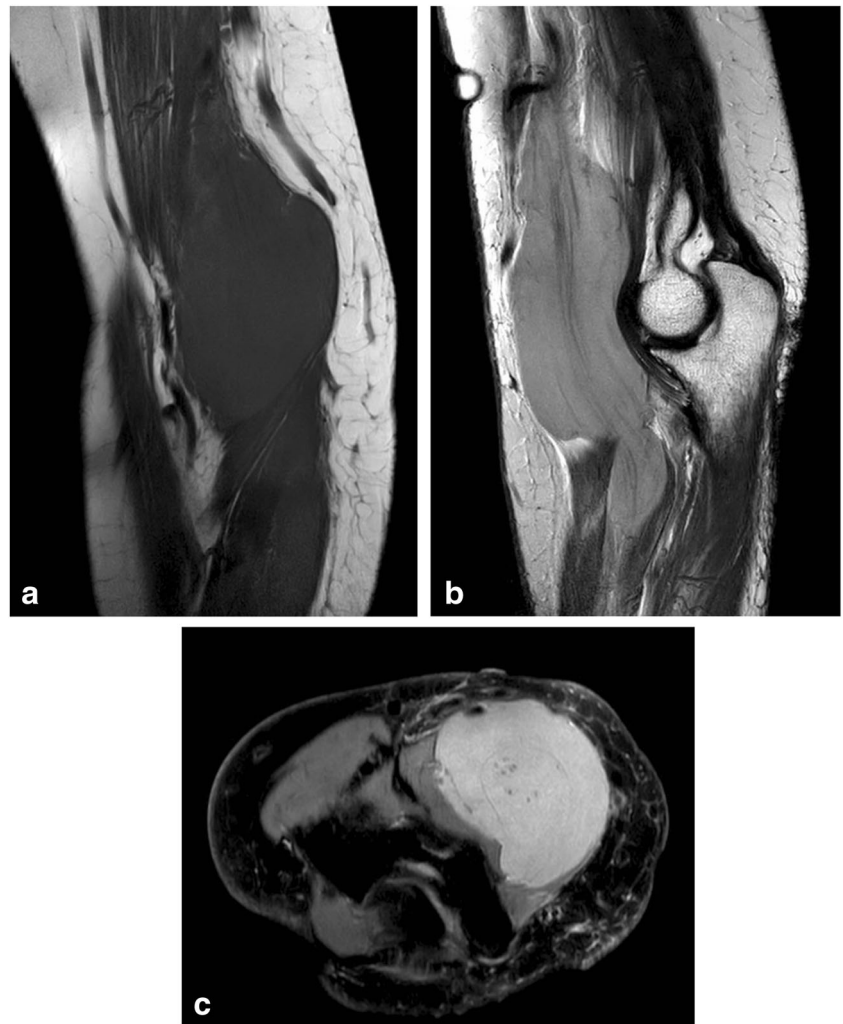
Fig. 2 Transverse US image

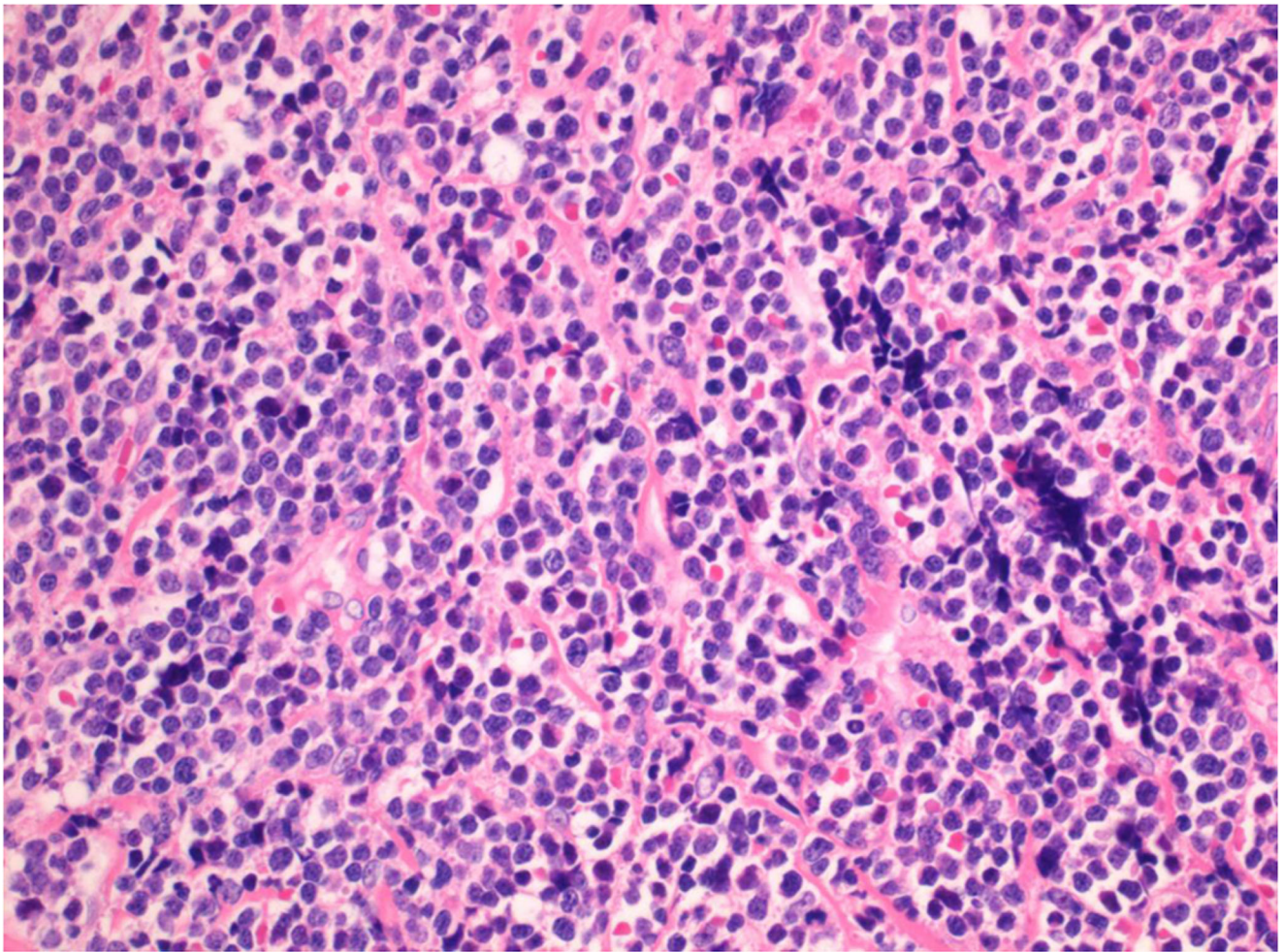


Fig. 3 H&S stain. Magnification 10x