

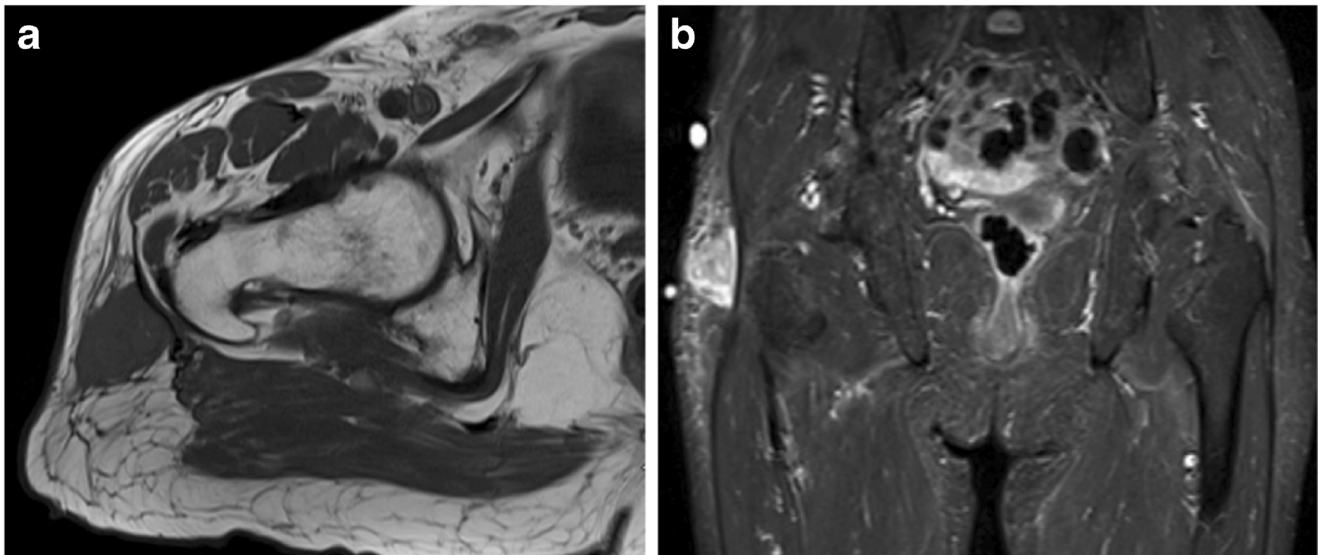


## Test Yourself Question: Enlarging right thigh mass

Ban Sharif<sup>1</sup> · Asif Saifuddin<sup>1</sup>

Published online: 30 July 2018  
© ISS 2018

82-year-old female presents with a 3-month history of a rapidly enlarging mass in her right thigh Figs. 1, 2, 3, 4 and 5.



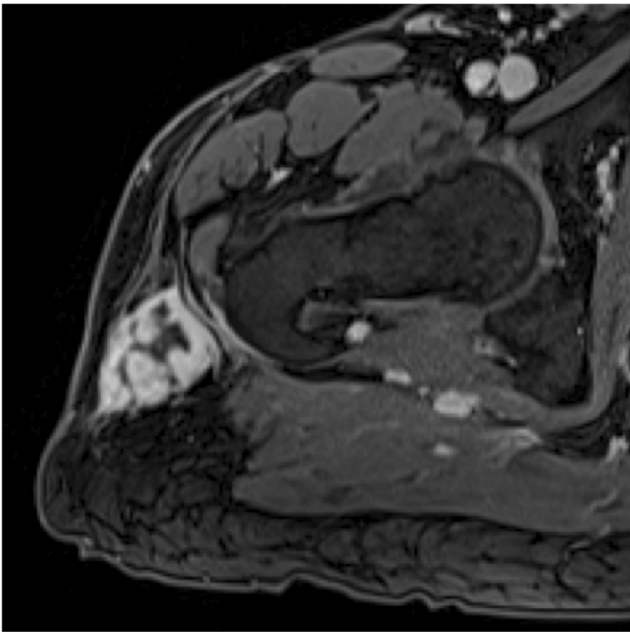
**Fig. 1** a Axial T1W FSE MR image. b Coronal STIR MR image

---

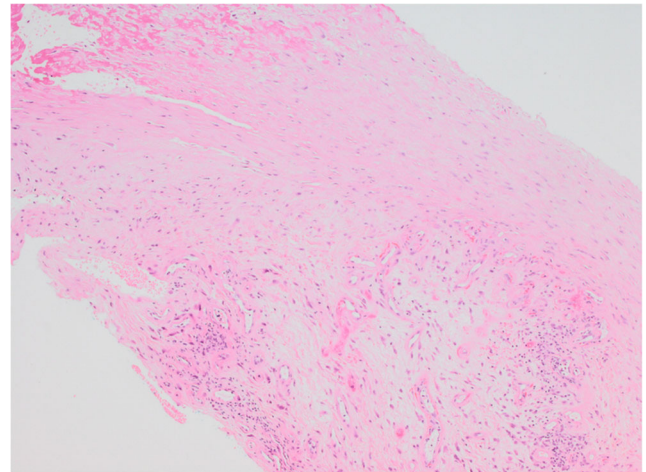
The diagnosis can be found at <https://doi.org/10.1007/s00256-018-3031-4>

✉ Ban Sharif  
ban.sharif@nhs.net

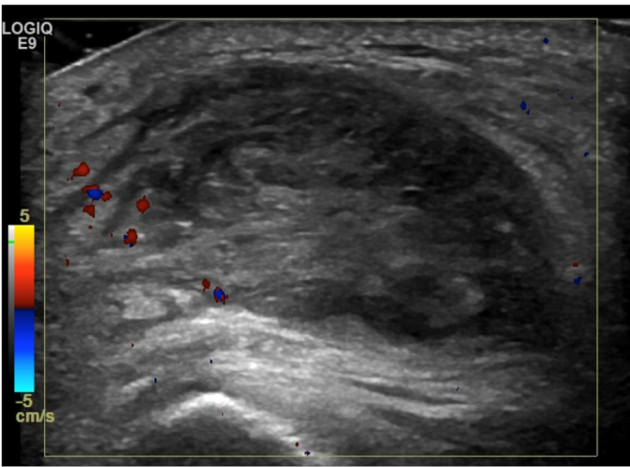
<sup>1</sup> Department of Radiology, Royal National Orthopaedic Hospital, Brockley Hill, Stanmore, Middlesex HA7 4LP, UK



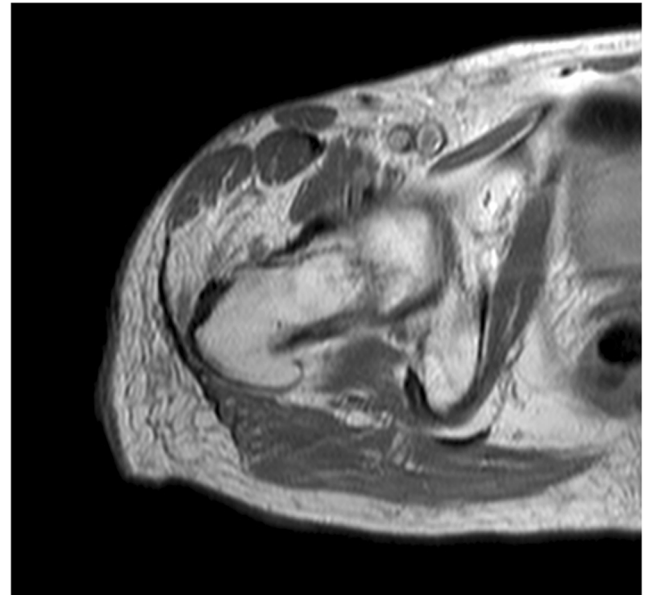
**Fig. 2** Axial T1W FS post gadolinium image



**Fig. 4** Histopathological micrograph [4× magnification haematoxylin and eosin stain (4× H&E)]



**Fig. 3** Static ultrasound image with Doppler flow



**Fig. 5** Axial PDW image performed 21 months after the index MRI scan

### Compliance with ethical standards

**Conflict of interest** The authors declare that they have no conflict of interest.