



A child with painless left wrist swelling

Wai Keung Lo¹ · Cheuk Kei Kathy Wong¹ · Chi Hin Chan¹

Published online: 11 January 2018
© ISS 2018

A 9-year-old child presented with insidious onset painless left wrist swelling for months. (Figs. 1, 2, 3, 4, 5, and 6).

Fig. 1 Radiographs of left wrist

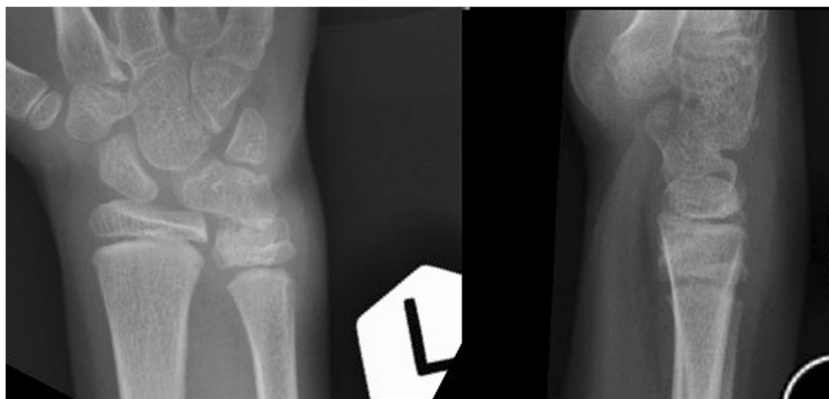
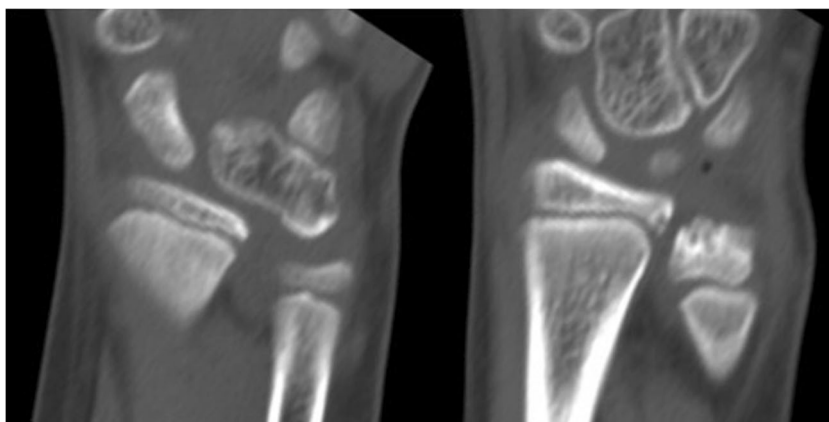


Fig. 2 Coronal CT of left wrist



The diagnosis can be found at <https://doi.org/10.1007/s00256-017-2859-3>

✉ Wai Keung Lo
waikglo@gmail.com

¹ Department of Diagnostic and Interventional Radiology, Kwong Wah Hospital, 25 Waterloo Road, Yau Ma Tei, Hong Kong

Fig. 3 Sagittal CT at sites of pathology

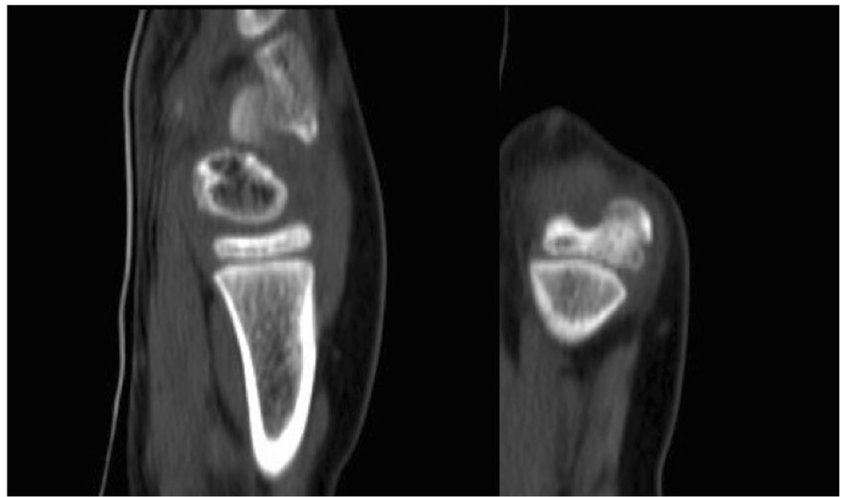

Fig. 4 3D-reformatted CT showing volar, ulnar and dorsal sides of wrist

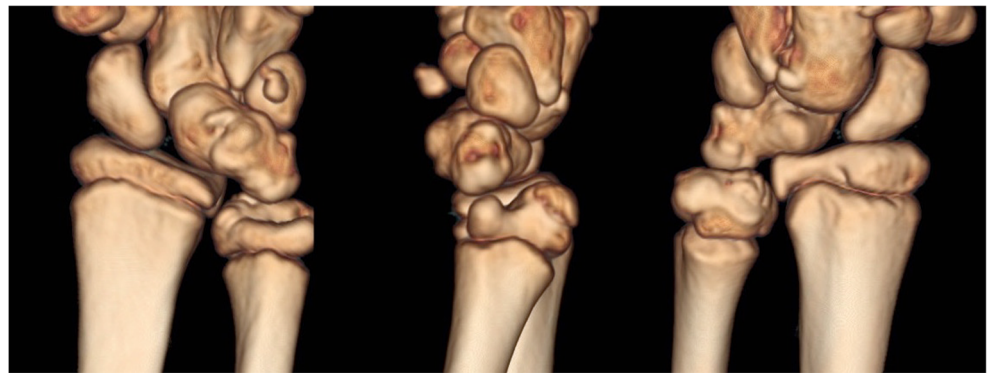


Fig. 5 Coronal T1W MRI of left wrist

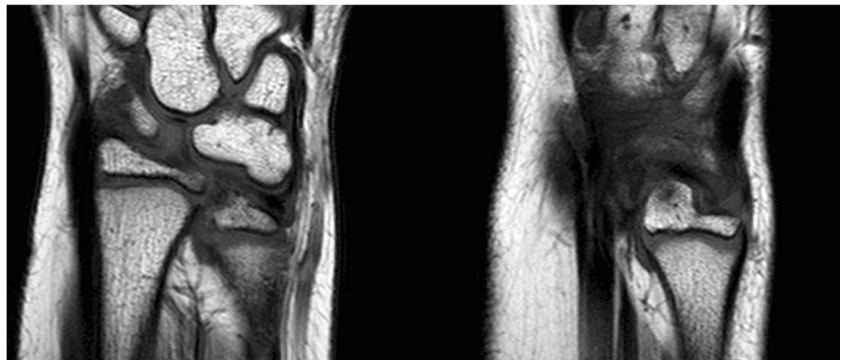


Fig. 6 Coronal water-selective sequence highlighting cartilages of left wrist

