



Correction to: Carotid artery intima-media thickness measurement in children with normal and increased body mass index: a comparison of three techniques

Ramy El Jalbout¹ · Guy Cloutier² · Marie-Hélène Roy Cardinal² · Mélanie Henderson³ · Chantale Lapierre¹ · Gilles Soulez⁴ · Josée Dubois¹

Published online: 23 May 2018
© Springer-Verlag GmbH Germany, part of Springer Nature 2018

Correction to: Pediatric Radiology 2018
<https://doi.org/10.1007/s00247-018-4144-6>

The original version of this article contained a mistake in Fig. 1: The old version was used during figure processing instead of the replacement. The correct figure is shown here. The original article has been corrected.

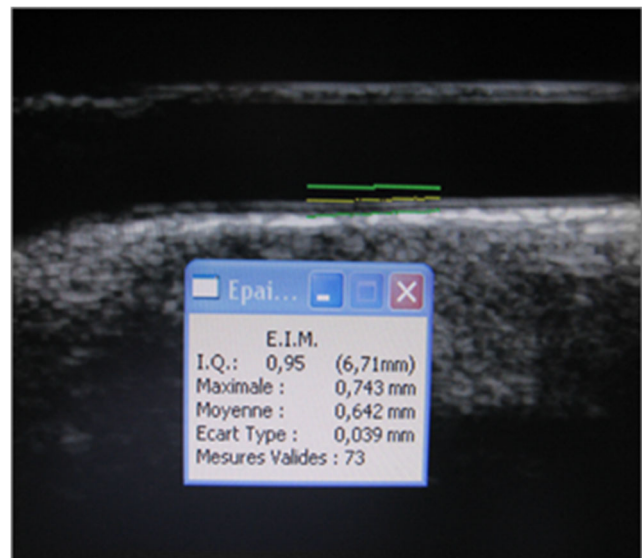


Fig. 1 B-mode longitudinal US image of the common carotid artery of a 12-year-old boy shows the line drawn by the technologist next to the intima-media-lumen interface indicating the location of the automatic measurement by the M'Ath-Std system software. The software automatically gave the intima-media thickness value averaged over the 1-cm segment of the vessel and gave the quality index (we aimed an index superior to 0.5 as explained in text)

The online version of the original article can be found at <https://doi.org/10.1007/s00247-018-4144-6>

✉ Ramy El Jalbout
ramy.el-jalbout.hsj@ssss.gouv.qc.ca

¹ Department of Medical Imaging, University of Montreal, Sainte-Justine University Health Center, 3175 Cote-Sainte-Catherine Road, Montreal, Quebec H3T 1C5, Canada

² Laboratory of Biorheology and Medical Ultrasonics, University of Montreal Hospital Research Center (CRCHUM), Montreal, Quebec, Canada

³ Department of Pediatrics, University of Montreal, Sainte-Justine University Health Center, Montreal, Quebec, Canada

⁴ Department of Radiology, University of Montreal Hospital Center (CHUM), Montreal, Quebec, Canada