


Analysis of normal and dysplastic glenohumeral morphology at magnetic resonance imaging in children with neonatal brachial plexus palsy

Fabian van de Bunt¹  · Michael L. Pearl² · Eric K. Lee² · Lauren Peng² · Paul Didomenico²

Received: 16 December 2016 / Revised: 28 March 2017 / Accepted: 27 April 2017 / Published online: 4 July 2017
© The Author(s) 2017. This article is an open access publication

Abstract

Background Glenoid version and percentage of the humeral head anterior to the scapular line are commonly used 2-D measures to assess deformity of the glenohumeral joint of children with neonatal brachial plexus palsy.

Objective To assess whether glenoid version and percentage of the humeral head anterior to the scapular line would be altered by standardizing the measurements to the orientation of the scapula.

Materials and methods Twenty-one bilateral magnetic resonance imaging (MRI) scans were evaluated by four reviewers. Measurements were performed on the axial image slices and again after applying 3-D reformatting.

Results Three-dimensional reformatting led to inpatient corrections up to 25° for version and −30% for percentage of the humeral head anterior to the scapular line. The mean difference on the involved side between clinical and anatomical version across all subjects from all reviewers was 2.2° ± 3.9° (range: −4.5° to 11.5°). The mean difference in the percentage of the humeral head anterior to the scapular line after reformatting was −1.8% (range: −15.9% to 5.2%).

Conclusion Measurements can differ greatly for the same child depending on technical factors of image acquisition and presentation in the clinical setting. With this study, we present a clinically accessible protocol to correct for scapular

orientation from MRI data of children with neonatal brachial plexus palsy.

Keywords Brachial plexus · Glenoid version · Magnetic resonance imaging · Neonatal brachial plexus palsy · Scapular orientation

Introduction

Neonatal brachial plexus palsy frequently results in altered muscular development of the rotator cuff muscles and osseous deformities of the glenohumeral joint [1–7]. Glenoid version and percentage of the humeral head anterior to the scapular line are established 2-D tools to assess deformities occurring to the complex 3-D shape of the scapula and glenohumeral joint [2, 5, 7, 8].

Normal glenoid version in most studies has been reported close to 0°, with values typically ranging less than 10° in either direction, but generally slightly retroverted [9–16]. A large study by Mintzer et al. [17] analyzed version in young children ($n = 111$) and showed similar results finding slightly more retroversion in children between 0 and 2 years old than in children >2 years old, $-6.3^\circ \pm 6.5^\circ$ compared to $-1.7^\circ \pm 6.4^\circ$, respectively. In children with neonatal brachial plexus palsy and internal rotation contracture, the glenoid version angle is almost always affected, resulting in increased retroversion [3, 8, 18]. This alters normal glenohumeral mechanics and often leads to subluxation of the humeral head, as measured by percentage of the humeral head anterior to the scapular line. Several classification systems have been developed to grade glenohumeral deformity using these measures, as early osseous changes often lead to severe functional impairment warranting surgical treatment [2, 7]. These

✉ Fabian van de Bunt
fabianvbunt@gmail.com

¹ VU University Medical Center, De Boelelaan 1117
1081 HV Amsterdam, The Netherlands

² Kaiser Permanente, 4760 Sunset Blvd Ste. 1213,
Los Angeles, CA 90027, USA

classification systems are important for consideration and follow-up of surgical treatment.

Recently, it has become clear that the accepted gold standard for measuring glenoid version presents reliability issues [10, 19]. In healthy subjects, glenoid version measurements at different heights along the superior/inferior axis of the glenoid have been shown to differ amongst several investigators [20–23]. In general, glenoid version is measured at the mid glenoid level, which is less arbitrary when a CT scan of the shoulder has three or four cuts that traverse the glenoid [11]. Contemporary advancements in technologies allow for a larger selection of mid glenoid level slices. Furthermore, version measurements depend on slice orientation in creating 2-D images and variables that alter scapular orientation (Fig. 1). Especially in a child with an internal rotation contracture, anatomical variation of the glenohumeral joint and patient positioning in the gantry can greatly affect scapular orientation [10, 18, 19, 24]. These factors question the accuracy of these measurements. The findings of these measurements are important to the extent that surgeons use these numbers to indicate the need for surgical intervention. The purpose of this study was to evaluate how this known variability affects measurements of relevant parameters in a neonatal brachial plexus palsy population and evaluate the interobserver reliability of these measures. We hypothesized that glenoid version and percentage of the humeral head anterior to the scapular line as customarily measured in a clinical setting and most of the published literature would be altered by standardizing the measurements to the scapula's orientation. We assessed our measurement outcomes by manipulating 3-D images to bridge

the variance between clinical and anatomical version in a clinical setting.

Materials and methods

With Institutional Review Board approval, 21 bilateral MRI scans (42 image sequences) of a consecutive series of children with internal rotation contractures were evaluated by four independent reviewers trained in a protocol, specific for slice selection and placement of reference axes for version measurements, between September 2011 and June 2012. Our study group existed of 7 boys and 14 girls, with a mean age of 3.8 years old (range: 1.3–12.3 years). The mean passive external rotation measured with the arm by the side was -13° (range: -70° – 40°). The children included in this study were all candidates for surgical intervention, therefore MRI was conducted. The MRI studies were performed on a 1.5-T MRI unit (Signa; General Electric Medical Systems, Milwaukee, WI) with the use of Signa 5X software. Thin-section 3-D axial gradient-echo images (repetition time, 38 ms; echo time, 15 ms; flip angle, 20° ; two signals acquired; 2-mm section thickness with 0-mm spacing, 120-mm field of view and 256×160 matrix) were made of both shoulders in the axial plane. Dedicated shoulder surface coils were used. Children were not moved in the gantry between securing images from the shoulder and corresponding elbow to preserve the coordinate system of the humerus. Children younger than 7 years of age are imaged under general anesthesia or sedation, according to our radiology and anesthesia department guidelines for children of that age. There were no complications as a result of the general anesthesia or sedation. Children were placed in the supine position with both arms placed against the side of the body and imaged simultaneously, parallel to each other and coaxial to the gantry as well as the contracture or body shape would allow. The total length of this protocol is 60–90 min. The MRI scans were anonymized and measured for glenoid version and percentage of the humeral head anterior to the scapular line by four independent reviewers. They included three musculoskeletal radiologists, one a fellowship-trained musculoskeletal radiologist with >10 years of experience outside of training (L.P.) and two senior residents in radiology fellowship training in musculoskeletal radiology (E.K.L.), and one fellowship-trained orthopaedic surgeon with 25 years of experience and a specialization in shoulder and elbow pathology (M.L.P.). The measurement protocol applied in this study is previously described by van de Bunt et al. [25]. Briefly, reviewers were trained to use our measurement protocol for 6 1-h sessions during a 6-week period before the study commenced. Reviewers were blinded to each other's measurements and their own between clinical and reformatted measurements until the data collection was complete. Images were stored in DICOM (Digital Imaging and Communications

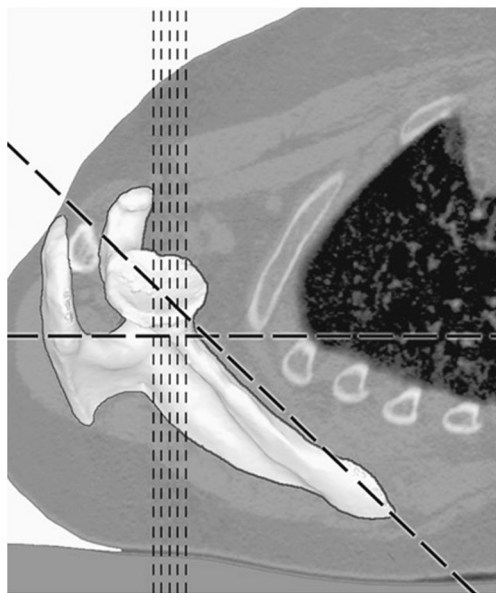


Fig. 1 The difference between the orientation of standard axial 2-D CT scans (vertical lines) and the orientation of the scapula (diagonal line), the horizontal line indicates the orientation of the table the patient is laying on (supine position) [19]

in Medicine) format for further processing using radiologic software programs. General Electric Advantage Workstation with Version 4.4 reformatting software was used by the musculoskeletal radiologists and Osirix (Pixmeo, Geneva, Switzerland) was used by the orthopaedic surgeon. The first decision made in version measurement was choosing the mid glenoid slice [9, 11, 14, 26]. Reviewers were instructed to use the slice that represented the greatest glenoid girth, free from artifact and distortion. In this population, severe deformities and occasional artifacts can alter one’s choice of points from which to draw the line representing the anterior and posterior corners of the glenoid. The image slice selection chosen by the reviewer was recorded as part of the analysis.

Reference axes were chosen as conventionally described [11]. Retroversion was measured as the angle subtended by the glenoid line and a perpendicular to the scapular line on the posterior aspect of the scapula. Retroversion was assigned negative values and anteversion positive values as consistent with literature. Clinical version was measured on the axial images, as they were delivered from the technician through the picture archiving and communication system (PACS). Anatomical version measurements were made after the reformatting protocol according to the study by van de Bunt et al. [25]. The goal of reformatting is to realign reference axes so that the coronal, transverse and sagittal planes relate to the scapula and the glenoid. Reformatting alters the image slice sequence after which the orders are not directly comparable among reviewers so this was not recorded. The percentage of the humeral head anterior to the middle of the glenoid fossa (percentage of the humeral head anterior to the scapular line) was measured as described in earlier studies [7, 8, 18, 27].

Data analysis

Means, standard deviations, and minimum and maximum values for numeric variables, as well as correlations between numeric variables, were computed for the involved and uninvolved sides separately, as well as for both sides together. The

reliability of the quantitative measurements (glenoid version and humeral subluxation measured as percentage of the humeral head anterior to the scapular line) using the clinical and anatomical method was measured according to the method of Bland and Altman [28]. Pearson correlation coefficients were estimated between passive external rotation and glenoid version and percentage of the humeral head anterior to the scapular line measurements.

Results

Involved side

The mean clinical version from all reviewers on the involved side was $-28.2^\circ \pm 16.1^\circ$ (range: -53.5° to -6.3°). The maximum clinical retroversion measurement by a single reviewer was -60° , and the minimum version measurement was -2° (Table 1). In two instances, all four reviewers selected the same image slice to make their measurements. For four children, three out of four reviewers chose the same slice. For 14 children, 2 of 4 reviewers chose the same slice. For one subject, the reviewers all chose different slices. Using the stated image slice selection criteria, reviewers differed in their selection by a mean of 2.5 slices per child (range: 0–6). The percentage of the humeral head anterior to the scapular line averaged 26.9%, ranging from 0% to 57.8%.

The mean anatomical version from all reviewers was $-26^\circ \pm 15.8^\circ$ (range: -53.4° to -4.1°). The maximum anatomical retroversion measurement by a single reviewer was -66° , and the minimum version measurement was -1° (Table 1). The percentage of the humeral head anterior to the scapular line averaged 28.7%, ranging from 3.4% to 57.1%.

Uninvolved side

Mean clinical version on the uninvolved side was $-5.7^\circ \pm 3.1^\circ$ (range: -11.2° to 1.1°), with maximum anteversion of 5° and retroversion of -15° as measured by a single reviewer. In one instance, all four reviewers selected the same image slice to

Table 1 Clinically assessed glenoid version measurements by reviewers

	Age	External rotation	Clinical Version (°)						Anatomical version (°)					
			Reviewer				Mean	Range	Reviewer				Mean	Range
			1	2	3	4			1	2	3	4		
Mean	3.75	-13.33	-29.81	-28.86	-26.29	-28.00	-28.24	9.52	-25.38	-25.48	-23.71	-29.57	-26.04	11.95
Standard deviation	3.08	26.00	17.29	17.66	16.54	15.04	16.13	5.33	16.69	16.88	15.13	17.72	15.86	7.83
Minimum	1.13	-70.00	-54.00	-52.00	-60.00	-54.00	-53.50	2.00	-50.00	-56.00	-53.00	-66.00	-53.50	4.00
Maximum	12.31	40.00	-4.00	-2.00	-7.00	-7.00	-6.25	21.00	-2.00	-1.00	-4.00	-5.00	-4.00	38.00

Table 2 Glenoid version angle difference after 3-D reformatting

	Version angle difference: Involved side (°)						Version angle difference: Uninvolved side (°)					
	Reviewer				Mean	Range	Reviewer				Mean	Range
	1	2	3	4			1	2	3	4		
Mean	4.43	3.38	2.51	-1.57	2.19	14.03	1.00	-0.24	0.48	-1.81	-0.14	7.21
Standard deviation	6.96	8.09	5.53	6.89	3.92	7.66	3.54	4.56	3.79	5.50	3.23	3.81
Minimum	-8.00	-10.00	-10.60	-13.00	-4.55	6.00	-6.00	-10.00	-8.25	-12.00	-6.65	1.00
Maximum	25.00	25.00	12.84	11.00	11.46	37.00	10.00	9.00	7.00	6.00	8.00	13.40
Range	33.00	35.00	23.44	24.00	16.01	31.00	16.00	19.00	15.25	18.00	14.65	12.40

make their measurements. For seven children, three out of four reviewers chose the same slice. For 12 children, 2 out of 4 reviewers chose the same slice. For one subject, the reviewers all chose different slices. Using the stated image slice selection criteria, reviewers differed in their selection by a mean of 2.4 slices per child (range: 0–10). The percentage of the humeral head anterior to the scapular line averaged 48.3%, ranging from 35% to 67%.

The mean anatomical version on the uninvolved side was $-5.9^\circ \pm 2.8^\circ$ (range: -12.5° to -1.7°). The maximum retroversion measurement by a single reviewer was -16° , and anteversion measurement was 1° . The percentage of the humeral head anterior to the scapular line averaged 47.4%, ranging from 41.5% to 54.8%.

Measured difference between clinical and anatomical version measurement

The mean difference on the involved side between the clinical and anatomical versions across all children from all reviewers was $2.2^\circ \pm 3.9^\circ$ (range: -4.5° to 11.5°)

(Table 2). The range amongst the reviewers was -13° to 25° . On the uninvolved side, the mean difference between both measurement methods averaged $-0.1^\circ \pm 3.2^\circ$ (range: -6.7° to 8°). The range among the reviewers was -12° to 10° . The Bland-Altman plot demonstrated a bias (mean difference) of 2.19° (standard deviation [SD]: 3.92) over all measurements at the involved side and a bias of -0.14° (SD: 3.22) on the uninvolved side (Fig. 2). Nearly all measurements fell within the 95% level of agreement. Both methods demonstrated one outlier, which involved a different patient. The distribution of measurements is larger on the uninvolved side as opposed to the involved side.

Measured difference between clinical percentage of the humeral head anterior to the scapular line and percentage of the humeral head anterior to the scapular line measurement after reformatting

The mean difference in percentage of the humeral head anterior to the scapular line after reformatting was -1.8% (range: -

Fig. 2 Bland-Altman plot demonstrates a bias of 2.19° (standard deviation [SD]: 3.92) over all measurements at the involved side and a bias of -0.14° (SD: 3.22) on the uninvolved side

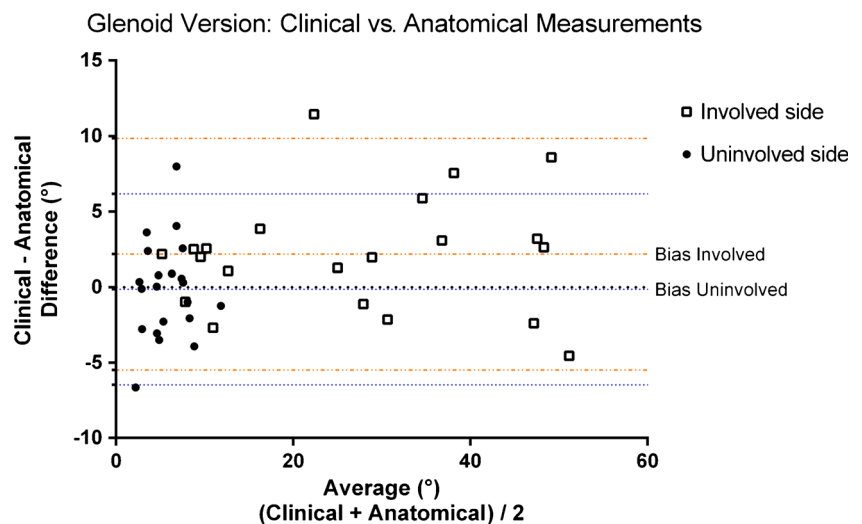


Table 3 Percentage of the humeral head anterior to the scapular line (PHHA), difference after 3-D reformatting

	PHHA difference: Involved side (%)						PHHA difference: Uninvolved side (%)					
	Reviewer				Mean	Range	Reviewer				Mean	Range
	1	2	3	4			1	2	3	4		
Mean	-4.36	0.68	-3.22	-0.16	-1.77	15.52	-0.37	1.17	1.08	1.58	0.86	9.34
Standard deviation	6.39	9.96	4.76	11.07	5.35	6.76	5.40	6.32	4.58	7.62	4.38	5.69
Minimum	-17.18	-14.53	-13.61	-30.04	-15.91	6.71	-11.42	-9.60	-5.65	-12.62	-8.73	1.12
Maximum	4.31	21.83	4.91	23.16	5.19	34.12	10.37	16.70	12.52	22.95	10.62	26.60
Range	21.49	36.36	18.52	53.20	21.10	27.41	21.79	26.30	18.17	35.57	19.35	25.48

15.9% to 5.2%). The range amongst the reviewers was -30% to 23.1%. For the uninvolved side, the mean difference was 0.9% (range: -8.7% to 10.6%). The range amongst the reviewers was -12.6% to 23% (Table 3). The Bland-Altman plot demonstrated a bias (mean difference) of -1.77% (SD: 5.35) over all measurements at the involved side and a bias of 0.86% (SD: 4.38) on the uninvolved side (Fig. 3). Nearly all measurements fell within the 95% level of agreement, but both methods demonstrated one exception. The distribution of measurements is larger on the uninvolved side as opposed to the involved side.

Passive external rotation measurements were correlated with anatomical glenoid version and percentage of the humeral head anterior to the scapular line measurements. For both anatomical version ($r = 0.643$; $P = 0.002$) and anatomical percentage of the humeral head anterior to the scapular line measurements there was a significant correlation ($r = 0.611$; $P = 0.003$). The passive external rotation measurements decreased, with an increase in glenoid

retroversion and decrease of percentage of the humeral head anterior to the scapular line.

Discussion

The mean glenoid version and percentage of the humeral head anterior to the scapular line measurements observed for both the clinical and anatomical method are consistent with those in literature [2, 4, 7, 8, 18, 29, 30]. However, measurements can differ greatly for the same patient depending on technical factors of image acquisition and presentation in the clinical setting. The effect of 3-D reformatting on glenoid version measurements is best represented in the difference in measurement outcomes between both methodologies (Table 2, Figs. 4 and 5). In our study, we calculated a mean difference of 2.2°; however, the range in measured differences after 3-D reformatting within patients varied from -13° to 25° on the involved side as opposed to -12° to 10° on the uninvolved side. In no instance is the range in measured differences among observers lower than 7° on the involved side. The range in measured differences is >10° in 12 out of 21 measurements versus 5 out of 21 on the uninvolved side. These numbers represent overestimation as well as underestimation of the version angle using the clinical method, suggesting there is no systematic bias in the clinical version measurements. Over- or underestimation of the glenoid version angle can alter clinical decision-making regarding surgical indications. The 3-D reformatting protocol aims to introduce a systematic approach to improve the accuracy of measurement parameters relative to the scapula, in this study glenoid version and percentage of the humeral head anterior to the scapular line. Both the clinical and anatomical measurement methods were acceptably reliable in terms of inter- and intraobserver repeatability (precision); however, applying the reformatting protocol improves the accuracy by correcting for the variation in scapular

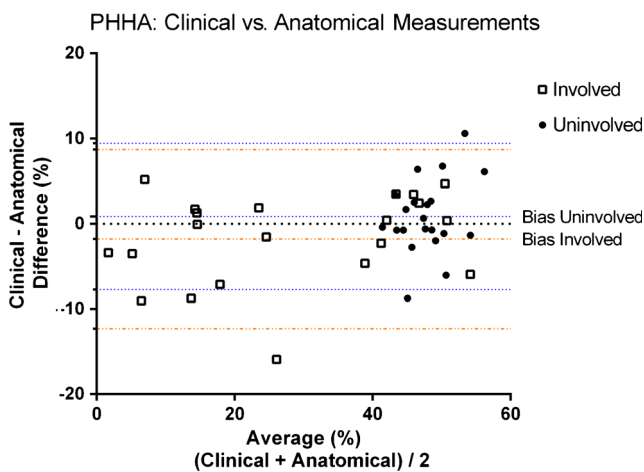


Fig. 3 Bland-Altman plot demonstrates a bias of -1.77% (standard deviation [SD]: 5.35) over all measurements at the involved side and a bias of 0.86% (SD: 4.38) on the uninvolved side. PHHA percentage of the humeral head anterior to the scapular line

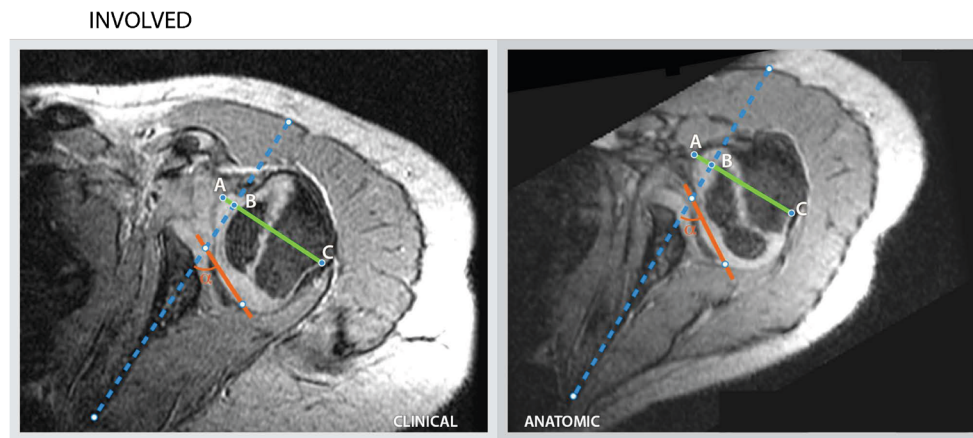


Fig. 4 Measurements for child 1, performed by reviewer 3 for the involved with according measurement outcomes. The clinical and anatomical measurement outcomes for glenoid version (-90°) and percentage of the humeral head anterior to the scapular line ($AB/AC * 100$) are 21° and 11% , and 32° and 15% , respectively. *Dotted blue line:*

scapular line, *Red line:* glenoid line, *Green line:* transverse line through the margins of the humeral head, perpendicular to the scapular line, *AB:* the distance of the humeral head, above the scapular line, *AC:* the distance of the green line perpendicular to the scapular line, α : The angle between the glenoid line and the scapular line (glenoid version = $\alpha - 90$)

orientation relative to the gantry due to patient positioning, variation in body habitus and posture. These concerns are especially relevant in this population with internal rotation contractures and other deformities of the shoulder. The 3-D reformatting protocol offers a clinically accessible recalibration tool for scapular orientation.

The most common decision in pursuing surgical treatment in this patient population is choosing between a humeral rotational osteotomy and a soft-tissue procedure. This decision is usually based primarily on the extent of glenohumeral deformity (inclusive of glenoid retroversion) and potential for remodeling [30–35]. The findings of this study suggest that these measurements can be misleading without correction for scapular orientation. Furthermore, minimizing measurement deviations allows for more reliable assessment of possible bony remodeling after surgical intervention. For

percentage of the humeral head anterior to the scapular line measures, similar differences were found. The range in difference between clinical and anatomical measures varied in both directions (range: -30% to 23.1%). Similar clinical implications apply as to glenoid version measurements.

Various factors are involved in picking the best slice for version measurement. Assessing the mid-point slice, and how well the anterior/posterior edges are visualized, used to be less arbitrary when imaging techniques allowed for a limited number of slices. In the neonatal brachial plexus palsy population, severe osseous deformities can cloud mid-point assessment and appropriate border selection as illustrated in our study where slice selection proved to be inconsistent. Reviewers picked the same slice for version measurement in only 3 of the 42 possibilities. Note, there are fewer slices to pick as there would be in a skeletally mature scapula. These factors have

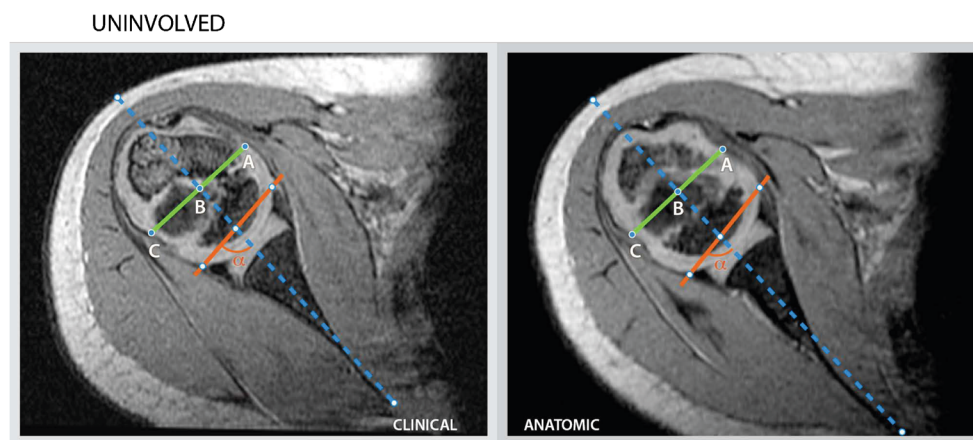


Fig. 5 Measurement for child 1, performed by reviewer 3 for the uninvolved side with according measurement outcomes. The clinical and anatomical measurement outcomes for glenoid version (-90°) and percentage of the humeral head anterior to the scapular line ($AB/AC * 100$) are 7° and 49% , and 10° and 46% , respectively. *Dotted blue line:*

scapular line, *Red line:* glenoid line, *Green line:* transverse line through the margins of the humeral head, perpendicular to the scapular line, *AB:* the distance of the humeral head (AB), above the scapular line, *AC:* the distance of the green line perpendicular to the scapular line, α : The angle between the glenoid line and the scapular line (glenoid version = $\alpha - 90$)

yet not been taken into account when selecting the appropriate slice using contemporary imaging techniques. The observations made in our study regarding slice selection confirm this; however, it does not offer a consistent methodological solution.

With the software used for this study, the ability to manipulate 3-D models of the anatomy was limited. However, this software's wide availability and open source make it a clinically useful tool for manipulating the 3-D anatomy of the scapula. For the coronal and transverse planes, the superior/inferior and anterior/posterior edges of the glenoid were readily identifiable and comparable with 3-D modeling. Some subjectivity is added in defining the sagittal plane neatly in line with the scapular body, since the scapular body is usually curved and rarely sits nicely in place. Scrolling back and forth through the 2-D images medial to the glenoid allows for approximation of the scapular body axis. This step admittedly would benefit from greater precision.

This study demonstrated comparable interobserver variability between the clinical and anatomical version measurements (Figs. 2 and 3).

For practical reasons, we did not investigate all separate components of the measurement process. Slice selection was recorded; however, variance in version from slice to slice was not assessed. Neither were reference points from which the measurement axes for scapular and glenoid lines are determined. Furthermore, intraobserver variability was not assessed, since we expected interobserver differences to exceed intraobserver differences. The focus of this study was on variability among observers related to the MRI scanning process and the clinical relevance accompanying the measured difference of the version angle after reformatting. The version values observed in this study are consistent with the literature, both for the involved and uninvolved side, as well as for clinical and anatomical methodologies. The precise value of version depends on the chosen definition of the scapular plane. When using 3-D models, which are so far solely available for study purposes, these measurements will become more precise [10, 19].

Conclusion

The findings of this study show that glenoid version and percentage of the humeral head anterior to the scapular line are dependent on scapular orientation, as previously identified in other studies using scapular models in normal and arthritic shoulders, and extend this observation to the neonatal brachial plexus palsy population with internal rotation contractures. Measurements can differ greatly for the same patient depending on technical factors of image acquisition and presentation in the clinical setting. We recommend applying a 3-D

reformatting protocol for accurate measurement of these parameters.

Compliance with ethical standards

Conflicts of interest None

Open Access This article is distributed under the terms of the Creative Commons Attribution 4.0 International License (<http://creativecommons.org/licenses/by/4.0/>), which permits unrestricted use, distribution, and reproduction in any medium, provided you give appropriate credit to the original author(s) and the source, provide a link to the Creative Commons license, and indicate if changes were made.

References

1. Kambhampati SB, Birch R, Cobiella C et al (2006) Posterior subluxation and dislocation of the shoulder in obstetric brachial plexus palsy. *J Bone Joint Surg Br* 88:213–219
2. Pearl ML, Edgerton BW (1998) Glenoid deformity secondary to brachial plexus birth palsy. *J Bone Joint Surg Am* 80:659–667
3. Pearl ML, Edgerton BW, Kon DS et al (2003) Comparison of arthroscopic findings with magnetic resonance imaging and arthrography in children with glenohumeral deformities secondary to brachial plexus birth palsy. *J Bone Joint Surg Am* 85-A:890–898
4. van der Sluijs JA, van der Meij M, Verbeke J et al (2003) Measuring secondary deformities of the shoulder in children with obstetric brachial plexus lesion: reliability of three methods. *J Pediatr Orthop B* 12:211–214
5. van der Sluijs JA, van Ouwkerk WJ, de Gast A et al (2001) Deformities of the shoulder in infants younger than 12 months with an obstetric lesion of the brachial plexus. *J Bone Joint Surg Br* 83-B:551–555
6. Waters PM, Monica JT, Earp BE et al (2009) Correlation of radiographic muscle cross-sectional area with glenohumeral deformity in children with brachial plexus birth palsy. *J Bone Joint Surg Am* 91:2367–2375
7. Waters PM, Smith GR, Jaramillo D (1998) Glenohumeral deformity secondary to brachial plexus birth palsy. *J Bone Joint Surg Am* 80:668–677
8. Kozin SH, Chafetz RS, Barus D et al (2006) Magnetic resonance imaging and clinical findings before and after tendon transfers about the shoulder in children with residual brachial plexus birth palsy. *J Shoulder Elb Surg* 15:554–561
9. Bokor DJ, O'Sullivan MD, Hazan GJ (1999) Variability of measurement of glenoid version on computed tomography scan. *J Shoulder Elb Surg* 8:595–598
10. Bryce CD, Davison AC, Lewis GS et al (2010) Two-dimensional glenoid version measurements vary with coronal and sagittal scapular rotation. *J Bone Joint Surg Am* 92:692–699
11. Friedman RJ, Hawthorne KB, Genez BM (1992) The use of computerized tomography in the measurement of glenoid version. *J Bone Joint Surg Am* 74:1032–1037
12. Kwon YW, Powell KA, Yum JK et al (2005) Use of three-dimensional computed tomography for the analysis of the glenoid anatomy. *J Shoulder Elb Surg* 14:85–90
13. Mallon WJ, Brown HR, Vogler JB 3rd et al (1992) Radiographic and geometric anatomy of the scapula. *Clin Orthop Relat Res* 277:142–154
14. Randelli M, Gambrioli PL (1986) Glenohumeral osteometry by computed tomography in normal and unstable shoulders. *Clin Orthop Relat Res* 208:151–156

15. Scalise JJ, Codsí MJ, Bryan J et al (2008) The three-dimensional glenoid vault model can estimate normal glenoid version in osteoarthritis. *J Shoulder Elb Surg* 17:487–491
16. Welsch G, Mamisch TC, Kikinis R et al (2003) CT-based preoperative analysis of scapula morphology and glenohumeral joint geometry. *Comput Aided Surg* 8:264–268
17. Mintzer CM, Waters PM, Brown DJ (1996) Glenoid version in children. *J Pediatr Orthop* 16:563–566
18. Pearl ML, Woolwine S, van de Bunt F et al (2013) Geometry of the proximal humeral articular surface in young children: a study to define normal and analyze the dysplasia due to brachial plexus birth palsy. *J Shoulder Elb Surg* 22:1274–1284
19. Hoenecke HR Jr, Hermida JC, Flores-Hernandez C et al (2010) Accuracy of CT-based measurements of glenoid version for total shoulder arthroplasty. *J Shoulder Elb Surg* 19:166–171
20. Inui H, Sugamoto K, Miyamoto T et al (2001) Evaluation of three-dimensional glenoid structure using MRI. *J Anat* 199:323–328
21. Lewis GS, Armstrong AD (2011) Glenoid spherical orientation and version. *J Shoulder Elb Surg* 20:3–11
22. Monk AP, Berry E, Limb D et al (2001) Laser morphometric analysis of the glenoid fossa of the scapula. *Clin Anat* 14:320–323
23. Schlemmer B, Dosch JC, Gicquel P et al (2002) Computed tomographic analysis of humeral retrotorsion and glenoid retroversion. *Rev Chir Orthop Reparatrice Appar Mot* 88:553–560
24. Scalise JJ, Codsí MJ, Bryan J et al (2008) The influence of three-dimensional computed tomography images of the shoulder in preoperative planning for total shoulder arthroplasty. *J Bone Joint Surg Am* 90:2438–2445
25. van de Bunt F, Pearl ML, Lee EK et al (2015) Glenoid version by CT scan: an analysis of clinical measurement error and introduction of a protocol to reduce variability. *Skelet Radiol* 44:1627–1635
26. Nyffeler RW, Jost B, Pfirrmann CW et al (2003) Measurement of glenoid version: conventional radiographs versus computed tomography scans. *J Shoulder Elb Surg* 12:493–496
27. Waters PM, Bae DS (2005) Effect of tendon transfers and extra-articular soft-tissue balancing on glenohumeral development in brachial plexus birth palsy. *J Bone Joint Surg Am* 87:320–325
28. Bland JM, Altman DG (1986) Statistical methods for assessing agreement between two methods of clinical measurement. *Lancet* 1:307–310
29. Hogendoorn S, van Overvest KL, Watt I et al (2010) Structural changes in muscle and glenohumeral joint deformity in neonatal brachial plexus palsy. *J Bone Joint Surg Am* 92:935–942
30. Kozin SH, Boardman MJ, Chafetz RS et al (2010) Arthroscopic treatment of internal rotation contracture and glenohumeral dysplasia in children with brachial plexus birth palsy. *J Shoulder Elb Surg* 19:102–110
31. Hui JH, Torode IP (2003) Changing glenoid version after open reduction of shoulders in children with obstetric brachial plexus palsy. *J Pediatr Orthop* 23:109–113
32. Pearl ML, Edgerton BW, Kazimiroff PA et al (2006) Arthroscopic release and latissimus dorsi transfer for shoulder internal rotation contractures and glenohumeral deformity secondary to brachial plexus birth palsy. *J Bone Joint Surg Am* 88:564–574
33. Pedowitz DI, Gibson B, Williams GR et al (2007) Arthroscopic treatment of posterior glenohumeral joint subluxation resulting from brachial plexus birth palsy. *J Shoulder Elb Surg* 16:6–13
34. van der Sluijs JA, van Ouwerkerk WJ, de Gast A et al (2004) Treatment of internal rotation contracture of the shoulder in obstetric brachial plexus lesions by subscapular tendon lengthening and open reduction: early results and complications. *J Pediatr Orthop B* 13:218–224
35. Waters PM, Bae DS (2006) The effect of derotational humeral osteotomy on global shoulder function in brachial plexus birth palsy. *J Bone Joint Surg Am* 88:1035–1042