

# Death in the octopus' garden: fatal blue-lined octopus envenomations of adult green sea turtles

Kathy A. Townsend · Jens Altvater ·  
Michael C. Thomas · Qamar A. Schuyler ·  
Geoffrey W. Nette

Received: 27 July 2011 / Accepted: 18 November 2011 / Published online: 3 December 2011  
© The Author(s) 2011. This article is published with open access at Springerlink.com

**Abstract** The blue-lined octopus *Hapalochlaena fasciata* contains the powerful neuromuscular blocker tetrodotoxin (TTX), which causes muscle weakness and respiratory failure. *H. fasciata* is regarded as one of the most venomous marine animals in the world, and multiple human fatalities have been attributed to the octopus. To date, there have been no recorded incidents of an envenomation of a wild animal. Here, we present a newly developed, multi-stage tandem mass spectrometry technique that provides unequivocal evidence for two cases of envenomation of two ~110 kg herbivorous green sea turtles by two tiny cryptic blue-lined octopuses (~4 cm body length). These cases of accidental ingestion provide evidence for the first time of the antipredator effect of TTX and highlight a previously unconsidered threat to turtles grazing within seagrass beds.

## Introduction

Twenty thousand sea turtles are estimated to reside in Moreton Bay, off Brisbane in Queensland, Australia (Limpus et al. 1994). Moreton Bay's expansive seagrass beds are an important feeding ground for the endangered green turtle (*Chelonia mydas*) (Limpus et al. 1994; Brand-Gardner et al. 1999; Arthur et al. 2008). The seagrass beds also provide important habitat for many marine creatures, including juvenile fish, crustaceans, molluscs, and cephalopods (Weng 1990; Davie 1998). One of the species of cephalopods sheltering within these seagrass beds is the venomous blue-lined octopus, *Hapalochlaena fasciata* (Norman and Reid 2000). This visually cryptic animal hides among tide pools, blending in with its surroundings via pigmented chromatophore organs. When threatened, the animal flashes bright blue rings and lines, which act as a warning to potential predators (Tranter and Augustin 1973; Mathger et al. 2008).

The saliva of *H. fasciata* contains tetrodotoxin (TTX), a powerful neurotoxin that it uses to incapacitate prey such as large fish and crustaceans. It has been hypothesized that TTX is also used for protection from predators, although to date there has been no empirical evidence to support this assumption (Tranter and Augustin 1973; Yotsu-Yamashita et al. 2007). TTX is a potent neuromuscular blocker that causes muscle weakness and respiratory failure and it is known as one of the most toxic venoms to mammals. TTX has been shown to have a wholly lethal dose (LD) of 5.8 µg/kg via intramuscular injection (Xu et al. 2003), and it is estimated that a tiny 25 g octopus possesses enough venom to fatally paralyze ten 75 kg humans (Narahashi et al. 1967; Sutherland 1983; Williamson 1987). While there are high levels of TTX in many of the tissues of *H. fasciata*, including their arms and mantel (see Yotsu-Yamashita et al. 2007; Williams and Caldwell 2009;

---

Communicated by R. Lewison.

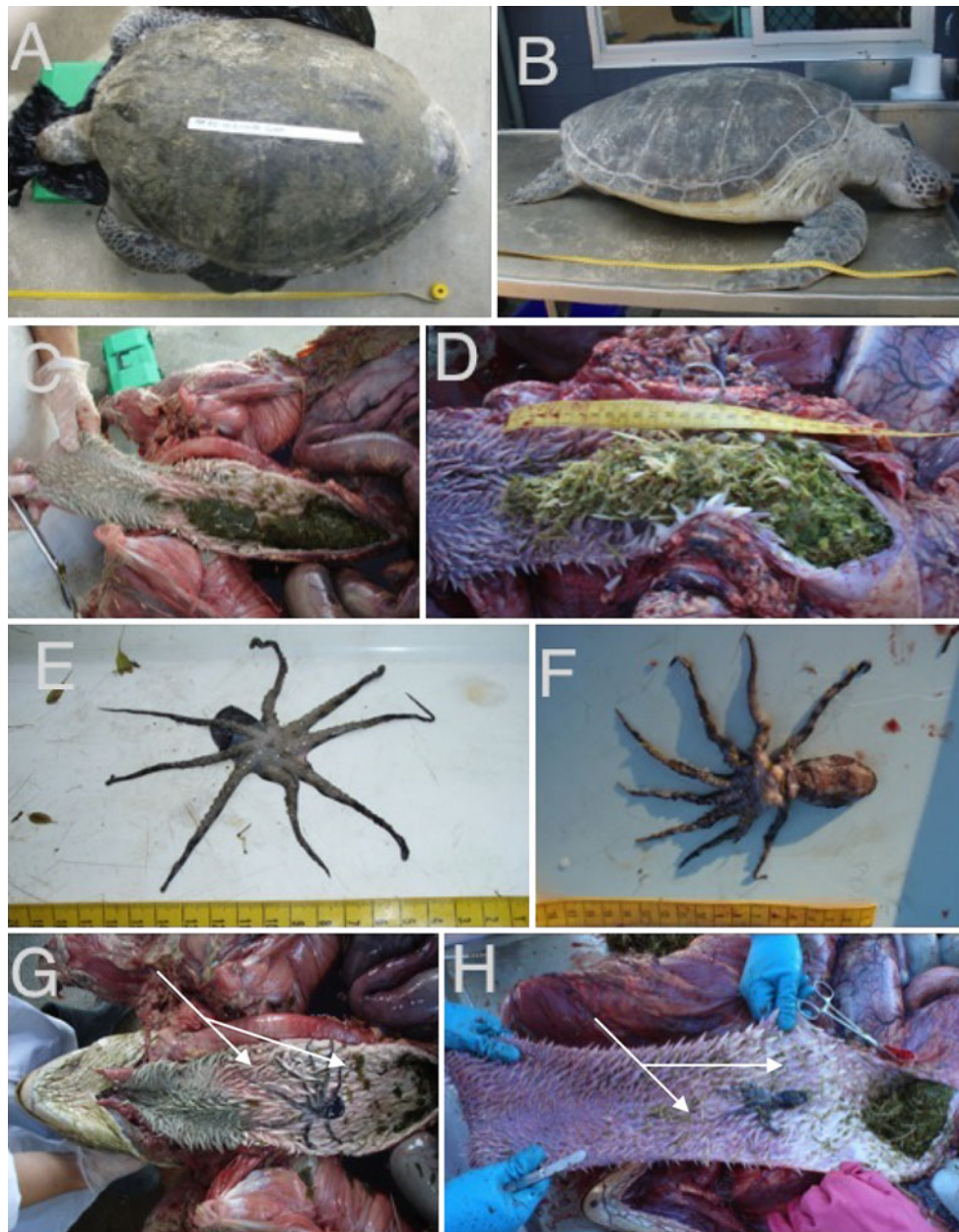
---

**Electronic supplementary material** The online version of this article (doi:10.1007/s00227-011-1846-9) contains supplementary material, which is available to authorized users.

---

K. A. Townsend (✉) · Q. A. Schuyler  
School of Biological Sciences, The University of Queensland,  
Moreton Bay Research Station, P.O. Box 138,  
Dunwich, QLD 4183, Australia  
e-mail: kathy.townsend@uq.edu.au

J. Altvater · M. C. Thomas · G. W. Nette  
Independent Marine Biochemistry Research,  
Moreton Bay Research Station, P.O. Box 138,  
Dunwich, QLD 4183, Australia



**Fig. 1** External and internal photographs of Green turtles (*Chelonia mydas*) 1 and 2 and associated blue-lined octopuses (*Haplochlana fasciata*). **a** Turtle 1 (97 cm curved carapace length (CCL)) showing the dorsal surface with a clean carapace and good body condition, **b** Turtle 2 (100.6 cm CCL) showing clean carapace and good body condition, **c** in situ bolus of *Halophila ovalis* seagrass containing blue-lined octopus *H. fasciata* (Turtle 1), **d** in situ bolus of *H. ovalis* seagrass containing blue-lined octopus (Turtle 2),

**e** ventral surface of 3.1 cm body length *H. fasciata* extracted from seagrass bolus (Turtle 1), showing 2 mm beak, **f** dorsal surface of 4.5 cm body length *H. fasciata* extracted from seagrass bolus (Turtle 2), **g** *H. fasciata* extracted from bolus of *H. ovalis* and returned to location found within the esophagus of Turtle 1, **h** *H. fasciata* extracted from bolus of *H. ovalis* and returned to location found within the esophagus of Turtle 2. Arrows highlight reddening of the esophagus where the octopuses were located

Williams et al. 2011), there is currently no empirical evidence that the octopuses can exude TTX from these tissues. Instead, envenomation is thought to occur through subcutaneous injection via a bite from its small, parrot-like beak (Edmonds 1969; Yotsu-Yamashita et al. 2007). Many case studies have described *Haplochlana* sp. envenomations in human beings (Edmonds 1969; Walker 1983; Williamson

1987; Edmonds 1989; Hodgson 1997; Cavazzoni et al. 2008), but to date, there have been no recorded incidents of an envenomation of a wild marine animal. This study presents the first morphological and biochemical evidence of mortality caused by the envenomation of two fully grown, sexually mature green turtles (*Chelonia mydas*) by two blue-lined octopuses (*Haplochlana fasciata*).

Complimentary to this report is the development of a new methodology utilizing multi-stage tandem mass spectrometry, which has allowed unequivocal determination of the presence of the TTX toxin within the samples tested.

## Methods and materials

As part of a larger study investigating turtle mortality within Moreton Bay, two large green turtles (*Chelonia mydas*) were found dead; Turtle 1 on a sand bank (S27°21'50" E153°25'6") on October 11, 2008, and Turtle 2 on North Stradbroke Island (S27°24'13" E153°26'12") on September 15, 2010, a distance of 4.7 km apart (and nearly 2 years). The animals were brought to Moreton Bay Research Station and necropsied via gross anatomical investigation. External and internal observations were recorded and photographed.

During the necropsy, samples were collected of the food bolus, liver, kidney, and muscle of the *C. mydas* specimens 1 and 2, and the enflamed tissue associated with the octopus within the esophagus in Turtle 2. Samples were stored frozen at  $-20^{\circ}\text{C}$ . The entire *H. fasciata* organism from each *C. mydas* was removed from the esophagus and maintained in 90% ethanol (Turtle 1) or placed in  $-80^{\circ}\text{C}$  freezer (Turtle 2).

The salivary glands of the *H. fasciata* specimens were subsequently extracted and all samples listed above (plus the liver from a third turtle that did not die from TTX) were analyzed for the presence of TTX using a unique multiple-stage mass spectrometry technique developed specifically for this study. This powerful technique utilizing HPLC–MS with hydrophilic interaction chromatography was chosen above single-stage mass spectrometry (SSMS). During SSMS, many other substances may elute off the column at the same retention time as TTX, making a negative control necessary (Matsumura 1995, 2001; Williams et al. 2004, 2011). To highlight the strength of this technique, we included a negative control, although it was unnecessary as

the technique provides unequivocal identification of TTX. While a summary of the procedure is below, a full description of the technique can be found in Online Resource 1.

Preliminary experiments on the identification of TTX centered on the detection of the expected  $[\text{M} + \text{H}]^{+}$  ion at  $m/z$  320 by LC–MS and monitoring the  $m/z$  320–302 transition by LC–MS/MS. Both methods lead to the detection of a range of isobaric ions complicating the identification of TTX. The  $m/z$  320–302 transition results from the neutral loss of water from the TTX  $[\text{M} + \text{H}]^{+}$  ion. The neutral loss of water is a common fragmentation process for many ions and is therefore not specific to TTX.

The fragmentation of the TTX  $[\text{M} + \text{H}]^{+}$  ion was studied using  $\text{MS}^n$  by ion trap mass spectrometry.  $\text{MS}^2$  and  $\text{MS}^3$  resulted primarily in the neutral loss of additional water from the precursor ions. Using  $\text{MS}^4$ , however, abundant fragment ions were observed at  $m/z$  162, 200, and 254 which were characteristic of the TTX  $[\text{M} + \text{H}]^{+}$  ion. The  $m/z$  200 fragment ion in the  $\text{MS}^4$  spectrum was used in the identification of TTX since it was the most abundant of these three fragment ions.

## Results

The two large dead green sea turtles (*Chelonia mydas*) appeared outwardly healthy, with no life threatening external injuries (Fig. 1a, b). Internal observations of both turtles revealed a large, healthy muscle mass (Table 1) and an extensive fat layer throughout the entire body, indicating death was sudden. In each case, the circulatory and urogenital systems presented normal. Water was found within the bronchi, and bright red, frothy oxygenated blood observed in both lungs. On investigation of the gastrointestinal tract (GI), large quantities of seagrass (*Halophila ovalis*) were found within the esophagus and stomach of each animal (Fig. 1c, d), while the rest of the GI was filled with progressively digested food through to the rectum.

**Table 1** Morphological measurements of the two sexually mature female green turtles (*Chelonia mydas*) and blue-lined octopus (*Hapalochlaena fasciata*) involved in this study

	Turtle I (KAT110920080086)	Turtle II (QAS150920100007)
Minimum over-curve carapace length (CCL) (cm)	97.0	100.6
Head width (cm)	11.3	12.97
Tail length (cm)	20.8	21.0
Plastron length (cm)	76.6	82.0
Pectoral muscle depth (cm)	$R = 2.2, L = 1.4$	$R = 2.3, L = 2.2$
Calculated mass (kg)*	106.6	118.6
Body length of blue-lined octopus (cm)	3.1	4.5
Body plus arm length of blue-lined octopus (cm)	10.9	12.2

Mass estimates are based on the mass-size function for female green turtles published by Limpus et al. (1994)

Linear regression used  $\log \text{wt (kg)} = 2.9297(\log \text{CCL (cm)}) - 3.7929$  ( $r^2 = 0.986$ ,  $\text{DF} = 1174$ ,  $p < 0.0005$ ) from Limpus et al. (1994)

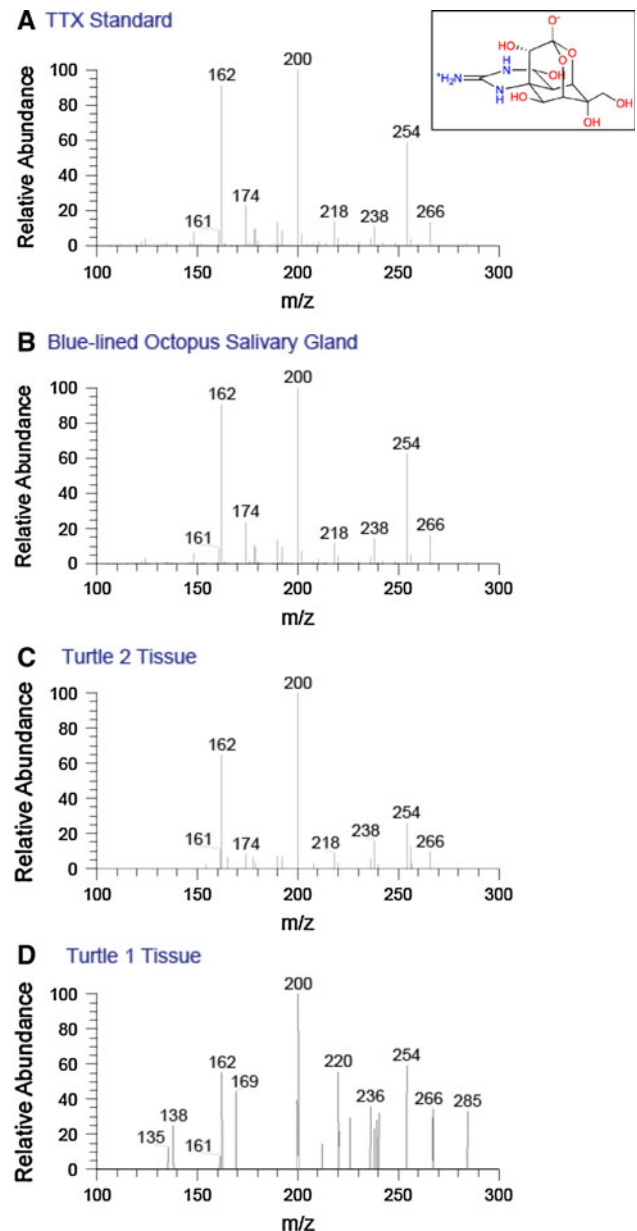
Both turtles exhibited the same symptoms. A closer inspection of the contents of the esophagus revealed a blue-lined octopus (*Hapalochlaena fasciata*) encased within the seagrass bolus in each of the two turtles (Fig. 1e, f). Morphometric measurements of the turtles and the octopuses are outlined in Table 1. The mouthparts of both blue-lined octopuses were approximately 2 mm in diameter (Fig. 1e). The esophageal tissue directly surrounding the octopus was red and inflamed in both cases (Fig. 1g, h), suggesting that these were the sites of envenomation, although no obvious bite marks could be found among the keratinized papillae.

Through comparison to the TTX standard (Fig. 2a), MS<sup>4</sup> fragment ions were observed at m/z 162, 200, and 254 in the salivary glands of the octopus (Fig. 2b) and tissues of both turtles (Fig. 2c, d), which were characteristic of the TTX [M + H]<sup>+</sup> ion (Fig. 2 insert).

MS<sup>4</sup> m/z 200.2 fragmentation chromatogram for the TTX standard indicated that the distinctive peak was found between 8 and 12 min (9.7 min) (Fig. 3a). For ease of display, we narrowed the remaining chromatograms to this region (Fig. 3b). Note also the different scales on the y-axis for each sub-figure, which is a reflection of the relative abundance of the TTX in each sample. Distinctive peaks were found in the turtle muscle, esophagus, and kidney (Fig. 3c–e), and in the salivary gland of the octopus (Fig. 3f). All of these had a signal to noise ratios (SN) of above 3. However, TTX was below detectable levels in the food bolus and the liver tissues of the Turtle 2 and 3 (Fig. 3g–i). While peaks appear to be present around the 9.8 and 9.6 min mark of Fig. 3g, h, respectively, these were at such low concentrations, and missing distinctive ion signatures that they are considered to be background noise. This was further confirmed by the analysis of the SN, for these tissues were at not detectable levels. A summary of positive TTX detections from both case studies can be found in Table 2.

## Discussion

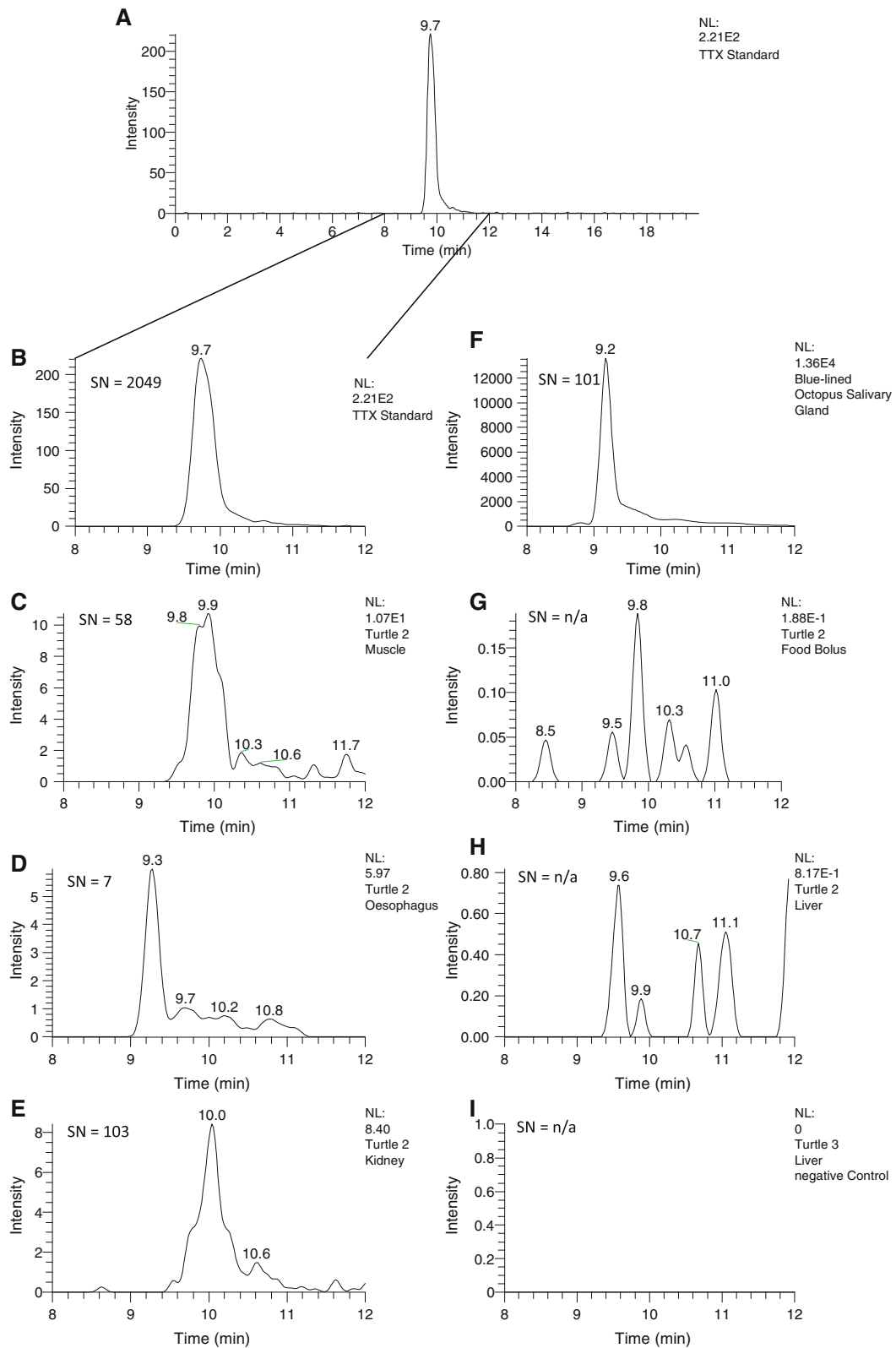
Green turtles (*C. mydas*) are herbivorous, feeding mainly on seagrass, macroalgae, and mangrove fruits (Brand-Gardner et al. 1999; Arthur et al. 2008) while supplementing their diet with gelatinous organisms (Arthur et al. 2007). The species feeds while submerged and can breath hold for up to 3 h while foraging, before returning to the surface to breathe (Lutz and Bentley 1985; Arthur et al. 2007). Of the six species of seagrass found within the sheltered waters of Moreton Bay, *Halophila ovalis* is the preferred food source for *C. mydas* due to its nutritional qualities (Brand-Gardner et al. 1999). Submerged meadows of *H. ovalis* are very common on the sand banks surrounding the area where the turtles in this study were found (Zharikov et al. 2005; Phinn



**Fig. 2** MS<sup>4</sup> fragment spectrum of (from top to bottom) **a** TTX Standard and TTX molecule structure (insert top right); **b** Blue-lined octopus salivary gland; **c** Turtle 2 esophagus and **d** Turtle 1 muscle tissues showing peaks consistent with the presence of TTX

et al. 2008). Large quantities of *H. ovalis* throughout the gastrointestinal tracts of the sea turtles indicated that the animals had had long-term access to a high-quality food source and were feeding within the sheltered waters of Moreton Bay prior to their death. As the octopuses in both instances were completely encased within a seagrass bolus (Fig. 1c, d), it is proposed that the ingestion was accidental, with the turtles consuming the visually cryptic animals during the grazing process.

While there was a distinct reddening of the esophagus in the area in which the octopuses were located, (Fig. 1g, h) no



**Fig. 3** **a** Extracted ion chromatogram ( $m/z = 200.2$ ) of TTX standard across the full 20 min run. The remaining chromatograms are highlighted between 8 and 12 min, **b** TTX standard, **c** muscle (Turtle 2), **d** esophagus (Turtle 2), **e** kidney (Turtle 2), **f** octopus salivary gland (found in Turtle 2 esophagus), **g** food bolus (Turtle 2), **h** liver (Turtle 2), and **i** negative con-

trol (liver from Turtle 3) and their associated signal to noise ratios (SN). SN values less than 3 are considered to be noise and indicate that the TTX is below detectable levels, while n/a indicates undetectable levels. Note also the different scales on the y-axis and NL values for each sub figure, which are a reflection of the relative abundance of the TTX in each sample

**Table 2** Presence and absence of TTX from samples sourced from stranded green sea turtles and associated blue-lined octopus

Animal	Tissue sampled					
	Liver	Muscle	Kidney	Esophagus	Salivary gland	Food bolus
Turtle I	–	+	+	#	n.a.	–
Turtle II	–	+	+	+	n.a.	#
Blue-lined octopus I	#	#	#	#	+	n.a.
Blue-lined octopus II	#	#	#	#	+	n.a.

(–) TTX undetectable, (+) TTX detected, # not analyzed, n.a. not applicable

distinct bite marks could be found. Other studies have shown that the bite leaves little mechanical or pharmacological skin trace locally, although reddening and swelling of the envenomation site is common (Edmonds 1969, 1989; Williamson 1987; Cavazzoni et al. 2008). The lack of distinct puncture marks may also be an indication that the octopus may not have bitten the inner tissue of the esophagus; instead, toxins may have been leached from the dermis of *H. fasciata*, as proposed by Yotsu-Yamashita et al. (2007). However, while TTX has been detected in high levels in multiple regions of the octopus body (Yotsu-Yamashita et al. 2007; Williams and Caldwell 2009; Williams et al. 2011), it has been shown that the consumption of tissue is fifty times less toxic relative to intraperitoneal injection (Xu et al. 2003). The lack of detectable TTX in the seagrass bolus in which the octopus was fully encased further indicates that the TTX detected in the turtle tissues came from the octopus via active envenomation, not exudation.

There is no anti-venom currently available for TTX (Anonamous 2003, Xu et al. 2003); however, human case studies have shown that patients that are ventilated mechanically often recover (Edmonds 1969; Walker 1983; Williamson 1987). There are two proposed mechanisms for the removal of TTX from the body. Unlike protein-based neurotoxins, it is thought that TTX is not broken down and is excreted unchanged by vertebrates (Kao 1966). However, others have hypothesized that the toxin is broken down in the body, presumably via the liver—although there is currently no empirical evidence that this is the case (Edmonds 1969; Walker 1983; Williamson 1987). This hypothesized role of the liver in degrading TTX is supported by the lack of detectable levels of the toxin within both liver samples from this study (Table 2).

TTX disrupts sodium channels causing nerve conduction failure, particularly in the somatic motor nerves (Narahash et al. 1966, 1967). Human case studies have shown that flaccid muscle paralysis occurs soon after bite, with the patients remaining conscious even after paralysis has occurred. Dose-dependent respiratory weakness or failure occurs spontaneously some time later (Williamson 1987; Edmonds 1989; Cavazzoni et al. 2008). Necropsy evidence

from the cases in this study indicates that similar symptoms may have affected the turtles. Saltwater drowning is diagnosed in reptiles by a bloody froth in the airways, while fluid, sometimes together with plant and other material, is likely to be present in the upper alimentary tract (Cooper 2008). Water in the bronchi and bright red, frothy oxygenated blood were found within the lungs of both turtles, indicating that the animals were in the water when the bite occurred, and subsequently drowned. The large amount of fresh seagrass in the esophagus and stomach suggests that they were most probably feeding. The subsequent flaccid paralysis likely disabled their ability to swim and lift their heads out of the water to breathe, causing the animals to take water into the lungs.

This is the first evidence of the antipredator function of TTX. While omnivorous green turtle hatchlings have been observed attempting to feed on small, non-venomous octopuses, *Octopus bocki* (Caldwell 2005), we propose that these are two cases of healthy, adult herbivorous green sea turtles (*C. mydas*) accidentally consuming cryptic blue-lined octopuses (*H. fasciata*) while feeding on the seagrass meadows in which the octopus shelters. These accidental ingestions resulted in lethal TTX envenomations by the blue-lined octopuses, delivered actively through biting the esophageal tissue. The TTX subsequently immobilized the turtle, preventing it from raising its head above the water to breathe, filling its lungs with water and resulting in a toxin-induced drowning. As these two animals were sourced from 100 necropsied turtles, death by blue-lined octopus envenomation may be a previously unconsidered threat to grazing within seagrass beds.

**Acknowledgments** This project was supported by the Goldring Emerging Marine Scientist Fellowship, Earthwatch Institute of Australia, Underwater World Mooloolaba, Quandamooka Land and Sea Council, The Goodman Foundation, and Moreton Bay Marine Park Authority. Thanks also go to T. Gallagher, Z. Allen, C. Mueller, E. Lewis, D. Burns and to the staff at Moreton Bay Research Station.

**Open Access** This article is distributed under the terms of the Creative Commons Attribution Noncommercial License which permits any noncommercial use, distribution, and reproduction in any medium, provided the original author(s) and source are credited.

## References

- Anonamous (2003) Australian Venom Research Unit—blue-ringed octopus. The University of Melbourne, Melbourne. [http://www.avru.org/health/health\\_bluering.html](http://www.avru.org/health/health_bluering.html). Accessed 9 Nov 2011
- Arthur KE, O’Neil JM, Limpus CJ, Abernathy K, Marshall G (2007) Using animal-borne imaging to assess green turtle (*Chelonia mydas*) foraging ecology in Moreton Bay, Australia. *Marine Technol Soc J* 41:9–13
- Arthur KE, Boyle MC, Limpus CJ (2008) Ontogenetic changes in diet and habitat use in green sea turtle (*Chelonia mydas*) life history. *Marine Ecol Prog Ser* 362:303–311
- Brand-Gardner SJ, Lanyon JM, Limpus CJ (1999) Diet selection by immature green turtles, *Chelonia mydas*, in subtropical Moreton Bay, south-east Queensland. *Aust J Zool* 47:181–191
- Caldwell RL (2005) An observation of inking behavior protecting adult Octopus bocki from predation by green turtle (*Chelonia mydas*) hatchlings. *Pac Sci* 59:69–72
- Cavazzoni E, Lister B, Sargent P, Schibler A (2008) Blue-ringed octopus (*Hapalochlaena* sp.) envenomation of a 4-year-old boy: a case report. *Clin Toxicol* 46:760–761
- Cooper JE (2008) Methods in herpetological forensic work—post-mortem techniques. *Appl Herpetol* 5:351–370
- Davie P (1998) Wild guide to moreton bay. Queensland Museum, Brisbane, p 408
- Edmonds C (1969) A non-fatal case of blue-ringed octopus bite. *Med J Aust* 2:601
- Edmonds C (1989) Case report blue-ringed octopus bite Dangerous Marine Creatures. Reed Books, Frenchs Forest, pp 100–101
- Hodgson WC (1997) Pharmacological action of Australian animal venoms. *Clin Exp Pharmacol Physiol* 24:10–17
- Kao CY (1966) Tetrodotoxin, saxitoxin, and their significance in the study of excitation phenomena. *Pharmacol Rev* 18:997–1049
- Limpus CJ, Couper PJ, Read MA (1994) The green turtle, *Chelonia mydas*, in Queensland: population structure in a warm temperate feeding area. *Mem Qld Museum* 35:139–154
- Lutz PL, Bentley TB (1985) Respiratory physiology of diving in the sea turtle. *Copeia* 3:671–679
- Mathger LM, Denton EJ, Marshall NJ, Hanlon RT (2008) Mechanisms and behavioural functions of structural coloration in cephalopods conference on Iridescence—more than meets the eye, Tempe, AZ, pp S149–S163
- Matsumura K (1995) Re-examination of tetrodotoxin production by bacteria. *Appl Environ Microbiol* 61:3468–3470
- Matsumura K (2001) No ability to produce tetrodotoxin in bacteria. *Appl Environ Microbiol* 67:2393–2394
- Narahash T, Moore JW, Poston RN (1966) Specific action of tetrodotoxin on nerves. *Science* 154:425
- Narahashi T, Moore JW, Poston RN (1967) Tetrodotoxin derivatives: chemical structure and blockage of nerve membrane conductance. *Science* 156:976–979
- Norman M, Reid A (2000) A guide to squid, cuttlefish and octopuses of Australia. CSIRO Publishing, Moorabbin
- Phinn S, Roelfsema C, Dekker A, Brando V, Anstee J (2008) Mapping seagrass species, cover and biomass in shallow waters: An assessment of satellite multi-spectral and airborne hyper-spectral imaging systems in Moreton Bay (Australia). *Remote Sens Environ* 112:3413–3425
- Sutherland SK (1983) Australian animal toxins: the creature, their toxins and the care of the poisoned patient. Oxford University Press, Melbourne
- Tranter DJ, Augustin O (1973) Observations on life-history of blue-ringed octopus *Hapalochlaena-maculosa*. *Mar Biol* 18:115–128
- Walker DG (1983) Survival after severe envenomation by the blue-ringed octopus (*Hapalochlaena maculosa*). *Med J Aust* 2:663–665
- Weng HT (1990) Fish in Shallow Areas in Moreton Bay, Queensland and factors affecting their distribution. *Estuar Coast Shelf Sci* 30:569–578
- Williams BL, Caldwell RL (2009) Intra-organismal distribution of tetrodotoxin in two species of blue-ringed octopuses (*Hapalochlaena fasciata* and *H. lunulata*). *Toxicon* 54:345–353
- Williams BL, Brodie ED Jr, Brodie ED III (2004) Chemical ecology of a resistant predator and its toxic prey: distribution of tetrodotoxin in the common garter snake after ingestion of the rough-skinned newt. *J Chem Ecol* 30:1901–1919
- Williams BL, Lovenburg V, Huffard CL, Caldwell RL (2011) Chemical defense in pelagic octopus paralarvae: Tetrodotoxin alone does not protect individual paralarvae of the greater blue-ringed octopus (*Hapalochlaena lunulata*) from common reef predators. *Chemoecology* 21:131–141
- Williamson JAH (1987) The blue-ringed octopus bite and envenomation syndrome. *Clin Dermatol* 5:127–133
- Xu Q, Huang K, Gao L, Zhang H, Rong K (2003) Toxicity of tetrodotoxin towards mice and rabbits. *Wei sheng yan jiu*. *J Hyg Res* 32:371–374
- Yotsu-Yamashita M, Mebs D, Flachsenberger W (2007) Distribution of tetrodotoxin in the body of the blue-ringed octopus (*Hapalochlaena maculosa*). *Toxicon* 49:410–412
- Zharikov Y, Skilleter GA, Loneragan NR, Taranto T, Cameron BE (2005) Mapping and characterising subtropical estuarine landscapes using aerial photography and GIS for potential application in wildlife conservation and management. *Biol Conserv* 125:87–100