Anesthesia for insertion of a Dumon stent in a patient with a large tracheo-esophageal fistula

Takefumi Inada MD,*
Masao Umemoto MD,†
Taichi Ohshima MD,‡
Osamu Sawada MD,†
You-saku Nakamura MD†

Purpose: To present the anesthetic management for the insertion of a Dumon silicon stent to the trachea of a patient with a large tracheo-esophageal fistula. The aim of the stent insertion was to seal the fistula in order to prevent aspiration of esophageal content and subsequent pneumonitis.

Clinical features: A 45-yr-old man with a large tracheo-esophageal fistula was scheduled for the insertion of the Dumon stent. Since placement of the stent necessitates the insertion of a rigid bronchoscope, under general anesthesia, with its tip just proximal to the fistula, controlled ventilation was expected to be difficult to achieve because of the diversion of oxygen through the large fistula to the esophagus. We successfully ventilated the lungs, after the fistula was sealed using a large balloon which was inserted in the esophagus, and the stent insertion was completed uneventfully.

Conclusion: Anesthesia for procedures involving the central airway is challenging. This report describes a simple and practical method to facilitate ventilation by temporary seal of a tracheo-esophageal fistula using a modified esophageal balloon.

Objectif : Présenter l'anesthésie utilisée pendant l'insertion d'un tuteur au silicone Dumon dans la trachée d'un patient pour fermer une importante fistule trachéo-œsophagienne et ainsi empêcher une aspiration du contenu œsophagien et une pneumopathie consécutive.

Éléments cliniques : Un homme de 45 ans qui présentait une grande fistule trachéo-œsophagienne a été admis pour l'insertion d'un tuteur Dumon. Comme sa mise en place nécessite l'insertion, sous anesthésie générale, d'un broncoscope rigide dont la pointe est introduite tout près de la fistule, nous nous attendions à ce que la ventilation contrôlée soit difficile à cause de la possibilité pour l'oxygène de passer dans l'oesophage. Nous avons réussi la ventilation après la fermeture de la fistule en utilisant un gros ballon que nous avons inséré dans l'œsophage, et l'insertion du tuteur a été réalisée sans incident.

Conclusion : C'est un défi de procéder à l'anesthésie lors d'interventions aux voies aériennes centrales. Le présent article décrit une méthode simple et pratique de faciliter la ventilation en fermant temporairement une fistule trachéo-œsophagienne avec un ballon œsophagien modifié.

From the Departments of Anaesthesia,* Radiology,‡ and Surgery,† Tsuda Hospital, Tsuda Kita-machi, 3 cho- me 30-1, Hirakata-city, Osaka 573-0121, Japan.

Address correspondence to: Dr. Takefumi Inada, Department of Anesthesiology, Kansai Medical University Hospital, 10-15 Fumizono-cho, Moriguchi, Osaka, 570-8507, Japan. Phone: 81-6-992-1001; Fax: 81-6-991-1301.

Accepted for Publication, January 20, 1999

ANESTHESIA for procedures involving the tracheo-bronchial tree is challenging to anesthesiologists. We were required to provide anesthesia for the insertion of a Dumon silicon stent (Endoxane prosthesis, Axion, Aubagne, France) (Figure 1)[1] into the trachea of a patient with a large tracheo-esophageal fistula. The purpose of the stent insertion was to seal the fistula for the prevention of aspiration through the fistula and aspiration pneumonitis. Placement of the stent necessitates insertion of a dedicated rigid bronchoscope (Dumon-Harrell bronchoscope) (EFER, La Ciotat, France) (Figure 1) with its tip just proximal to the fistula.[1,2] Although the bronchoscope has a port for ventilation, the establishment of controlled ventilation was expected to be compromised, because oxygen delivered through the bronchoscope would mostly be diverted through the large fistula to the esophagus, instead of to the lungs. Our strategy was to seal the tracheo-esophageal fistula from the esophageal site with a large balloon (length 15 cm, diameter when inflated 8 cm) attached to the tip of a nasogastric tube (Figure 2).



FIGURE 1 Dumon-Harrell bronchoscope (which consists of an open tube and a telescope) (1), Dumon silicone stent (2), hockey-puck-shaped funnel loader (3), stent introducer tube (4), and stent pusher (5). To place the Dumon silicone stent, the stent is rolled and packed into the stent introducer tube through a hockey-puck-shaped funnel loader. After withdrawing the telescope, the stent introducer tube is passed down the open tube of the Dumon-Harrell bronchoscope. The stent pusher is used to push the stent out into the trachea.[1]

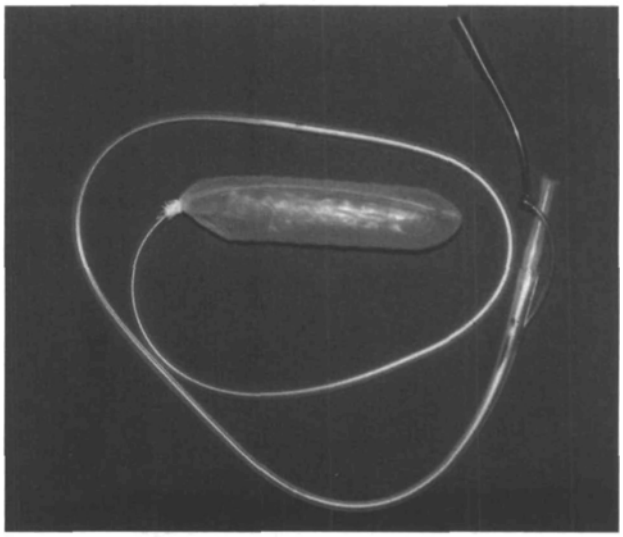

FIGURE 2 Balloon used to seal the tracheo-esophageal fistula from the esophagus, attached to the tip of a 16 Fr nasogastric tube. Air is introduced into, or removed from the balloon through the lumen of the nasogastric tube.

Case report

A 45-yr-old man (50 kg, 162 cm) was admitted to hospital for acute pneumonia. He had a history of an esophageal foreign body (a coin) at two years old, which was removed through a neck incision. During the year following the surgery, he began to cough upon ingestion of both liquid and solid materials. He had to swallow a small amount at a time with the upper part of the body leaning slightly backwards to minimize coughing. He had suffered several episodes of aspiration pneumonitis since then. At presentation, chest X-ray showed a damaged left lung, and diffuse infiltration in the right lung, indicating pneumonia. Fibreoptic bronchoscopy revealed a tracheo-esophageal fistula (10 x 20 mm in diameter) at the mid-trachea, in which a posterior membranous portion of the trachea communicated directly with the esophagus (Figure 3). Fibrescopy of the upper digestive tract showed that the fistula was 23 - 25 cm from the upper incisors and the esophagus was dilated as large as 4 cm in diameter at the level of the fistula. At the time of anesthesia, the pneumonia was cured without any dyspnea.

Atropine 0.5 mg and hydroxyzine hydrochloride 50 mg *im* were given as premedication. Monitoring included an electrocardiograph, a non-invasive blood pressure cuff, and a pulse oximeter. With infusion of propofol 6 $mg \cdot kg^{-1} \cdot hr^{-1}$, a 16 Fr nasogastric tube (Nipro Double-lumen tube NDL-16, Nipro, Japan), equipped with a balloon (Echo-probe cover, Utsunomiya, Japan) (Figure 2), was inserted through the left naris into the esophagus. Then, with sufficient lidocaine topical anesthesia and with propofol sedation (6 $mg \cdot kg^{-1} \cdot hr^{-1}$), fibreoptic bronchoscopy was performed. During both bronchoscopy and fluo-

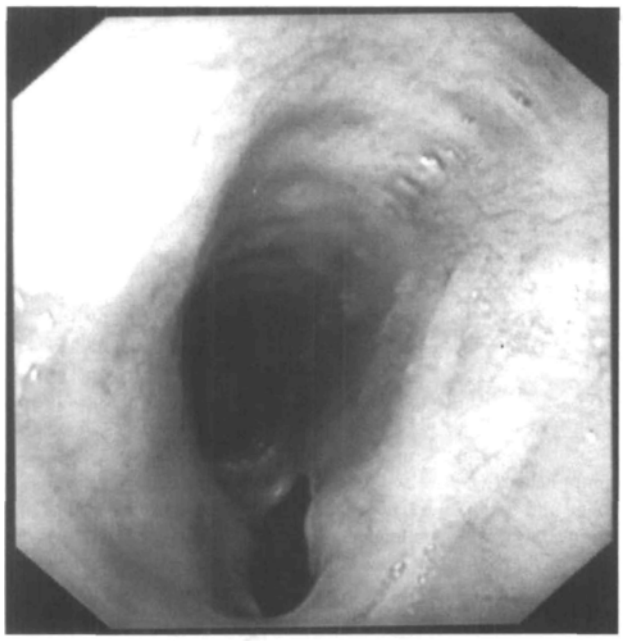

FIGURE 3 Bronchoscopic view of the trachea.

roscopy, the balloon was inflated with air and iodine solution, and the position of the balloon was adjusted to seal the fistula (Figure 4). Anesthesia was then induced with 3 $mg \cdot kg^{-1}$ propofol *iv*: ventilation *via* a mask was effective. Then, 1 $mg \cdot kg^{-1}$ succinylcholine was given and the trachea was intubated with an endotracheal tube. Anesthesia was maintained with propofol 7 - 8 $mg \cdot kg^{-1} \cdot hr^{-1}$ (with bolus administrations of 20-30 mg propofol *iv* as necessary) and oxygen 100%. Manual ventilation of the lungs was effective without distension of the stomach, and 5 mg vecuronium *iv* was given. The patient was positioned with the neck extended for insertion of the rigid bronchoscope (Figure 1). The endotracheal tube was removed and an attempt was made to place the rigid bronchoscope so that its tip was proximal to the fistula, which was unsuccessful. The bronchoscope was removed. After ventilation *via* a mask, placement of the bronchoscope was repeated successfully. Ventilation of the lungs was provided *via* the ventilation port of the bronchoscope. The Dumon silicon stent (Endoxane TD 16 L 40 ORX) (length 40 mm, outer diameter 16 mm) (Figure 1) was placed in the trachea through the bronchoscope using a dedicated stent introducer tube and a stent pusher (Figure 1).[1,2] The stent placement in the trachea was then adjusted with an alligator forceps to seal the fistula snugly. Throughout most of the procedure, the hemodynamics were stable and pulse oximetry readings were ≥ 98%. However, the oxygen

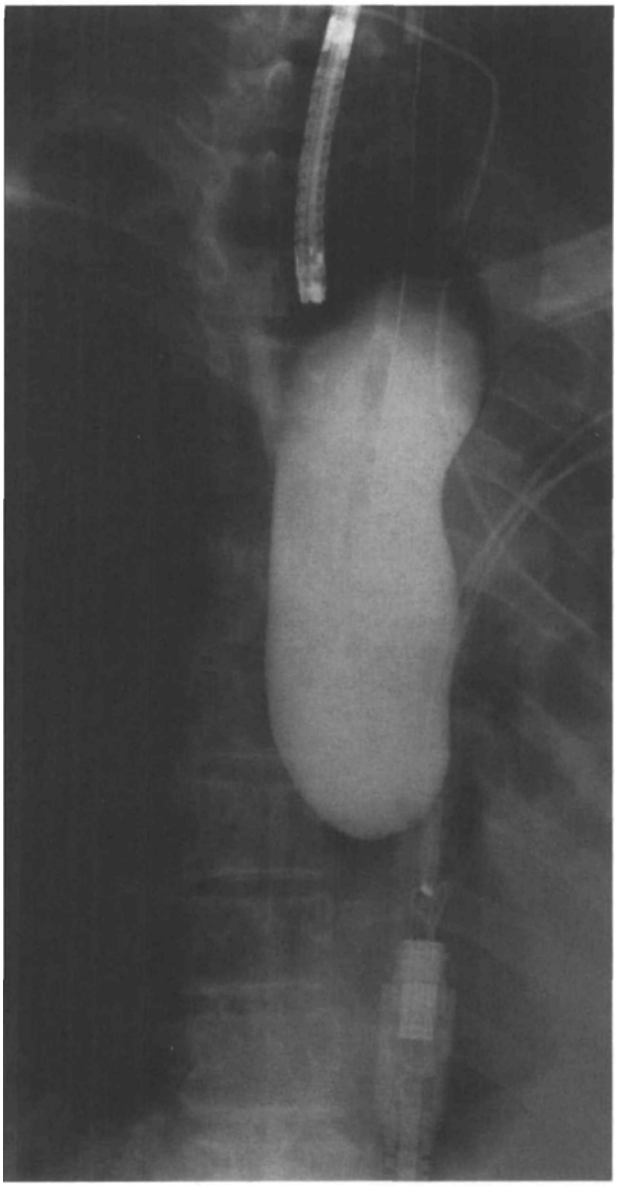

FIGURE 4 The X-ray shows that the balloon inserted in the esophagus, inflated with air and iodine solution, sealing the fistula. The position of the balloon was also confirmed by fibreoptic bronchoscopy.

saturation decreased temporarily to 80% at the times of the insertions of the rigid bronchoscope and of the insertion of the stent transducer tube for stent placement, into the bronchoscope (because the ventilation port is obstructed by the stent introducer tube). Otherwise, ventilation *via* the ventilation port of the bronchoscope was adequate (assessed by the movements of the chest and by the presence of breath sounds during manual compression of the reservoir

bag). After the successful stent insertion, the rigid bronchoscope was removed and ventilation *via* a mask was performed. Muscle relaxation was antagonized with 1 mg atropine and 2 mg neostigmine *iv*. After spontaneous respiration became appropriate, the balloon was deflated and removed, and propofol infusion was discontinued. Emergence from anesthesia was smooth and the postoperative course was uneventful. The prevention of the cough upon ingestion was successful and no aspiration pneumonitis developed to date (about five months after the procedure).

Discussion

In the present case, we were challenged to provide anesthesia for insertion of a Dumon stent to seal a large tracheo-esophageal fistula. Since intubation of the stent necessitates the insertion of a rigid bronchoscope with its tip just proximal to the fistula,[1,2] controlled ventilation through the bronchoscope was expected to be inadequate because oxygen would divert through the fistula into the stomach, instead of the lungs. The expected difficulty of ventilation was solved by successfully sealing the fistula from the esophageal site with a large balloon attached to a nasogastric tube. The method of sealing the fistula may be similar to a previously reported method,[3] in which a Fogarty balloon catheter was used in an infant with a tracheo-esophageal fistula for temporary occlusion of the distal esophagus for preventing air entry from the trachea to the stomach. Insertion of an esophageal stent under sedation and topical anesthesia to prevent esophago-tracheal reflux, was not planned because the esophagus was severely dilated, thus making the stenting of the esophagus impossible.

There may be alternative means of providing effective ventilation or oxygenation in such a case. Employing spontaneous ventilation, perhaps preceded by topical anesthesia of the airways, as some experts have recommended in the management of tracheo-esophageal fistulae,[4,5] may be an option. However, we felt that this may be difficult, if not impossible because of the following reasons. Stimulation produced by the rigid bronchoscope is so intense that it is rarely possible to have a spontaneously breathing patient sufficiently anesthetized to tolerate the bronchoscope without compromising oxygenation. We also assumed that the paralyzed patient is much more amenable to the insertion of the bronchoscope due to the resultant relaxed upper airway.

Other methods include partial cardiopulmonary bypass[6] or high frequency positive pressure ventilation.[7] However, the former may both necessitate expensive equipment and be associated with increased cost; the latter may require the special equipment, which may obstruct the surgical field since such ventilation necessitates a catheter tip for ventilation distal (carinal side) to the fistula.

The Dumon stent has been used exclusively for palliative treatment in tracheo-bronchial obstruction.[1,2,8] The use of the stent to seal a tracheo-esophageal fistula is unusual. Radical surgery involving tracheoplasty and esophageal reconstruction may have been an option, but was not performed because the patient refused such treatment.

References

1 *Dumon J-F.* A dedicated tracheobronchial stent. Chest 1990; 97: 328–32.

2 *Abdullah V, Yim APC, Wormald PJ, van Hasselt CA.* Dumon silicone stents in obstructive tracheobronchial lesions: the Hong Kong experience. Otolaryngol Head Neck Surg 1998; 118: 256–60.

3 *Filston HC, Chitwood WR Jr, Schkolne B, Blackmon LR.* The Fogarty balloon catheter as an aid to management of the infant with esophageal atresia and tracheoesophageal fistula complicated by severe RDS or pneumonia. J Pediatr Surg 1982; 17: 149–51.

4 *Berry FA.* Neonatal anesthesia. *In:* Barash PG, Cullen BF, Stoelting RK (Eds.). Clinical Anesthesia, 3rd ed. Philadelphia: Lippincott-Raven, 1997: 1091–114.

5 *Yaster M.* Anesthesia for surgical emergencies in newborns. *In:* Longnecker DE, Tinker JH, Morgan GE Jr. (Eds.). Principles and Practice of Anesthesiology, 2nd ed. St. Louis: Mosby, 1998: 2058–78.

6 *Niwa H, Masaoka A, Yamakawa Y, Fukai I, Kiriyama M, Shindou J.* Esophageal tracheobronchoplasty for membranous laceration caused by insertion of dumon stent maintenance of oxygenation by percutaneous cardiopulmonary support. Eur J Cardiothorac Surg 1995; 9: 213–5.

7 *Eriksson I, Nilsson L-G, Nordström S, Sjöstrand U.* High-frequency positive-pressure ventilation (HFPPV) during transthoracic resection of tracheal stenosis and during peroperative bronchoscopic examination. Acta Anaesthesiol Scand 1975; 19: 113–9.

8 *Bolliger CT, Probst R, Tschopp K, Solèr M, Perruchoud AP.* Silicone stents in the management of inoperable tracheobronchial stenoses. Indications and limitations. Chest 1993; 104: 1653–9.