REGIONAL ANAESTHESIA FOR THE FOOT

R McCutcheon, M D *

Introduction

Lesions of the foot are frequently presented for anaesthesia in the Casualty Department at Lagos University Teaching Hospital General anaesthesia carries a considerable risk due to the possibility of a full stomach, so regional techniques are ideal Intravenous regional anaesthesia, popular at this hospital,[1] may be technically difficult in the lower limb Epidural and spinal blocks are undesirable outside the sterile environment of the main theatre while sciatic and femoral nerve blocks may be cumbersome, unpleasant, and incapacitating for the patient We therefore considered blocks closer to the foot, particularly at the ankle

The literature available to us, with the exception of a few paragraphs in Lee,[2] was especially scanty on the subject. The nerve distribution of the foot was purported to be so variable that in many instances blocks said to be properly performed were incomplete Furthermore, the first few ankle blocks we casually attempted were not greatly successful In order to improve the technique we instituted the following study

1 The exact courses of nerves supplying the foot, and their areas of innervation, were mapped out

2 These nerves were blocked in a series of 100 cases, and the results were recorded

3 The areas of analgesia were compared with the text-book picture of the sensory supply of the foot

Anatomy

Current textbooks of anatomy[3-5] were consulted and the dissection laboratory visited to provide a basis for a detailed outline of the nerve supply to the foot In general terms, the nerve supply can be described as follows The sole of the foot is innervated by the posterior tibial nerve The dorsum of the foot is innervated by the lateral popliteal nerve The lateral part of the foot is innervated by the sural nerve Part of the medial side of the foot is innervated by the saphenous nerve

Posterior tibial nerve (Fig 1)

The posterior tibial nerve is a continuation of the medial popliteal nerve (tibial nerve) It passes through the posterior compartment of the leg, deep to the superficial calf muscles, between the tibialis posterior and the flexor digitorum longus, and beside the posterior tibial artery In the lower leg it rests on the posterior

*Department of Anaesthesia, Lagos University Teaching Hospital, Lagos, Nigeria

surface of the tibia It passes deep to the flexor retinaculum behind the medial malleolus to divide into the lateral and medial plantar nerves One branch the medial calcanean nerve comes off just above this division pierces the retinaculum and descends superficially to supply the lower surface and part of the posterior surface of the heel

The medial plantar nerve supplies the medial two-thirds of the sole and the plantar half of the medial three and one-half toes (up to the nail) while the lateral division supplies the lateral third of the sole and plantar half of the lateral one and one half toes

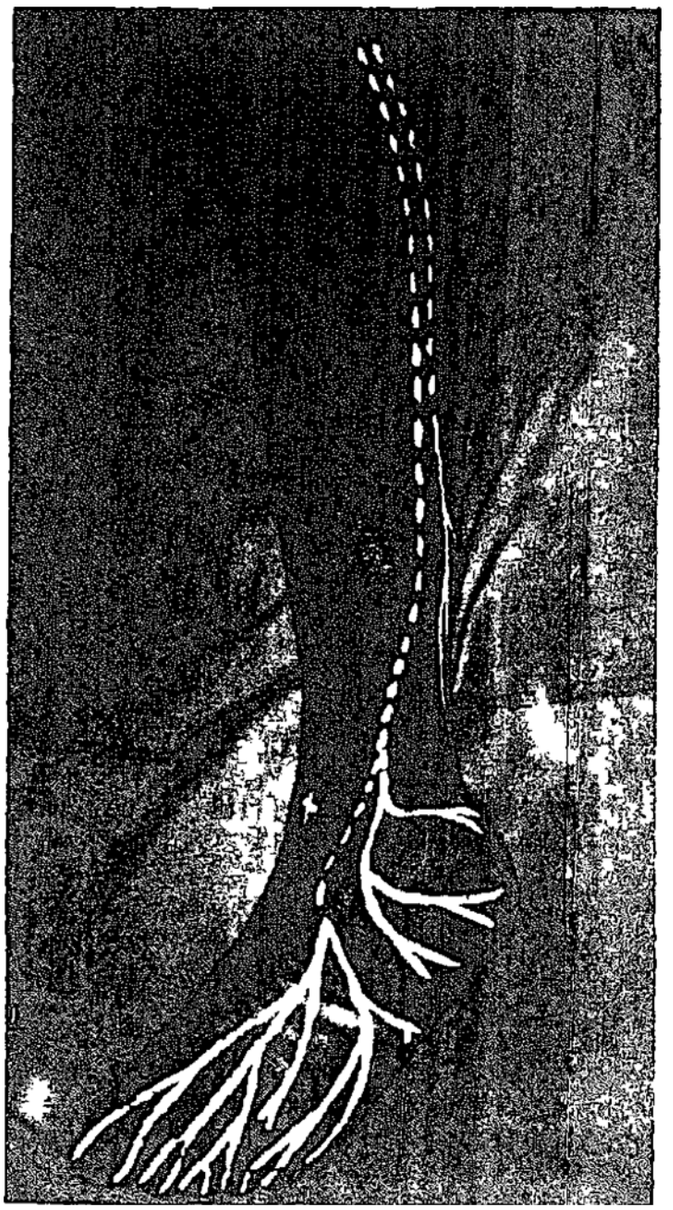

FIGURE 1 Course of posterior tibial nerve Broken line = deep course solid line = superficial course X indicates medial and lateral malleoli

Lateral popliteal nerve (common peroneal nerve) (Fig 2)

This smaller branch of the sciatic nerve passes through the popliteal fossa to the neck of the fibula where it divides into the musculo cutaneous nerve (superficial peroneal nerve) and the anterior tibial nerve (deep peroneal nerve) There

are two branches of the lateral popliteal nerve prior to division the sural communicating nerve which joins the sural nerve and the lateral cutaneous nerve of the calf which supplies the upper two thirds of the antero lateral aspect of the leg

The musculo cutaneous nerve passes from the neck of the fibula down between the peroneus longus and brevis then anterior to the brevis to pierce the deep fascia one third of the way up the leg above the lateral malleolus Almost immediately it divides into lateral and medial branches which cross the ankle anteriorly in the subcutaneous tissue The musculo cutaneous nerve supplies the lower antero lateral aspect of the leg the dorsum of the foot and the dorsal half of all the toes except those parts supplied by the anterior tibial and sural nerves

The anterior tibial nerve passes through the inter muscular septum into the anterior compartment of the leg and descends with the anterior tibial artery in front of the interosseus membrane It crosses the anterior ankle approximately midway between the malleoli with two tendons the tibialis anterior and the extensor hallucis longus medially and one tendon the extensor digitorum



FIGURE 2 Course of musculo cutaneous and anterior tibial nerves

longus laterally It usually lies lateral to the artery beneath the inferior extensor retinaculum The anterior tibial nerve supplies only the skin of adjacent areas of the first and second toes

Sural nerve (Fig 3)

This interesting nerve is a branch of the medial popliteal nerve in the popliteal fossa It courses between the heads of the gastrocnemius and pierces the deep fascia to become superficial halfway down the middle of the calf It picks up the sural communicating nerve and travels with the short saphenous vein behind and below the lateral malleolus superficial to the extensor retinaculum The area supplied is the lower postero lateral surface of the leg the lateral side of the foot and the lateral part of the fifth toe A communicating branch passes to the lateral branch of the musculo cutaneous nerve distal to the malleolus and the importance of this fact will be discussed later



FIGURE 3 Course of sural nerve

Saphenous nerve (Fig 4)

A branch of the femoral nerve the saphenous pursues a complicated course before piercing the deep fascia at the knee 4 finger breadths behind the medial border of the patella It travels with the long saphenous vein down the medial side of the leg which it supplies anterior to the medial malleolus to innervate the medial part of the foot as far forward as the mid portion occasionally to the metatarso phalangeal joint

it can be rolled under the finger This procedure is faster, and less solution is necessary It is to be stressed that the nerve is easily palpable at the posterior aspect of the neck of the fibula, and often cannot be felt laterally Two to three cc of solution were injected onto the nerve or around it, paraesthesias not being necessary

Sural nerve

One to two cc of solution were deposited subcutaneously, superficial to the extensor retinaculum, about one finger-breadth below the lateral malleolus

Saphenous nerve

Two to three cc of solution were injected subcutaneously anterior to the medial malleolus

Agent

Lignocaine was used in this series because of its rapid onset, reliable action, and low toxicity A concentration of two per cent was used in adults, one per cent in children Adrenaline was used only in cases where prolongation of analgesia was desired, or occasionally to decrease the toxicity of the drug in children

Lignocaine blocks generally lasted 1¼ hours, and with adrenaline added, about 2 hours Until sensation returned, the patient was instructed to avoid injury to his foot The foot drop associated with the lateral popliteal block was never any problem

Procedure

When presented with a foot lesion requiring anaesthesia, the anaesthetist carefully considered the nerve supply of the area, and the nerve or nerves to be blocked were determined If more than one nerve was involved, the first was blocked, and after five minutes, both the extent of analgesia and the area of sensory loss were tested and recorded The second block was then instituted in a similar manner

For example, with an abscess of the third toe, blocking of the lateral popliteal and posterior tibial nerve was considered necessary The lateral popliteal nerve was blocked, and in five minutes the adequacy and area of analgesia were noted Posterior tibial nerve blocking followed, and again the analgesia and area of sensory loss were tested

If analgesia was absent or poor after five minutes, a re-blocking of the nerve was carried out immediately

Results

The series included in this study comprised 100 patients The youngest was 2 years of age, the oldest 65 years Males predominated in ratio of 7 3 Table I illustrates the large numbers of abscesses and lacerations which made up the series

TABLE I

REGIONAL ANAESTHESIA FOR THE FOOT

Surgical procedure	(%)
I and D abscess	48
Suture laceration	30
Toenail avulsion	10
Removal of foreign body	8
Excision of plantar wart	3
Toe amputation	1

TABLE II

BLOCK RESULTS

Block	No of cases	No of cases with incomplete analgesia	Cases with complete analgesia (%)
Posterior tibial	77	9	88
Lateral popliteal	60	6	90
Sural	20	2	90
Saphenous	15	0	100

TABLE III

COMPARISON OF AREAS OF ANALGESIA WITH TEXTBOOK AREAS OF SENSATION

	Normal (%)	Medial spread (%)	Distal spread (%)	Plantar spread (%)
Sural	60	40	—	—
Saphenous	84	—	10	6

Table II represents the results of the blocks Onset of analgesia varied between one and ten minutes, the latter figure including all cases of re-blocking The column under "Incomplete analgesia" includes all cases where re-blocking was necessary, and all cases where some discomfort was experienced during surgery Discomfort was never severe enough to require supplemental anaesthesia Two-thirds of the cases in this column were re-blocked and subsequently proved complete The last column represents all patients who enjoyed complete freedom from pain during the operation

Table III compares the areas of analgesia as determined in our study with those defined in the textbooks It is interesting to note that in as many as 40 per cent of our cases, the sural nerve supplied areas extending more medially than those described in references Often the whole fourth toe and the associated dorsal area were included Perhaps this can be accounted for by the presence of the previously mentioned communicating branch of the sural to the musculo-cutaneous nerve

The saphenous presented a less complicated picture In one-tenth of the cases the nerve supplied the medial part of the foot as far forward as the meta-tarso-phalangeal joint, and in two of these cases it supplied the whole medial aspect of the big toe In only four cases the saphenous overlapped a small area of the sole

Summary

1 In our study of anaesthetic techniques for the foot, the courses and distribution of the nerves supplying the foot were outlined in detail

2 A series of 100 cases of foot blocks was carried out, involving one or more of the four nerves innervating the foot, depending on the site of the lesion

The *sole* was anaesthetized by a posterior tibial nerve block behind the medial malleolus, and analgesia was complete in 88 per cent of the cases

The *dorsum* was anaesthetized by a lateral popliteal nerve block at the posterior aspect of the neck off the fibula, with complete analgesia in 90 per cent of the cases

The *lateral* portion of the foot was anaesthetized by a sural nerve block below the lateral malleolus, with complete analgesia in 90 per cent of the cases

The *medial* part of the foot was anaesthetized by a saphenous nerve block anterior to the medial malleolus, and analgesia was complete in all cases

3 The areas of analgesia mapped out following the blocks for the most part reflected the textbook picture of sensory distribution There were, however, two patterns of variation which occurred with some degree of frequency

a The sural nerve required blocking for many dorsal lesions because it extended medially to include the fourth toe in 40 per cent of the cases No doubt this was due to the presence of its communicating branch to the musculocutaneous nerve Thus any dorsal lesion extending laterally beyond the third toe required sural blocking

b The saphenous nerve presented problems of anomaly in some 10 per cent of the cases, usually extending forward only to the metatarso-phalangeal joint of the big toe Rarely was the medial portion of the great toe innervated by the saphenous nerve, but if this was the case with surgery involving this toe, the nerve was blocked easily as described

Briefly then we may consider the site of the lesion and the nerve blocks required Any dorsal lesion requires a lateral popliteal nerve block, and if the lesion extends to or beyond the fourth toe, a sural block is necessary as well Seldom is a sural block done alone Toe lesions generally require lateral popliteal and posterior tibial nerve blocks Any lesion involving the medial side of the foot necessitates a saphenous nerve block unless it is well forward on the side of the big toe The sole is nicely anaesthetized by a posterior tibial block

We were pleased with the results of this series These blocks are now used by all anaesthetists in our department for surgery of the foot when regional anaesthesia is desirable All out-patient and casualty procedures can be carried out with this form of analgesia, and much of the surgery in the main theatre as well, when a tourniquet is not necessary The nerve blocks are simple to perform, work rapidly and predictably, and can be mastered within a short time by any physician interested in the foot

Résumé

Nous avons décrit en détail les trajets et la distribution des nerfs du pied Nous avons pratiqué une série de 100 blocages du pied, intéressant un ou plusieurs des quatre nerfs du pied, selon le site de la lésion

La surface plantaire a été anesthésiée par un blocage du tibial postérieur en arrière de la partie moyenne de la malléole et cela a réussi dans 88 pour cent des cas La surface dorsale du pied a été anesthésiée par un blocage du nerf poplité externe à la partie postérieure du col du péroné, cela a réussi dans 90 pour cent des cas La partie externe du pied a été anesthésiée par un blocage du saphène externe au-dessous de la malléole externe, cela a réussi dans 90 pour cent des cas La partie interne du pied a été anesthésiée par un blocage du nerf saphène en avant de la malléole interne, cette anesthésie a toujours réussi

Les zones d'analgésie dessinées à la suite des blocages, la plupart du temps, reproduisaient les dessins des auteurs sur la distribution sensitive Toutefois, nous avons observé deux types de variations qui apparaissaient avec une certaine fréquence

a Le saphène externe doit être bloqué dans plusieurs lésions dorsales parce qu'il s'étend sur la ligne médiane pour innerver le 4e doigt dans 40 pour cent des cas Sans doute, cela était dû à sa branche communiquante avec le nerf musculo-cutané Ainsi, toute lésion dorsale s'étendant latéralement au-delà du 3eme doigt requiert un blocage du saphène externe

b Le nerf saphène présente des problèmes d'anomalie dans environ 10 pour cent des cas, ordinairement il se prolonge en avant à la seule articulation métatarso-phalangienne du gros orteil Ce n'est que rarement que la portion médiane du gros orteil était innervée par le saphène, mais s'il arrivait qu'il en était ainsi au cours de la chirurgie du gros orteil, il était facile de la bloquer de la façon décrite

Rapidement, on peut étudier le site de la lésion et le blocage à pratiquer Toute lésion dorsale exige un blocage du nerf poplité externe et, si la lésion s'étend jusque au-delà du 4eme doigt, il faut aussi bloquer le saphène externe Il est rare de pratiquer un blocage du saphène externe seulement Les lésions d'orteils exigent d'habitude un blocage du polité externe et du tibial postérieur Toute lésion intéressant le côté interne du pied exige un blocage du saphène à moins qu'elle soit bien antérieure et sur le côté du gros orteil La plante du pied s'anesthésie bien par un blocage du tibial postérieur

Nous avons été heureux des résultats de ces séries Ces blocages sont maintenant pratiqués par tous les anesthésistes de notre service au cours de la chirurgie du pied, lorsqu'une anesthésie locale est indiquée Tous les malades externes et les accidentés peuvent être opérés à l'aide de cette technique d'analgésie et une bonne partie de la chirurgie de la grande salle d'opération peut également être pratiquée avec cette anesthésie, lorsque le garrot n'est pas nécessaire Les blocages nerveux sont simples à faire, s'installent rapidement et de façon prévue et, en peu de temps, tout médecin intéressé dans le pied peut maitriser cette technique

ACKNOWLEDGMENTS

The author wishes to express his gratitude to Professor Shirley Fleming and the other members of the Department of Anaesthesia at Lagos University Teaching Hospital, for their assistance and encouragement in preparing this paper

REFERENCES

1 DAWKINS, O S, RUSSELL, E S, ADAMS, A K, HOOPER, R L, ODIAKOSA, O A, & FLEMING, S A Intravenous Regional Anaesthesia Canad Anaesth. Soc J *11* 243 (1964)
2 LEE, J A A Synopsis of Anaesthesia 5th ed Bristol Wright (1964)
3 GRAY Anatomy, 33rd ed London Longmans (1962)
4 CUNNINGHAM Manual of Practical Anatomy, vol 1, 12th ed London Oxford (1961)
5 ZUCKERMAN, S A New System of Anatomy, 1st ed London Oxford (1961)