

Chapter 3

Panorama of Cancer



“Everything was fine till yesterday, but today I came to know that my tissue has turned out to be positive for cancer. After retirement, I started my second innings with lot of aspiration, enjoying with my grandchildren, teaching the underprivileged school students in our colony, doing Yoga with peer groups and many more fun activities. Suddenly everything collapsed. I lost my *jivisha*, my desire to live. But few questions are haunting me day and night: Why me? I never indulged in any kind of addiction. I had been doing regular exercise throughout my life. My parents didn’t have cancer. Even the doctor couldn’t answer my query; he is only preparing me and my family to fight the battle”.—Mr. Naresh Pandita, a 70-year-old retired bureaucrat, shared his agony when he came to see me to manage his newly diagnosed cancer of lung. I believe these are the thoughts that commonly occupy a person who is newly diagnosed with cancer.

3.1 Cancer: An Unpredictable Melody

There are many theories related to the occurrence of cancer, but none can answer all the questions on when and why it occurs. Scientists have found that certain factors—lifestyle choices, habits such as smoking and alcoholism, critical gene and family history of cancer—may cause cancer, but these too are immensely unpredictable.

Ageing is one of the non-modifiable risk factors for cancer. In 60% cases, the newly diagnosed cancer occurs in people who are 65 years old or above. Incidence of cancer in those over 65 in age is ten times higher than younger patients [1]. Some studies have focussed on DNA metabolism and repair process. For example, microsatellite instability in haemopoetic stem cells, the stem cells that give rise to all the other blood cells, derived from the bone marrow showed high level of aberrations in the elderly as compared to younger adults [2].

3.2 Non-specific Symptoms in Elderly May Be Signs of Cancer



Mr. Prabir, a good friend of mine, had dedicated his life to the service of elderly in the community. He was filled with excitement and pride on the birth of his daughter. “Goddess Lakshmi has blessed my family in the form of a baby girl”, he exclaimed over the phone.

I enquired about the health of the baby and Meghla, the mother. He told me that both of them were well and healthy. He couldn’t stop talking about his newborn’s smile, and how he was happy spending hours and hours with her.

Mr. Prabir, Ms. Meghla and their family were living in the peaceful and lush green campus of Gandhi Smarak Nidhi at ITO, Delhi. Located amidst the greenery were small offices and staff quarters. The people residing and working in the campus were the remaining few Gandhians of this country, who lived a life of simplicity and spread the messages of Mahatma Gandhi, one of the greatest social activist philosophers of the last century.

However, all was not well in this beautiful serene campus. Two days before Meghla was admitted for delivery on 12 December 2016, Shri Anupam Mishra was admitted to the hospital on account of severe weakness and probable chest infection. Anupam Mishra, a noted environmentalist, was the Vice Chairman of Gandhi Smarak Nidhi and was also living on the campus. On the one side, a fresh bud blossomed to greet the world, whereas on the other, an old leaf was about to wither away.

I was extremely upset when my junior resident Dr. Mohit told me that Mr. Mishra’s scan of chest and abdomen showed extensive metastasis of his neuroendocrine tumour (NET) of the prostate. When tumour spread to other organs from its originated place, it is called metastasis.

In October 2016, Mr. Prabir had paid me a visit at my office in AIIMS. It was nearly 3 days prior to Durga Puja, a Bengali festival during which devotees pray to warrior Goddess Durga for strength. I heard a soothing voice and saw an old gentleman along with Mr. Prabir, standing at my doorstep with folded hands. I could tell from his appearance that he was suffering from some major illness.

Mr. Prabir introduced me, “Sir, Shri Anupam Mishraji has come to see you. He was in a private hospital for a tumour in the prostate for the past couple of days. But now he has complained of recurrent infection in the kidney”.

“Namaste, Doctor Sahab” Mr. Mishra greeted me.

“Namaste, sir”, I responded immediately, “I have heard a lot about you from Prabir. I always wanted to meet you to talk about your efforts to conserve water; the concept really intrigues me”.

It was evident that he was smiling through his pain. He replied politely, “I had told Prabir that I will come to meet you, doctor. I know you are very busy; you should not waste your time to come to see me”.

Such was his humbleness. I asked him how I could be of help. His wife, Ms. Manju, was also accompanying him. She gave me all the documents. As I went through the reports, I was listening to Mr. Mishra who spoke with much modesty even in the midst of his travesty. “Everybody has to come to AIIMS at least once in their lifetime to get rid of their problems. I had some uneasiness in my lower part of the tummy eight or nine months ago. Initially, just like any other layperson, I neglected it. But almost after a month of being in pain, my cousin, who was a radiologist, convinced me to do an ultrasound scan of abdomen. I could sense he was little surprised and anxious while seeing the internal organ through the tummy”.

I saw the first page of the discharge summary, dated 10 February 2016, which read:

“Mr. Anupam Mishra is 68 years old gentleman is presented with increased frequency of micturition with pain in hypogastric region, mass in urinary bladder with extensive lymphadenopathy with SPSA 163 ng/ml. TRUS guided biopsy was done-? Ca Prostate”.

I was hopeful that there was a probability of a milder variety of cancer, namely, adenocarcinoma prostate, amenable to surgery and chemo with good prognosis. It seemed like a challenge, but I had the belief and the confidence that I could do better for him.

Mr. Mishra further told me: “I was jittery to get admitted in such an expensive hospital. But my elder cousin counselled me that everything will be at a subsidised rate. The team of doctors and paramedics from that hospital provided me a compassionate and comprehensive care. They told me that I have a tumour in my prostate gland”.

Then I checked his prostate biopsy report which was done on 17 February 2016. It mentioned an adenocarcinoma prostate with Gleason score 8.

Gleason score is a grading system of prostate tumour, devised in the 1960s by a pathologist named Donald Gleason who realized that cancerous cells fall into five distinct patterns as they change from normal cells to tumour cells. The cells are scored on a scale of 1–5 (Fig. 3.1).

The pathologist, who checks the biopsy sample, assign one Gleason grade to the most predominant pattern in the prostate biopsy material and a second Gleason grade to the second most predominant pattern. Finally the two grades will then be added together to determine the total Gleason score. For example: 3 + 4 (between 2 and 10).

A low Gleason score [2–4] means the cancer cells are similar to normal prostate cells and are less likely to spread; a high Gleason score [5–10] means the cancer cells are very different from normal and are more likely to spread to other organs [3].

But pelvis, that is lower abdomen, scan suggested mass lesion in the urinary bladder with right-sided hydronephrosis (Fig. 3.2).

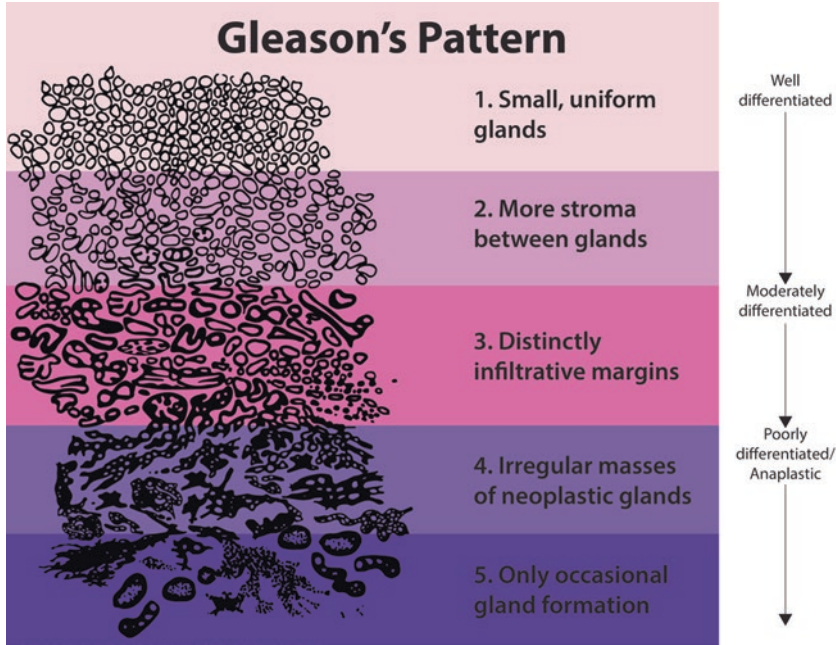


Fig. 3.1 Gleason's Pattern Scale. (Source: <https://www.prostateconditions.org/about-prostate-conditions/prostate-cancer/newly-diagnosed/gleason-score> (Accessed 4 October 2018))

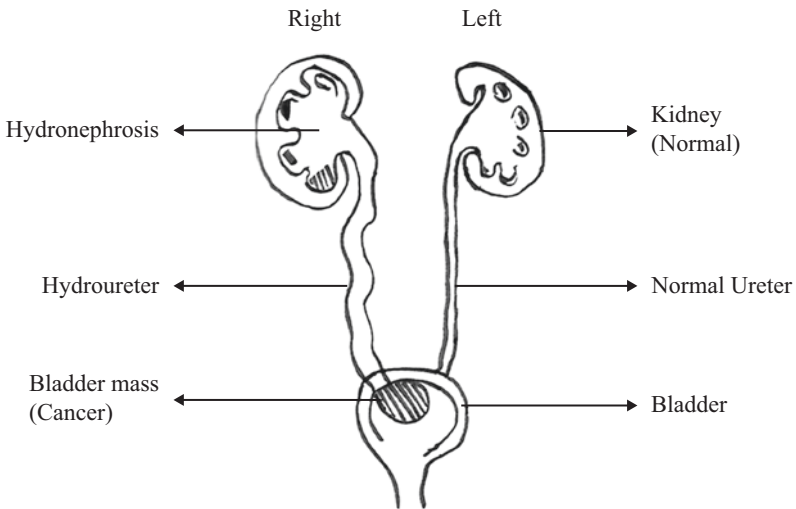


Fig. 3.2 Right-sided bladder tumour obstructing uterus opening and causing hydronephrosis due to back pressure. (Source: Author)

Hydronephrosis is the swelling of kidneys when urine flow is obstructed in any part of the urinary tract [4]. Usually, tumour cells do not spread to bladder. Cancer cells mostly spread through lymphatic system or the bloodstream to the backbones, lymph nodes, lungs, liver and brain.

I started wondering whether he was suffering from two different types of cancer.

However, the last page of the hospital's discharge summary came as a shock to me. Mr. Mishra had been diagnosed as "a case of Metastatic Ca prostate (Mixed Adenocarcinoma and neuroendocrine type (small cells) with it sided DJ stent in situ)–Patient has undergone two rounds of chemotherapy".

That night, I read about details of small cell carcinoma of prostate, which was comparatively rare variety for geriatrician. Small cell cancer is a type of cancer diagnosed at biopsy by pathologist, usually arising from epithelial cells that line the surface of the organ like lungs, prostate, etc. It is rare, accounting for less than 1% of all prostate cancers. As per the available literature, small cell carcinoma of all organs is an aggressive disease that spreads quickly. Symptoms depend on the tumour location within the prostate and on whether the cancer has spread to other parts of the body [5]. Approximately, half of the patients have pure small cell carcinoma at initial presentation. Around 25 to 50% of cases are mixed with a conventional prostatic adenocarcinoma (another variety in biopsy sample) [5]. But during our initial conversation, I didn't know much about the course of small cell variety with metastasis.

Mr. Mishra was looking at me with such hope that I wanted to say that his disease was curable and that he would gradually be fine with treatment. I tried not to dishearten him and told him, "I want to get you admitted in our ward, to treat the infection of your kidney and also to understand your disease better. I hope we would be able to provide you with good care to reduce your unease and also tell you the future course of the disease".

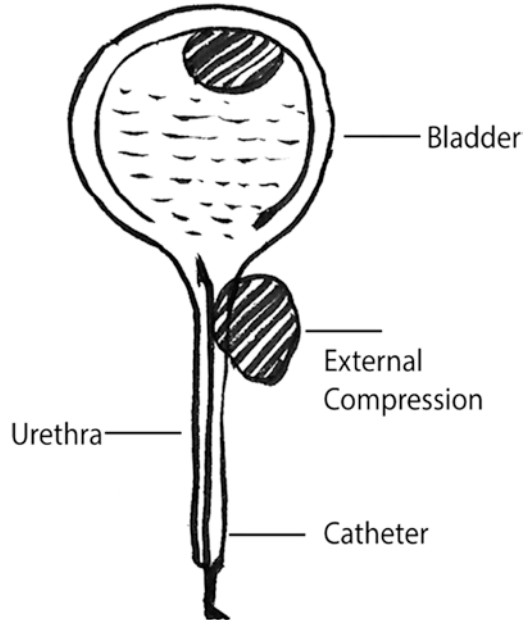
Mr. Mishra and his wife breathed a sigh of relief. I understood that the previous oncologist and internist must have explained them the prognosis correctly, but I was glad to be able to give them some positivity. Though I didn't know what made them relieved, whether it was getting admitted in AIIMS or my empathetic behaviour.

Mr. Mishra was admitted in the new private ward at AIIMS. He was febrile; his urine sample was sent for culture and sensitivity. As per the protocol at AIIMS, we sent his prostate biopsy slide from the private hospital for review. The urine culture was positive for organism sensitive to colistin. In the course of next few days, his fever subsided with the help of antibiotics.

3.3 The Varied Prognosis of Ca Prostate

On the fourth day of admission, I went to check up on Mr. Mishra. He informed me that he was feeling much better. His fever and burning sensation had subsided. However, he was worried about the swelling in his lower part of the tummy and both

Fig. 3.3 External tumour obstructing the outflow. There was another deposit in the bladder (Source: Author)



of his legs and the erratic flow of urine. I explained to him that there might be some obstruction in the path of urine flow, causing the swelling of the bladder, which was causing his tummy full. I drew a picture of bladder and urethra to explain it to him (Fig. 3.3). There might be an obstruction in the venous flow of the inferior vena cava, which might be the cause of the lower limb swelling.

He said, “Your simple and lucid explanation helped me understand my situation better. I must congratulate you for your fantastic team of doctors and nurses. They are cordial and compassionate. I understand that remaining problems will be fine within few days? I am probably disturbing you by asking too much”.

I responded spontaneously, “Not at all, sir. It is my duty to explain it to you”.

I left his room and continued with my morning rounds, but a single thought occupied my mind: “Who is counselling whom? Is a doctor counselling his patient who is counting his days, or is a wise man counselling a young doctor who wants to do good for his patient?” I prayed for his wellbeing.

During my morning rounds the next day, Mr. Mishra continued to complain about the swelling in his abdominal area, which also came up in the CT scan of his abdomen. It was increasing day by day. I tried to explain that there were multiple lymph nodes in his limbs, which were pressing the inferior vena cava. I further explained that there might be another limb lymph node which could be obstructing the ureter due to which he was experiencing intermittent obstruction in his urine flow.

He understood, but of course he was anxious too. I knew that he was aware of the severity of the problem—that it was spreading to other organs and making him functionally and psychologically dependent. Like other days, that day too he complained about feeling weak and lethargic and said that he couldn’t sit up even for 15 min at a stretch. But after looking at my expressions and remembering my earlier

explanation, he gave an optimistic yet pragmatic response: “I think this will be fine with your treatment in a few days”. I just folded my hands and said, “Hope and pray so”. This statement resonated in his mind; he knew I used it many times and it meant that I was helpless. I told our junior resident Dr. Mohit to write for an oncology call in the name of Dr. Ravi whose area of interest and work is genitourinary malignancy. I gave a call to my friend Dr. Raju who was a senior resident under Dr. Ravi. Both the doctors came the next day to evaluate Mr. Mishra’s situation. Dr. Raju called me in the afternoon saying, “Prashun *Da*, it is neuroendocrine tumour of the prostate, highly aggressive and there is not much treatment at this stage”.

Dr. Raju was very confident about the prognosis as he enquired from our pathologist, who reviewed the slide and confirmed that it was NET (neuroendocrine tumour) of the prostate. By that time I had read more about the aggressive nature of NET prostate. Usually, prostate cancer is predominantly of an adenocarcinoma variety, with raised prostate-specific antigen (PSA). Blood level of PSA increases in the urinary tract infection; benign hypertrophy of prostate and marked increase is noted in adenocarcinoma. But in NET and predominately small cell variant, the PSA level is usually normal or minimal elevation. Prognosis of predominantly adeno variety is good. The mixed variety originates from the neuroendocrine cells of the prostate. When there is combination of adenocarcinoma and NET or small cell variety, the prognosis is poor [6].

Neuroendocrine prostatic carcinomas (NEPC) are considered as a special type of neuroendocrine differentiation of prostatic epithelial neoplasms. Unfortunately, 50% of NEPC patients visit the doctor when the disease has already spread to various other organs and are left with average lifespan of 9.8–13.1 months after diagnosis. NEPC may also occur concomitantly with conventional adenocarcinoma [7].

Initially, Mr. Mishra’s blood reports showed raised PSA. Considering the predominant adeno variety, the doctor in the private hospital had operated. I asked for a full-body PET (positron emission tomography) scan to look for metastasis. PET is a functional imaging technique that is used to observe metabolic processes in the body as an aid to the diagnosis of disease. It is especially useful in searching the hidden tumour cell in various other organs by seeing the uptake of cancer cells. I was dismayed seeing that the tumour cell had extensive metastasis to almost all the organs except the liver, lungs and brain.

3.4 Bias in Professional Opinion and Management of the Disease

I insisted, while discussing the case with Dr. Raju, “Can we not do something with chemotherapy, radiotherapy or nuclear medicine therapy?” My statement was probably emotional with minimal scientific evidence. Maintaining a balance between scientific evidence, clinician’s experience and patient’s functional status is not only important to manage end-stage cancer; it is also important for initiating palliative care. The assistance to the patient and the doctor in taking difficult decisions, after

establishing the goals of care and treatment, is of immense value. The complex needs of terminally ill patients, in particular, can be met most effectively through dedicated palliative care programmes, which are non-existent in most of the hospitals, both public and private, in India [8, 9].

I visited Mr. Mishra to discuss the present status of his aggressive disease with him. He was lying on his couch with his leg elevated as I had instructed. We had recommended leg elevation to improve venous flow to reduce the leg swelling. However, I knew that it would not work for him as the obstruction was external. He greeted me pleasantly and asked his son for another pillow so that he could lift his head. I sat on the smaller couch next to him and began the conversation by requesting him to tell me about his work in water conservation. I knew that I had touched the right cord; his excitement to discuss the topic was evident. He instructed his son pass me a book.

He told, "I have written a small book, titled *Aaj Bhi Khaare Hain Taalaab*. You know, Doctor, my father was a follower of Gandhiji and he worked a lot with Dr. Vinoba Bhave, so once I completed my masters in Sanskrit, my father sent me to Gandhi Peace Foundation. They gave me a chair and table and asked me to do some official work, like editing a magazine about Gandhian philosophy. Once they had sent me to Jaipur for some important work. There, I fell in love with the way people of Jaipur used to preserve water. I stayed in a remote village near Jaipur to understand how they preserve rainwater and save millions of lives. Doctor, please read this book, and if possible, please also listen to my TED [10] speech. But I didn't keep any royalty from this book as I feel that I learnt from the society and so I need to give back to the society, why to charge!"

He further told me that the book was translated into different languages. I couldn't bring myself to break the bad news that day, as he kept on talking about his passion and his dream for a better world. Another thought came to my mind: Mr. Mishra and his wife could be fully aware of the situation but didn't want to think about that last stage, a very common scenario in Indian settings where preparation for active late life and dignified death is not discussed.

I was facing various end-of-life ethical dilemmas first-hand. It was a time for reflection on the fundamental ethical principles that guide clinical medicine and their direct application to palliative care and managing frail older adults. In geriatric practice, we don't treat the disease, we treat the patient. So, we always take the patient and their caregiver on board in decision-making. But many a times, we take a lot of time to break the news, as and when the situation permits.

The next morning he informed me that due to the treatment and care he was being provided, he did feel better, but there was swelling in the genital region and swelling in his legs was still persistent. He was facing difficulty in urination as well. I examined and prescribed a scrotal elastic support, which helps to reduce the swelling due to oedema in the genitalia. I tried to understand if there was any chest infection. He mentioned that there were no new symptoms, but he was taking Duolin in inhalational form. He showed apprehension in taking a steroid-containing drug I had prescribed as he feared that it might make him dependent. It is ironic that even well-educated people, like Mr. Mishra, still consider that inhalational steroid ther-

apy for bronchial asthma will make them dependent with impaired quality of life. It has been scientifically proven that inhalation steroid is safe for the management of bronchial asthma with minimal systemic absorption [11].

That day I was about to tell him that his disease had spread to most of the organs and he was left with few days, but there was a strong opposition from his wife to “not to do so”. I failed again.

As I came out of the room with his wife, Ms. Manju Mishra, she said, “Doctor, he knows everything about the disease and its aggressiveness. He understands that the disease has further progressed and spread to other vital organs except his lungs, liver and brain”. She started crying. I was speechless. “Doctor, please tell me honestly, how long will he survive?”, she asked. Her next question was difficult; I had no answer.

I was helpless but not hopeless. I discussed the case with my colleague from the department of nuclear medicine, Dr. Shakil Ahmed, who promised to visit and try for some nucleotide based therapy.

“Hi! Dr Prasad, I feel there is a chance that Anupamji’s survival might increase to six months if Lutetium-177 (Lu-177) works on his tumour”.

I rushed to tell Mr. Mishra that “there is still some hope”. I was excited as I thought, if an ambitious man like Mr. Mishra gets a chance, he will make 6 years out of these 6 months. But I couldn’t.

Mr. Mishra was looking at the sunlight, which was illuminating the dark corner of the room with teary eyes. He was visibly weaker and told his wife not to disturb. Probably he was in a different world, thinking about the environment and the Mother Earth.

I could not share the news with him but with his wife. Dr. Shahil had recommended two to three types of PET scan to see the uptake in this special type of cancer. It took almost a week to complete all the PET scans.

We were hoping that Dr. Shakil would confirm that tumour cell would be amenable to nuclear medicine therapy.

This is the advantage of multidisciplinary care in geriatrics where symbiosis of knowledge only makes each one wiser.

Every round that I made to visit this extremely humble man was a learning experience for me. I distinctly remember an episode from one of his PET scans. When he was taken in a wheelchair to the scan table, he saw that the patient before him had left the bed unmade and the pillow was lying on the floor. Mr. Mishra got up from the wheelchair and rearranged the bedsheet. After his scan was complete, he made sure that the bed was neatly made for the next patient. Considering his frame of mind while dealing with end-of-life issues, such behaviour was not common from a patient nearing his end.

Mr. Mishra was referred for nucleotide therapy after a telephonic discussion with Professor Rabin Singh, who was head of the department of nuclear medicine. Although he had made it clear that Lu-177 would not work in grade 4 neuroendocrine tumour, on my insistence, he agreed to try and see if it works in Mr. Mishra’s case. But he was also positive about Mr. Mishra, considering his positive attitude and good functionality score. We infused Lu-177 followed by palliative radiotherapy.

Fortunately, he tolerated radiotherapy well and the post-treatment PET CT showed uptake of the medicine to the correct target. I was immensely happy that day and informed him and his wife that I felt his tumour was responding to nucleotide therapy and since that would definitely improve the quality of life, he probably could resume his office activity also.

But I still couldn't bring myself to tell him that despite this treatment his life expectancy would be only 4–7 months.

We always try to involve the patient during management to maintain patient's autonomy, especially when the case is unpredictable. When I asked Mr. Mishra and his wife about nucleotide therapy, they replied, "Doctor, do whatever is best. We know you are the best judge". This is a usual response from most of the patients and their kin, irrespective of their socio-economic status. Elderly patients totally surrender themselves to the doctor towards the end of their life. This becomes a difficult scenario for doctors like us. In balancing the principles of medical ethics, evidence-based care and family sentiment, we do give more significance to the family's sentiment.

Mr. Mishra was convinced that the swelling in his leg would subside completely since he had noticed the abdominal swelling reduce drastically after the treatment. On completing the investigation and the possible treatment, we observed that there was minimal symptomatic improvement and no urinary tract infection, so we thought of discharging him. One of the components of geriatric practice is to know when to discharge a patient. The doctor needs to aim to achieve the set target, while keeping in mind the patient's comfort and prevention from hospital-acquired infections or any other iatrogenic factors. By then, Mr. Mishra had been in the hospital for more than a month, being immunocompromised; his immune system was weak due to cancer and ageing; hence he was more prone to hospital-acquired infection.

However, Mr. Mishra resisted the decision of being discharged. He wanted to stay in the hospital till the swelling subsided and he gained enough strength. He told me that he could not sit for more than 15 minutes at a stretch and wanted to resume work only once he was recovered well to sit for a longer duration. In retrospect, I wondered why I tried to stretch him too much—probably to boost him, to improve his confidence. In one of my counselling sessions, I told him about the poet Shri Sukanta Bhattacharya, who had died young. I recited one of his poems:

Tabu Aaj jatkhana dehe acha Pran
Pran pone prithivir sarab janjhal
A Bishwake a sishur basjaygya kare jabo ami
Naba jataker kache a amar drio angikar—Charpatra, Shri Sukanta Bhattacharya (Poet) [12]

"I promise to the new born baby that I would work hard against injustice of any form till my last breath, to make this planet a better place".

I told him, "I feel you are also doing the same thing. I don't want to see you losing the battle, and not trying till the last breath to save the environment". After this counselling, till his last breath I never heard him complaining about weakness and inability to work. He was discharged after three more days of hospital stay.

Towards the end of November 2016, Prabir requested me to meet the secretary of the Gandhi Peace Foundation regarding a medico-social congress they wanted to organise. Since I was visiting campus anyway, I thought of meeting Mr. Mishra first.

When his wife opened the door, she was quite surprised to see me, but of course very happy. Mr. Mishra was lying on the couch, and he immediately tried to sit up, though with a lot of effort. My visit was a friendly one, and not as a physician, so I just casually enquired about his health. He said, “Doctor, I am fine, but few days back a friend brought a radiotherapist doctor who treat cancer cell by killing it by light therapy. He told me that prostate cancer has lot of affinity to bone. I am having back pain for the past couple of days. Do you feel my cancer had spread from prostate to back?”

As per literature review, 75% of all patients with cancers of the breast, prostate, and lung may present with spread of tumour in the bone, especially in the vertebra. Small cell carcinoma of any organ spreads to almost all the organs and much earlier to the spinal cord [13].

Through the spinal cord, it transmits to various nerves, which are important for our movement, bowel, and bladder function [14].

Sometimes, the metastatic cancer cell can press in the nerve roots to create symptoms. But in his case, the good thing was that it was not pressing the chord, so he was able to walk. After some 20 min of having a cordial conversation, I took my leave. Mr. Mishra walked with me for a short distance in the campus, supported by his brother-in-law. He became nostalgic about the Foundation; he had worked there his entire life. Looking at the banyan tree that he had planted in 1978, he started reminiscing, “The banyan tree has left its legacy through the vines, it has sheltered innumerable tiny creature. But most importantly, by propagating through hanging roots it reserves lot of water for us. I think its contribution to the mother earth is more than me”. He was happily sharing stories, but his weakness forced him to return to his flat after few steps.

3.5 Rapidly Spreading Tumour and Its Consequences

A few days later, I got a phone call from Ms. Mishra. He wanted to talk to me; the pain was increasing, and the present medication was not providing any relief. I told him that we would have to start with morphine. There was an immediate denial from his side. He told me that he had heard that morphine causes addiction and those who take it once have to take it lifelong. I listened to him patiently and persuaded him for morphine because that was the best and the only pain management procedure for him at that moment. I explained to him that according to the World Health Organization (WHO) pain management ladder, the pattern for tumour-related pain after paracetamol/tramadol is to start morphine [15].

I requested him not to worry about the addiction and reassured him that I was prescribing this in good faith.

On 10 December 2016, I had gone to IIM Ahmedabad, Gujarat, to deliver a talk on advancement of healthcare management. I got a phone call from Prabir that

Mr. Mishra was suffering from breathlessness and burning sensation while urination. I told Prabir to take him to our department at AIIMS and also instructed our senior resident to get him admitted to a private ward. According to Dr. Souvik's Bhattacharya (our senior resident) narration, Mr. Mishra was suffering from UTI with probable infection of the chest. It gave me some relief as this was easily treatable with sensitive antibiotics, and I was happy that we would be able to send him home soon. But destiny had something else in store for us.

When I visited him on the third day of admission, clinically I saw no findings suggestive of chest infection, and his chest X-ray was absolutely normal. He, however, was breathless, which forced me to think if the cancer had spread to his lung. I asked for a scan of chest on 13 December, in consultation with Dr. Dey, which proved our suspicion to be right. He had metastasis to almost every organ except the brain. Compared to a CT taken 2 months before, the cancer had spread to his liver, lungs and two-thirds of his bladder. Mr. Mishra went to delirious state, with irrelevant talk and restlessness. It could be due to severe pain inspite of high dose of morphine or due to release of various chemicals from the cancer cells.

3.6 The Life Course Perspective and the Penultimate Phase

Then environment minister Mr. Anil Dave came to see Mr. Mishra like many other eminent personalities. Mr. Dave had worked with him in various projects to save our rivers. In spite of his delirious state, Mr. Mishra recognized Mr. Dave when he enquired about his health. He mentioned few sentences about working together to save a river. He also mentioned, "When I would be fine I must come to see, how you are saving the river front of Narmada".

After that he spoke something in cognizable sentences with intermittent words related to saving the environment and water. Mr. Dave bid his goodbyes after 10 min and started talking to us in the corridor. He said, with lot of anguish and grief, "Mr. Anupam Mishra had devoted his whole life to the environment and water conservation so much so that even in his last phase of life, in such delirious state, he was talking about 'Andolon' (revolution) to protect the environment".

Mr. Mishra's behaviour reminded me the Hindu Holy book Gita's verse no. 16, which Dr. Vinoba Bhave has explained well as "Samskar can be acquired through the lifelong practice of good work or good thought". [16] Sanskars are embedded in the subconscious mind. It means the imprints of actions, associations and experiences that remain indelibly engraved in our mind and mould our behaviour, our personality and world view.

On 15 December, our multidisciplinary team—comprising an oncologist, radiotherapist, nuclear medicine specialist and geriatrician—discussed if we could have any respite care for Mr. Mishra palliative radiotherapy. I knew this was an effort without scientific evidence, and all of us agreed that since he was probably nearing his last few hours, the best course would be to provide comfort and care. Mr. Mishra was comparatively lucid that day and then the following day, he was awake almost

throughout the day. Conscious and cooperative, he tried to take some liquid food, but it became difficult due to a large node that was pressing over his oesophagus (upper part of the food pipe). His bladder was full as there was an external obstruction over the urethra, so even after putting a catheter, there was minimal output (Fig. 3.3).

I sat with his caregivers, his wife, his two sisters—Namita and Nandita—and his son Shubham. We unanimously decided that we would not do any invasive procedure on Mr. Mishra. His younger sister, Dr. Namita, was an anaesthetist. She requested me to not administer antibiotics either. A grim Ms. Mishra said, “Doctor, you said he will survive for six more months after giving nuclear medicine therapy”. Tears welled up in her eyes, but she continued, “We know it is difficult to predict, but we thought we would have some time left to be together”.

I was speechless, trying to hold back my tears. Many a times during our interaction with the patient’s caregivers, we have to tell the partial truth on the basis of inadequate evidence. Our knowledge about the progression of aggressive cancer is still insufficient, extremely variable and unpredictable.

Mr. Mishra was delirious from the morning of 18 December; throughout the day and night, he was short of breathing and had intermittent choking sensation possibly due to multiple metastasis in the lung which had spread to the alveoli (the balloon-like structure helps in oxygen exchange). It was impossible for him to swallow both solid and liquid food. Dr. Namita came to my room along with her elder sister on 16 December and said, “Doctor we don’t want to prolong his agony. We understood our brother would not survive. He is in deep pain and agony. Please do minimum possible, we heard your doctor was talking about artificial lung support. We don’t want artificial support like ventilator support”.

I asked, “Have you discussed this with his wife?”

Dr. Namita nodded.

She whispered, “He is suffering a lot and we want him to have a dignified death”.

Being an anaesthetist, she understands comfort care, but this decision was not so easy for a sister or a wife.

The term “comfort care” refers to the basic palliative care interventions that provide relief from symptoms to a patient who is very close to death. It is used to achieve maximum possible comfort in the form of relief, ease or renewal in four contexts of human experience—physical, psychospiritual, environmental and social. Familiarity with basic comfort measures is an essential skill required by all clinicians who care for patients whose death is imminent [17].

Comfort care was crucial in Mr. Mishra’s case by decreasing the distress at the end of life, reducing caregiver’s stress and its cost-effectiveness, and decreasing burden on the healthcare machinery and a sense of satisfaction for both the physician and the patient’s family. As requested by families and after further discussion, we took a step back. We didn’t insert a nasogastric tube and removed the Foley’s catheter. Mr. Mishra was breathless. After having two spoonsful of tea on the evening of the 17 December, he became delirious again. But he continued his belief in me and in himself. His only comprehensible sentences were “I will be fine in a day or two” and “Doctor, give me some relief”.

His bladder was full. Both of his legs were swollen. We tried to relieve him with simple rubber catheter and gave approximately 250 ml of fluid through the vein with permission from his caregiver. It was an early morning of 18 December when Mr. Mishra's condition deteriorated further. He had shortness of breath and intermittent choking sensation, which was most likely due to multiple metastases in the lung. It was impossible for him to swallow food, solid or liquid.

I would visit him twice every day, but I was only an observer like other visitors. He noticed my entry but looked at me with lot of agony for the last time.

To my surprise, in spite of the intolerable pain of the disease and the pain of leaving the family and the Mother Earth, Mr. Mishra was not so restless.

His aspiration to do better helped him to remain positive till his last breath.

Mr. Mishra and his family members were aware of the prognosis and the end, but we never discussed it directly, or rather, we couldn't. The art of exploring the patient's preferences in decision-making at the end of life is a challenging ethical question missing from medical curriculum in India. Elderly care physicians and oncologists face similar challenges like this case. It must be accepted that the lack of palliative care programmes and late-life care in Indian hospitals is probably an ethical failure to attend to the needs and relieve the suffering of the patients. Very few public institutes in this country, including AIIMS, New Delhi, have a qualified palliative care team. The role of palliative care team is mostly restricted to cancer-induced pain management.

Every hospital is ethically obligated to offer such programs to maintain the basic principles of medical ethics, that is, beneficence and non-maleficence, relieving the pain and suffering of all patients to the best of their ability at every stage of illness. Dignified death is equally important as is a life with a good quality. We, the ethical practitioners, are bound to learn the art and expertise to provide cost-effective, high-quality care by placing patients in the most appropriate level of care, decreasing hospital length of stay, expediting appropriate treatment and reducing the use of non-beneficial resources [18].

The readers may question me whether it was justifiable to do multiple PET scans for Mr. Mishra or should we have infused him Lutetium-177 (nuclear medicine therapy) who had come to us in last stage of prostate cancer? I might not be right, but every action of mine was in good faith to the patient, partially guided by emotional attachment with him.

“Doctor, why can we not diagnose cancer of any organ in advance and thus protect ourselves? Medical science has advanced so much. You are discussing genes, DNA, but why could you not predict my mother's cancer, who was under your care for the last couple of years?” Ms. Revati Sharma, a senior lawyer at the Supreme Court and a Delhi-based social activist, asked me when her mother got diagnosed with advanced cancer.

I counselled her that cancer is not always the end of the road, it could be a chapter in one's life. Ms. Sumedha Sharma, an 85-year-old woman with minimal formal education but supported by a caring daughter, has a positive story to tell.

3.7 Alarm Signs of Early Cancer

I got a call from Dr. Raman Kumar in the evening of 1 December 2015. It was regarding one of his patients, Ms. Sumedha Sharma's health. She had developed haematuria again, he told me. Dr. Raman is a generalist from a village in Bihar where Ms. Sharma was residing for the past 50 years. She had haematuria, that is, occurrence of blood in the urine, 5 months ago, and was treated by Dr. Raman with antibiotics.

When there is a history of painless/painful haematuria in the elderly, the first thing that comes to our mind is the possibility of a tumour in the urinary bladder, followed by infection of the urinary tract or tuberculosis of the bladder [19].

Ms. Revati Sharma was Ms. Sumedha Sharma's daughter. Breaking a bad news like cancer on the first instance is not only difficult but sometimes can seem derogatory too. I had asked Ms. Revati 5 months back, after the last episode of haematuria, to perform an ultrasound to see if there was anything wrong with her mother's bladder. However, the local doctor said that it was a case of urinary infection, rightly suggested by the urine culture reports. Dr. Raman sorted that issue temporarily. Ideally a woman aged more than 80 with haematuria must have been evaluated with ultrasound of the abdomen [20]. But it is difficult to find qualified sonologists (the doctor who does abdominal ultrasound) in the remote villages of Bihar. After the second episode of haematuria in Ms. Sharma, I insisted on evaluating her for bladder cancer, as I had suggested earlier also. Although Dr. Raman was a generalist, he had a good exposure to managing various urological conditions. He agreed, and so did Ms. Revati, who was the prime decider for her mother's care. Ms. Sumedha underwent ultrasonography in the nearest district town of Muzaffarpur, with a qualified radiologist who found a heterogeneous eco-texture (tumour) measuring 11 cm × 10 cm. within the bladder wall. The very next day, Mrs. Sumedha underwent a cystoscopy to visualize the bladder mass and to extract some tissue for biopsy.

Ms. Revati, a social activist, does her bit to help many patients by sending them to our Geriatric Medicine department at AIIMS. She wanted her mother to be admitted under my care in AIIMS as I was treating her for the past 2 years for Parkinson's disease and high blood pressure. Although I had not informed Ms. Revati about her mother's cancer, she was anxious and asked me, "Doctor, is it a cancer?" I confessed that I was not sure and told her that painless haematuria at this age is mostly due to some form of tumour or TB. I requested her to bring her mother to AIIMS for diagnosis and further management. Meanwhile, the tissue extracted in Muzaffarpur had been sent to a reputed private lab in Delhi.

Ms. Sumedha was on a wheelchair when she and her family reached AIIMS on the morning of 4 December 2015. I examined her vitals and also tried to do a comprehensive assessment. When I asked her how she was feeling, her carefree response was, "Doctor, I am okay, these people are unnecessarily tensed. Nothing has happened to me". I was not surprised to hear this reply, an 85-year-old lady, who had seen so many ups and downs in her life, would not be bothered with such painless conditions. May be she understood the matter and was trying to counsel her family,

especially her daughter. This was a family where the next generation stayed far away and was too busy, but attached to their roots and their parents.

Most of her family members were already aware of her condition. They had seen the cystoscopy report conducted at Muzaffarpur. I discussed the case with Professor A. B. Dey, the head of our department, and informed him that we were admitting her for probable, curative radical cystectomy (removal of the urinary bladder) as well as palliative radiotherapy (killing cancer cells by light therapy) and chemotherapy (injection or oral medicine to kill cancer cells). She was a typical case of geriatric patients with multimorbidity (Parkinsonism, mild cognitive impairment, bronchial asthma, hypertension) and geriatric syndrome (mild cognitive impairment). In an era of better understanding of multimorbidity and geriatric syndrome in the elderly population, these kinds of patients get admitted in the Geriatric Department but get intervention from multiple disciplines like urology, medical oncology and radiotherapy. Ms. Sumedha's medical morbidity, bronchial asthma and high blood pressure were under control. She responded well to tablet Donepezil (5 mg), a medicine for forgetfulness. She recognized me immediately and remembered that I had seen her during her last visit to Delhi almost 6 months back. She was by then comfortably walking with the support of a cane. So, basically, she was functionally (physical, mental and cognitive domains) fit for any major surgery in spite of the factors like her age, her multiple medical comorbidity and cancer.

In usual practice, we see patients who had been rejected for major surgical procedure for tumour resection only due to their calendar age which is mostly 80 and above. But what matters most is the biological ageing, functionality, physical and cognitive reserve and overall intrinsic capacity. Intrinsic capacity is defined as a sum total of all the physical and mental capacities that an individual can carry out at that point of time. Though gradual decline in the intrinsic capacity was observed with increasing age, some exceptional individuals aged 80 years or above exhibited intrinsic capacity higher than the mean level seen in young adults [21].

On the second day of admission, the urologist Dr. Kamlesh Chaube suggested cystoscopy and near-total curettage, that is, removal of tumour tissue, as much as possible. As per the protocol, we did magnetic resonance imaging (MRI) of the pelvis. We also did PET scan to look for spread of the tumour. There was an incidental finding in PET scan, which showed that there was some uptake in thyroid, probably a tumour. Dr. Dey asked for fine needle aspiration cytology (FNAC) from the thyroid swelling to look for whether the cancer cells from the bladder had spread to thyroid.

3.8 Comprehensive Geriatric Assessment: The Best Tool to Assess Octogenarian Preoperatively

There is no standard guideline for assessing the preoperative status for an elderly individual aged more than 80 and suffering from multimorbidity, like Ms. Sumedha. Traditional preoperative anaesthesia consultations capture only some of the

information needed to identify older patients undergoing elective surgery who are at increased risk for post-operative complications, prolonged hospital stays and delayed functional recovery and death. Compared to traditional risk score, which is predominantly focussed on cardiovascular risk and respiratory function, comprehensive geriatric assessment (CGA) aims at adequate screening of physiologic and cognitive reserves in older patients and enable proactive perioperative management strategies (like strength, balance and mobility) to reduce adverse post-operative outcomes and readmissions [22].

In preoperative CGA, there is a complete assessment of vision, hearing, functional status by Rockwood frailty method, cognition by Montreal MOCA scale, gait and balance by Timed Up and Go (TUG) test and depression by geriatric depression scale. For the functionality of a cancer patient, we also assess the E-cog score. It is used to examine how a patient's disease is progressing, how the disease affects the daily living abilities of the patient and determine appropriate treatment and prognosis [23]. Thus, E-cog score describes the level of functioning of a patient in terms of their ability to care for themselves, daily activity and physical ability [24].

So after a discussion with Ms. Revati, Professor Kamlesh decided not to go for curative cystectomy. But he assured that he would try and remove as much tumour as possible endoscopically. Transurethral resection of bladder tumor is a surgical procedure to remove the bladder tumor through the urethra without opening the abdomen.

One evening, when we sat to talk with Ms. Revati, she informed us, "You know Dr. Chatterjee and Dr. Kamlesh, I lost my father three years ago due to a surgical procedure. The surgeon was keen on operating and he removed the gallstone. We were not sure whether we should go for gallstone surgery or not, as it caused pain to my father only once in a blue moon. But the surgeon from a private hospital operated on him. According to the surgeon my father did well during the surgery. He was also doing well during recovery, but ultimately we lost him due to post-operative complication pneumonia. They put him on a ventilator, but he didn't come back".

Ms. Revati wiped her tears and said, "I don't want to lose my mother, so do as much as possible for her".

After a moment of silence, Professor Kamlesh started telling Ms. Revati about the tumour of the bladder as seen in the MRI report. With much compassion and confidence, he said, "Madam, ideally radical cystectomy, which means the removal of the urinary bladder with pelvic lymph node (the cancer cells usually transfer to this area first) dissection, is the standard treatment for patients with invasive bladder cancer, followed by chemo and radiotherapy [25]. But considering her age and functional status, I will go for a diagnostic cystoscopy, which means that we have to get adequate amount of tissue to diagnose and characterise the tumour. If it has not spread to other organ as per our MRI report, I will try to remove as much tumour as possible".

Preoperative assessment in older adults is not only challenging but also a difficult task in decision-making, especially when the caregiver and/or the patient is not confident enough. Heterogeneity of older adults, minimal understanding of functional resilience, multiple morbidities, weak immune system and cumulative deficit works in a supra-additive fashion to make the post-operative period unpredictable [26].

3.9 Functionality Matters More than the Calendar Age

To relieve Ms. Revati's anxiety, I also explained that her mother's functional status, including lung function test, her ECG and echocardiogram (pumping system of the heart) were normal. I told her, "We are confident that she would do satisfactorily during and after surgery. The anaesthetist have also given their green signal. Further, she had been vaccinated against flu and pneumonia, which prevents invasive pneumonia. We feel that this surgery with maximum tumour tissue removal would give her a better quality of life".

She asked me what would happen if in case her mother did not undergo surgery. Professor Kamlesh told her that although we couldn't be sure, but there would be intermittent blood loss through urine, and gradually the tumour would spread to the bladder wall, followed by other organs. It would cause pain in the bladder, and there might be obstruction in the path of urine flow at a later stage, thus increasing the risk of recurrent infection of the urinary tract, and as the tumour spreads, there would be specific symptoms for specific organs. For example, if it spread to vertebra, there will be back pain. He also mentioned, "We have to weigh the risk and benefit considering her present status. Surgery with recovery would definitely give her better quality of life".

Ms. Revati was finally convinced to go for the surgery for her mom, and by evening we got the reports of the FNAC done from thyroid. It showed benign adenoma (tumour) which did not require any active intervention. We were, of course, in doubt about dual malignancy, that is, malignancy in two separate organs which is not a very uncommon entity in elderly.

On 7 December 2015, Ms. Sumedha was scheduled for curettage of bladder mass. Her family was a little panicky as there was a history of post-operative death in her husband's case. To our surprise, Ms. Sumedha was very confident, and before she entered the operation theatre (OT), she reassured Ms. Revati that there was nothing to worry about and that she would make it despite the tumour in her body.

Professor Kamlesh allowed our junior resident geriatrician to be the part of the OT team, other than the surgeons and anaesthetist, which is not a usual practice in India. A model to engage the parent department in the process as Ms. Sumedha was admitted under Geriatric Medicine Department. A few studies have suggested that an individual admitted under a geriatrician, preoperatively as well as post-operatively, does better after surgery both in terms of mortality and morbidity and quality of life, as compared to an individual admitted in surgical specialty and operated. Although most of the study groups were older adults with hip fracture, the concept can be extended to preoperative older adults for other surgery [22].

Ms. Sumedha recovered well after surgery, but the intraoperative picture was not very favourable. Professor Kamlesh explained that tumour was big and had spread into the bladder muscle. He removed as much as was possible and sent it for biopsy. She was kept under observation in ICU after the surgery. The following 2 days were critical with waxing and waning course. She developed bronchospasm and related

breathing difficulty, needed oxygen support to keep her comfortable and also hyponatremia and managed with judicious usage of 3% sodium chloride.

Later, she was shifted to her old private ward room 1001. Although she was fine otherwise, recovering steadily from her weakness but the family, especially her daughter was tensed about the biopsy report, since the next course of action would depend on the report.

However, the waiting period was over. On the seventh day of surgery, the head of the department of pathology informed Professor Dey on Ms. Sumedha's that it was a follicular transitional cell carcinoma, stage 2; that means the cancer had spread into the thick muscle wall of the bladder. It is also called invasive cancer, but the tumour had not reached the fatty tissue surrounding the bladder and had not spread to the lymph nodes or other organs.

Ms. Revati was tensed and wanted to discuss about the prognosis and future course. She wanted to know whether cancer bladder is more common in the elderly.

In fact, more than 60% of the cancer occurs in population aged more than 65 [1]. Bladder cancer occurs most commonly in the elderly: the median age at diagnosis is 69 years for men and 71 years for women. Advanced age may be associated with worse outcome, but stage and grade at diagnosis remain key determinants of prognosis.²⁷ High-grade or muscle-invasive tumours are much more likely to progress and metastasize than low-grade, low-stage cancers, and the 5-year survival rates in patients with high-grade or muscle-invasive tumours are as low as 6% as per literature review [27].

She was little upset and had many doubts related to diagnosis of cancer and why I couldn't diagnose her mother's cancer in advance despite she being on my regular follow-up.

3.10 Routine Screening in Late Life

“Why didn't you do genome analysis to diagnose cancer for my mother in advance?”

I was discussing the advantages of study of cancer genomes with her—how its knowledge has improved our understanding of the biology of cancer and led to new methods of diagnosing and treating the disease. But it is only true for few cancers. Genetic analysis has revealed unexpected genetic similarities in different types of tumours. For instance, mutations in the HER2 gene have been found in a number of cancers, including breast, pancreatic and ovarian cancers [28].

3.10.1 *In One of Our Conversations*

“Doctor, do you think I am also at risk of bladder cancer like my mom?”

“Yes, it is there, but not always due to genetic predisposition”.

Sometimes, family members with bladder cancer have all been exposed to the same carcinogen (cancer producing chemicals) like dye industry chemicals called *aromatic amines*, chemicals from rubber, leather, textiles and printing companies are at risk.

“That is not in our case”.

“Smokers are three times more prone to develop bladder cancer than a non-smoker”. [29]

“I do social smoking”.

Ms. Revati told me about the preventive steps taken by the celebrity Angelina Jolie. A section in the latter’s memoir reads:

“Is there any way I can screen for myself like Angelina?” and gave me a section in Angelina’s memoir to read:

We often speak of ‘Mommy’s mommy,’ and I find myself trying to explain the illness that took her away from us. They have asked if the same could happen to me. I have always told them not to worry, but the truth is I carry a ‘faulty’ gene, BRCA1, which sharply increases my risk of developing breast cancer and ovarian cancer. My doctors estimated that I had an 87 percent risk of breast cancer and a 50 percent risk of ovarian cancer, although the risk is different in the case of each woman. [30]

“I am not sure. I will fix an appointment for you with our preventive Oncologist”. I assured her.

Certain genetic abnormalities are found to be associated with bladder cancer. Specifically, mutations in genes known as GNT and NAT may trigger changes in the body’s breakdown of some toxins, which can in turn lead to malignancies in the bladder wall.

Our discussion continued as Ms. Revati was keen to know more. There are very few types of cancer which have a familial transmission, and not many middle-aged women are bold enough like Angelina Jolie to have their breasts and ovaries removed considering the future risk. Otherwise, even in the era of genomic analysis it is almost impossible to predict who will develop cancer and when. Old-age cancer cases are mostly non familial. This may be due to accumulation of cancer-causing mutations or the changing features of tissue in old age, which promote higher cancer rates in the elderly.

“Why don’t you do routinely screen in old age population, as prevalence is so high?”, Ms. Revati asked.

There is a paucity of clinical trial data about the effectiveness and harms of cancer screening in this population. But an individualized approach to cancer screening decisions involves estimating life expectancy, determining the potential benefits and harms of screening and weighing those benefits and harms with relation to the patient’s values and preferences [31]. For instance, prostate cancer screening should not be performed after 69 years of age. And there are matters related to screening, like the concept of lag time to benefit (LtB), which is defined as the time between the screening (preventive intervention) and the visibility of health improvement [32]. If a screening intervention, such as the screening for colorectal cancer with faecal occult blood testing, has a lag time of 10 years for a risk reduction of one death per 1000 persons screened, and an individual has a predicted life expectancy

of 5 years, then such screening would not be likely to provide benefit for that individual. But early detection of cancer greatly increases the chances of available fruitful treatment. Mass education about possible warning signs of cancer and improving health-seeking behaviour is the key to success.

“What are the early warning symptoms of probable cancer, Doctor?” Ms. Revati further asked.

Some early signs of cancer include lumps, bumps and sores that fail to heal, tumour or skin cancer; abnormal bleeding from any part or any organ; black terry stool like hair colour; coffee-coloured vomiting (cancer of food pipe); acute-onset constipation or diarrhoea (alteration of bowel habit, cancer of lower food pipe); unexplained onset of cough (lung cancer); unintentional weight loss (tuberculosis or tumour); unexplained low-grade fever (tuberculosis or cancer); chronic hoarseness (Ca larynx); etc. [33].

Even after diagnosis, the chances of betterment cannot be decided by calendar age alone, but by the type of cancer, its spread to other organs and pathological variety; many things matter.

Ms. Sumedha was otherwise doing well. The urinary catheter was removed on the seventh day. There was no bleeding in urine.

On the ninth day, I asked her how she was doing. She said that she was absolutely fine and that she wanted to go home. It was indeed the perfect time for her discharge, but I requested her to stay for a day more so that I could chart her future treatment course.

Contrary to the common practice in the Western world, many a times, on the request of the next of kin (son or daughter), we do not reveal the diagnosis of cancer to the elderly patient. We did the same for Ms. Sumedha.

3.11 The Care Provider on Decision-Making Process

After the surgery, we gathered in the visitor’s room. I told Ms. Revati that usually the ideal management for this condition after surgery would be to try with chemotherapy and radiotherapy. Then, Professor G K Panth, an eminent cancer specialist in India, added that we would not recommend chemotherapy for her mother, and he explained why.

Chemotherapy is like carpet bombing. The medicine will not only kill cancer cell but also normal cells. Further, Ms. Sumedha was unlikely to tolerate chemotherapy as it would strain her heart, kidneys and liver along with a lot of side effects like nausea, vomiting, etc., or more serious side effects like acute shut down of her kidneys or heart. Radiotherapy, on the other hand, is like a surgical strike with targeted killing of cancer cells.

Ms. Revati had probably studied on the Internet, so she asked why we could not try multimodal therapy, a combination of chemotherapy and radiotherapy. I told her that of course multimodal therapy was a good option, but one needed to weigh the effects, side effects and tolerability. Ms. Revati was little apprehensive about the

tolerability of radiotherapy as she discussed with Professor Panth the merits and demerits of the treatment. However, by the end of the discussion, she agreed to go with radiotherapy. Our plan was to give Ms. Sumedha a full course of curative radiotherapy, which would consist of daily session, except Saturday and Sunday. It was scheduled to continue for a month or depending on how much she was able to tolerate. Radiotherapy can have side effects like burning sensation during urination, sudden changes in bowel motion, etc. We assured them that we would not continue with the treatment if and when she developed any of these side effects.

Diagnosis is kept under the rap even in an advanced stage of cancer to the patient. Family members distort the symptoms into a benign variety. Sometimes we tell the partial truth, like we told Ms. Sumedha, “You have a tumour in the bladder which has been removed and now we will treat you with light therapy (radiotherapy) to cure the disease”.

Ms. Sumedha was discharged and sent to her home in Delhi. She would visit hospital for radiotherapy as per schedule and completed 20 cycles. She responded extremely well to the treatment. Her appetite, mobility and overall quality of life improved. There were no more episodes of blood in the urine. But most importantly, compared to her age and morbidity profile, she tolerated radio therapy more than our expectation. On 21 December 2015, she developed burning micturition. Urine culture showed that she had a urinary infection due to *E. coli*. We immediately stopped radiotherapy and managed the infection with sensitive antibiotics for 1 week. Dr. Krish Jain, the Assistant Professor of Radiotherapy, started alternate-day radiotherapy but was forced to stop again permanently on the 25th day as she developed loose motion.

Six months later, Ms. Sumedha was in full of spirit of vitality, living in her “BIG HUT” independently. She was roaming in the garden with Ms. Revati and sharing her life experience. Even though we did not inform her about the cancer, she knew that she had conquered a major disease. This chapter of her life made her more confident, independent and positive. It had even changed her attitude towards her other morbidities. She had stopped complaining about Parkinson’s disease, blood pressure and other age-related changes like chronic constipation, less sleep in the night, etc. Tablet Syndopa Plus (110 mg) three times for Parkinson’s disease and by tablet Amlong 5 mg for hypertension were only medication. She herself had stopped all non-specific medication like multivitamins, omeprazole, ayurvedic churan for constipation, etc.

Her appetite improved significantly, she was eating three chapatis in her meal compared to one before surgery, two large cups of milk, and two seasonal fruits.

“I didn’t expect that I would tolerate surgery and light therapy but now I am better and God willing I think I will bless your daughter in her marriage, next year” Ms. Sumedha told with an expression of “pride and confidence”.

Ms. Revati smiled and told “me too”.

Older patients are mostly burdened by the cost and implication of multiple diseases from their adulthoods (HTN/DM/CAD), with the diagnosis of cancer; there

is an exponential increase in the familial, social and fiscal impact to them. But the psychological impact is burgeoning. Further, there is an apprehension about painful death, leaving the spouse alone, complete dependency and both physical and functional dependency. There is a greater incidence of depression and social isolation after cancer. But the approach to the disease and the attitude of the patient matters a lot.

3.12 The Big Decision

I was discussing about the progress of cancer care in last few years in AIIMS with Dr. Rathin Mukherjee. She was working with elderly cancer patient in our department as a PhD scholar under Dr. Dey. Her thesis topic was creating and validating a functional assessment scale for older adults. So probably our department was a suitable option for her.

Usually, either from the Geriatric Medicine OPD or from the ward, any patient suffering from cancer would be sent to meet Dr. Mukherjee, for comprehensive assessment of various comorbidities, functional status (combination of physical, psychological and mental) followed by decision of future course of action.

“There was a couple from UP, Mr. Abdul Karim and Ms. Hashina Bibi, used to come to me. Ms. Hashina was suffering from cancer of lung which had spread to adrenal and spine”. Dr. Mukherjee told me with empathy.

She continued, “They were a very happy and a complete couple. Mr. Abdul Karim, was of around 76 years, used to preach in a Masjid and Ms. Hashina, of 65 years, used to teach through free tuition for poor girl of their society”.

After consultation with our department and Dr. Mukherjee, they went to pulmonology lung cancer clinic of AIIMS for opinion and management. She had been prescribed with palliative chemo- and radiotherapy as the cancer was of advanced variety.

They came back to Dr. Mukherjee and decided that they wouldn't need any intervention.

“The couple was holding each other's hand, but very confident in their decision making and understanding about their destiny” said Dr. Mukherjee.

Sometimes the patients and their caregiver fight the battle in a unique way, instead of trying to do impossible to possible, visiting multiple doctors for the solution.

Mr. Abdul Karim came alone to Dr. Mukherjee after a week and told her with lot of misery, “Doctor, I love her too much, but I can't see her suffering from pain, difficulties in chemo and radiotherapy. Can you help me if she has any pain for the disease?”

His wife was functionally suitable to tolerate chemo and radio well, mentally contended but when they mutually decided not to go for any intervention,

Dr. Mukherjee didn't insist, only connected them with a NGO helping the cancer patients to manage the terminal phase of life.

Mr. Abdul Karim tried to complete her wish list: "took her to Hujj, the youngest daughter got married". The whole family and society stayed with her till her last breath.

Understanding how cancer develops and behaves in the elderly and determining which older patients can benefit from treatment—and which ones lack the resilience to tolerate it—is an important aspect of cancer care.

Screening should be judicious and on the discretion of the doctor with experience in geriatrics, with special focus on life expectancy.

Although the trend is changing, but oncologist focuses more on calendar ageing instead of biological ageing, functionality or frailty status to select patient aggressive treatment vs palliation.

Both the story with real-life experiences had clear indication to overcome ageism in cancer care. The next step is to develop strategies to address the specialized needs of elderly cancer patients. Integrative care by incorporating geriatric assessment into oncological care would invariably improve better patient selection, reducing toxicity and improving quality of life and clinical outcome. The patients deserve best care irrespective of age, sex, caste, religion and economic status.

Can we discriminate between these two elderly patients:

An 85-year-old functionally healthy husband to a wife of 80 years with multimorbidity without their next generation nearby has newly developed cancer of prostate, which was amenable to surgery.

Another 65-year-old gentleman, who is also a widower, stays alone or in joint family developed cancer of the thyroid. Both are equally eligible and needed candidate to get full treatment and care for their cancer.

Should calendar ageing is a discriminator for an old man with cancer?

Awareness about cancer care is required not only among the doctors but patients and their care provider to have informed voluntary decision-making.

References

1. Berger, N. A., Savvides, P., Koroukian, S. M., et al. (2006). Cancer in the Elderly. *Transactions of the American Clinical and Climatological Association*, 117, 147–156.
2. Halter, J. B., Ouslander, J. G., Studenski, S., High, K. P., Asthana, S., Supiano, M. A., & Ritchie, C. (Eds.). (2017). *Hazzard's geriatric medicine and gerontology*, 7E. New York: McGraw-Hill Education LLC.
3. Prostate Cancer Foundation. *Grading your cancer*. Available at <https://www.pcf.org/c/gleason-score>. Accessed 4 Oct 2018.
4. *The Free Dictionary*. Available at <https://medical-dictionary.thefreedictionary.com/hydronephrosis>. Accessed 4 Oct 2018.
5. Wagner, D. G., Huang, J., Cheng, L. *Pathology of small cell prostate carcinoma*. Available from <https://emedicine.medscape.com/article/1611899-overview>. Accessed 4 Oct 2018.

6. Xenaki, S., Hingorani, R., Young, J., & Alweis, R. (2014). Mixed adenocarcinoma and neuroendocrine prostate cancer: a case report. *Journal of Community Hospital Internal Medicine Perspectives*, 4(5), 25176. Published 2014 Nov 25. <https://doi.org/10.3402/jchimp.v4.25176>.
7. Parimi, V., Goyal, R., Poropatich, K., & Yang, X. J. (2014 Dec 9). Neuroendocrine differentiation of prostate cancer: A review. *American Journal of Clinical and Experimental Urology*, 2(4), 273–285.
8. *A life lived with dignity*. Available at <http://www.livemint.com/Leisure/roy6c44JpWP50DYmK496yN/A-life-lived-with-dignity.html>. Accessed 4 Oct 2018.
9. *Unbearable pain; Indias-obligation-ensure-palliative-care*. Available at <https://www.hrw.org/report/2009/10/28/unbearable-pain/indias-obligation-ensure-palliative-care>. Accessed 4 Oct 2018.
10. *TED: Ideas worth spreading*. Available at <https://www.ted.com/>. Accessed 4 Oct 2018.
11. Barnes, P. J. (2010). Inhaled corticosteroids. *Pharmaceuticals*, 3(3), 514–540. <https://doi.org/10.3390/ph3030514>.
12. *Sukanta Bhattacharya's Poems*. Available at <http://www.kolkata-online.com/bangla/sukanta/>. Accessed 8 Mar 2019.
13. Sugiura, H., Yamada, K., Sugiura, T., Hida, T., & Mitsudomi, T. (2008). Predictors of survival in patients with bone metastasis of lung cancer. *Clinical Orthopaedics and Related Research*, 466(3), 729–736. <https://doi.org/10.1007/s11999-007-0051-0>.
14. Highsmith, J. M. *Spinal cord, nerves, and the brain*. Available at <https://www.spineuniverse.com/anatomy/spinal-cord-nerves-brain>. Accessed 4 Oct 2018.
15. *WHO's cancer pain ladder for adults*. Available at <http://www.who.int/cancer/palliative/pain-ladder/en/>. Accessed 4 Oct 2018.
16. Bhawe, B. *Talks on the Gita*. Available at https://www.mkgandhi.org/ebks/talks_on_the_gita.pdf. Accessed 4 Oct 2018.
17. Truog, R. D., Campbell, M. L., Curtis, J. R., et al. (2008). Recommendations for end-of-life care in the intensive care unit: a consensus statement by the American College of Critical Care Medicine. *Critical Care Medicine*, 36(3), 953–963. <https://doi.org/10.1097/CCM.0B013E3181659096>.
18. Paulus, S. C. *Palliative care: An ethical obligation*. Available at <https://www.scu.edu/ethics/focus-areas/bioethics/resources/palliative-care-an-ethical-obligation/>. Accessed 4 Oct 2018.
19. Blood in Urine (Haematuria). Available at <https://www.mayoclinic.org/diseases-conditions/blood-in-urine/symptoms-causes/syc-20353432>. Accessed 4 Oct 2018.
20. <https://www.uptodate.com/contents/etiology-and-evaluation-of-hematuria-in-adults>. Accessed 4 Oct 2018.
21. Beard, J. R., Officer, A., de Carvalho, I. A., et al. (2016). The World report on ageing and health: A policy framework for healthy ageing. *Lancet (London, England)*, 387(10033), 2145–2154. [https://doi.org/10.1016/S0140-6736\(15\)00516-4](https://doi.org/10.1016/S0140-6736(15)00516-4).
22. Kim, S., Brooks, A. K., & Groban, L. (2015). Preoperative assessment of the older surgical patient: honing in on geriatric syndromes. *Clinical Interventions in Aging*, 10, 13–27. <https://doi.org/10.2147/CIA.S75285>.
23. ECOG Performance status. Available at http://www.nprc.org/files/news/ECOG_performance_status.pdf. Accessed 4 Oct 2018.
24. *ECOG Performance Status – ECOG-ACRIN*. Available at <https://ecog-acrin.org/resources/ecog-performance-status>. Accessed 4 Oct 2018.
25. Yafi, F. A., & Kassouf, W. (2009). Radical cystectomy is the treatment of choice for invasive bladder cancer. *Canadian Urological Association Journal*, 3(5), 409–412. <https://doi.org/10.5489/cuaj.1156>.
26. Fagundes, C. P., Gillie, B. L., Derry, H. M., Bennett, J. M., & Kiecolt-Glaser, J. K. (2012). Resilience and immune function in older adults. *Annual Review of Gerontology and Geriatrics*, 32(1), 29–47.

27. Taylor, J. A., & Kuchel, G. A. (2009). Bladder cancer in the elderly: clinical outcomes, basic mechanisms, and future research direction. *Nature Clinical Practice Urology*, 6(3), 135–144. <https://doi.org/10.1038/ncpuro1315>.
28. National Cancer Institute. *Cancer genomics research*. Available at <https://www.cancer.gov/research/areas/genomics>. Accessed 4 Oct 2018.
29. *Bladder cancer risk factors*. Available at <https://www.cancer.org/cancer/bladder-cancer/causes-risks-prevention/risk-factors.html>. Accessed 4 Oct 2018.
30. Jolie, A. *My medical choice*. Available at <https://www.nytimes.com/2013/05/14/opinion/my-medical-choice.html>. Accessed 8 Mar 2019.
31. Salzman, B., Beldowski, K., & de la Paz, A. (2016). Cancer screening in older patients. *American Family Physician*, 93(8), 659–667.
32. Lee, S. J., Leipzig, R. M., & Walter, L. C. (2013). “When will it help?” Incorporating lagtime to benefit into prevention decisions for older adults. *JAMA*, 310(24), 2609–2610. <https://doi.org/10.1001/jama.2013.282612>.
33. World Health Organization. *Early detection of cancer*. Available at <http://www.who.int/cancer/detection/en/>. Accessed 4 Oct 2018.

Open Access This chapter is licensed under the terms of the Creative Commons Attribution 4.0 International License (<http://creativecommons.org/licenses/by/4.0/>), which permits use, sharing, adaptation, distribution and reproduction in any medium or format, as long as you give appropriate credit to the original author(s) and the source, provide a link to the Creative Commons license and indicate if changes were made.

The images or other third party material in this chapter are included in the chapter’s Creative Commons license, unless indicated otherwise in a credit line to the material. If material is not included in the chapter’s Creative Commons license and your intended use is not permitted by statutory regulation or exceeds the permitted use, you will need to obtain permission directly from the copyright holder.

