

Dairy Cattle Sub-clinical Uterine Disease Diagnosis Using Pattern Recognition and Image Processing Techniques

Matías Tailanián¹, Federico Lecumberry¹, Alicia Fernández¹, Giovanni Gnemmi², Ana Meikle³, Isabel Pereira³, and Gregory Randall¹

¹ Facultad de Ingeniería, Universidad de la República, Montevideo, Uruguay

² Bovinevet, Cressa, Italia

³ Facultad de Veterinaria, Universidad de la República, Montevideo, Uruguay

Abstract. This work presents a framework for diagnosing sub-clinical endometritis, a common uterine disease in dairy cattle, based in the analysis of ultrasound images of the uterine horn. The main contribution consists in the feature extraction proposal, based on the characteristics that the expert takes into account for diagnosing, such as statistics measures, image textures, shape, custom thickness measures and histogram, among others. Given the segmentation of the different regions of the uterine horn, a fully automatic supervised classification is performed, using a model based on C-SVM. Two different datasets of ultrasound images were used, acquired and tagged by an expert. The proposed framework shows promising results, allowing to consider the development of a complete automatic procedure to measure morphological features of the uterine horn that may contribute in the diagnosis of the pathology.

Keywords: Ultrasound images, feature extraction, Support Vector Machine, classification, endometritis, diagnosis, imbalance classes.

1 Introduction

Postpartum uterine diseases, such as uterus damage and ovarian cyclic activity disruption, has become one of the most important causes of reproductive inefficiency in dairy cattle and are associated with infertility [23,3]. Endometritis is an uterine disease defined as a chronic inflammation limited to the endometrium, which is not associated with systemic illness [22,24]. Clinical endometritis is characterized by the presence of purulent (>50%) or muco-purulent uterine exudate in the vagina, twenty one or more days postpartum and is not accompanied by systemic signs. Ultrasonography (US) images are widely used for endometritis diagnose, but this technique gets special relevance while detecting sub-clinical endometritis, since there is no visible material in vagina [12,11]. In this cases, the diagnosis is very difficult even for an expert, thus image processing techniques becomes an important help for veterinarians.

Sub-clinical endometritis can be diagnosed accurately by either cytologically (cytobrush and uterine lavage technique) or histologically (biopsy) [14,9], but some authors have questioned these methods because they are invasive, expensive and time consuming [17,7].

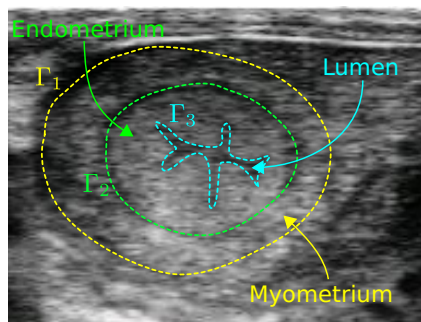


Fig. 1. Definitions. A schematic representation of the problem in a real example of the application is shown. The region between Γ_1 and Γ_2 is called *myometrium*, the region between Γ_2 and Γ_3 *endometrium* and the region inside Γ_3 *lumen*.

ing pattern recognition techniques. The main contribution consists in the feature extraction proposal, based on the characteristics considered by the expert for the diagnosis, such as texture, echogenicity (pixel intensities depending on the absorption/reflection of US waves) and shapes, among others. The diagnose of the expert is used to train our model in a supervised classification in two classes: sick and healthy cattle. The features used for the classification are based on the most relevant characteristics used by the expert, and tries to emulate his criteria. The trained algorithm is used to predict, based on the extracted features, the cow's condition.

Diagnosis based on US images is widely used in the literature to diagnose several kind of diseases. Usually, these solutions are particular for a specific application. In [26,27], US images are used to detect a liver disease in dairy cattle, hepatic steatosis, using image processing techniques and the result of the biopsy as a gold standard. Also, US imaging diagnosis is used for human diseases, in [16], Fourier-based shape features were extracted to implement a computer-aided US diagnosis system to detect breast tumors. In addition, US imaging can be also used for segmentation. In [2], shape priors combined with machine learning and image processing components are used to measure the rib eye area.

The remainder of the paper is organized as follows. Section 2 describes the framework, Section 3 presents the experiments and results, and some conclusions and future work are shown in Section 4.

2 Framework

The proposed framework consists of three modules: (1) pre-processing and normalization, (2) feature extraction and selection, and (3) classification. This work focuses in the feature extraction stage, reproducing the expert evaluation of the diagnostic and using machine learning algorithms over the US images to infer

The diagnosis of the sub-clinical endometritis using US images is based on the appearance of the uterus layers (myometrium and endometrium) and the presence and quality of the uterine fluid. Figure 1 shows an image of a transversal cut of the uterine horn: the myometrium is the region delimited by curves Γ_1 and Γ_2 and the endometrium is the region delimited by curves Γ_2 and Γ_3 .

This work presents a method to aid veterinaries in endometritis diagnose, based on US images of a transversal cut of the uterine horn. We present a strategy to make the automatic diagnosis based on segmented images, using

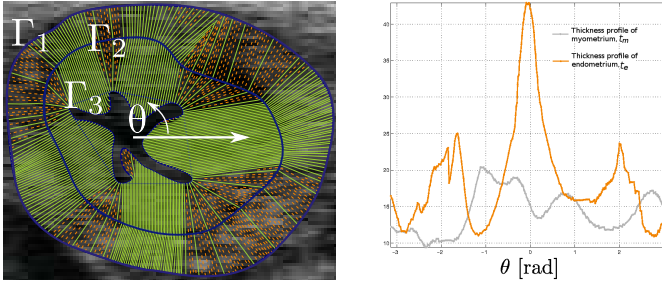


Fig. 2. Thickness profile measurement. Left: path of the evolved points. Green solid lines corresponds to the path of the original points of the curve, and orange dashed lines corresponds to points created during evolution to ensure a good sampling of the curve at each step. Right: thickness profile obtained. This graphic shows the thickness of myometrium (t_m) and endometrium (t_e) as a function of the angle in radians (θ), shown at left.

the composition or biological content of the different regions of the uterine horn, in order to identify the anatomic characteristics that are taken into account by the expert for diagnosing. An automatic classification method was implemented using the segmented US images, based on the C-SVM algorithm.

2.1 Features Extraction and Selection

The sub-clinical endometritis is characterized by the thickness of endometrium (> 8 mm) and thickness of the lumen of the uterus (> 3 mm) [3], but those features are not enough for diagnosing. These thicknesses should be considered together with myometrium thickness and their echogenicities. For this reason the measure of echogenicity and thickness becomes relevant features to distinguish this disease from some normal physiological situations.

In order to measure the thickness of the myometrium and endometrium, we implemented an algorithm based on the normal evolution of the curves delimiting these regions (Γ_1 , Γ_2 and Γ_3) that, adding mechanisms of creating and combining points during evolution, ensures a good representation of the curve in each step [25]. This algorithm provides an entire thickness profile of the regions and leads to an intuitive thickness definition (see Figure 2). Let $t_e(\theta)$ and $t_m(\theta)$ be the thickness profile of endometrium and myometrium respectively, $\theta_e = \arg \max_{\theta} (t_e)$, and $\theta_m = \arg \max_{\theta} (t_m)$. The thickness profile is used to extract various features intending to capture the useful information needed:

- $t_e(\theta_e)/t_m(\theta_e)$: captures a localized inflammation of the endometrium.
- $t_e(\theta_e)/\text{area}(\Gamma_1)$: measures the maximum “portion” of the uterine horn occupied by the endometrium.
- $t_e(\theta_e)/(\text{area}(\Gamma_2) - \text{area}(\Gamma_3))$
- $t_e(\theta_e)/t_m(\theta_m)$
- $t_m(\theta_m)/\text{area}(\Gamma_1)$ captures the relative thickness of the myometrium.

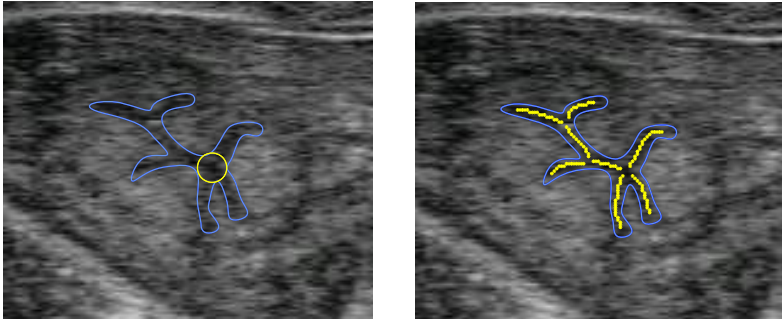


Fig. 3. Features extracted to measure lumen thickness. In blue the Γ_3 curve delimits the lumen. Left: in yellow the lumen inner osculating circle. Right: in yellow the lumen skeleton.

The thickness of the lumen is also a good descriptor for diagnosing endometritis [3]. Therefore we computed two more features intending to capture this characteristics: the radius of the biggest inner osculating circle and the average distance between points of Γ_3 to the lumen skeleton (Figure 3).

The presence of endometritis implicates the inflammation of uterus, and in the case of clinic endometritis the inflammation can be easily seen as a purulent or muco purulent fluid inside the lumen [15,23,12,10,11]. The mucus appears as a whiter region, because of higher reflectance of US waves. We propose two other descriptors to capture this effect, one based on histogram capturing the number of modes presents, and the other based on a texture descriptor: LBP [1].

2.2 Classifier

While diagnosing this kind of diseases, the number of infected cows is significantly lower than the number of healthy ones; this problem is well known as the *class imbalance problem*. In this cases, standard classifiers tend to classify all samples as belonging to the majority class. To overcome this difficulty we used a weighted-cost learning, which assigns a higher cost to the misclassification of a sample of the minority class. Another problem while working with highly unbalanced classes is that most widely used metrics to evaluate the performance, such as *accuracy* and *error rate* do not take into account those weights, favoring the majority class [8]. Other metrics, such as F_{value} [18], takes into account the imbalance problem:

$$Recall : R^p = \frac{TP}{TP + FN}, \quad Precision : P = \frac{TP}{TP + FP}, \quad F_{value}(\beta) = (1 + \beta^2) \times \frac{R^p \times P}{\beta^2 \times R^p + P} \tag{1}$$

	Classified as sick	Classified as healthy
Truly sick	TP (true positive)	FP (false positive)
Truly healthy	FN (false negative)	TN (true negative)

Therefore we decided to use $F_{value}(1)$ as the performance measure, instead of accuracy or error rate. Also, as one of the datasets used presented highly

imbalanced classes, we decided to over-sample the minority class, creating synthetic samples by using the SMOTE technique [4].

In this sense, a classification using C-SVM [21] with a RBF Kernel was performed, assigning a higher cost to the misclassification of the samples of the minority class. The parameter selection was made using Grid Search technique, analyzing the variation of parameters C of C-SVM and γ of the RBF kernel.

3 Experiments and Results

3.1 Datasets

Two different datasets were used. **Dataset 1:** Consists in 252 images captured in two different Uruguayan dairy farms using *Imago ECM (90-1945) Ultrasound Scanner* with the *lineal rectal sonda LB760P*. **Dataset 2:** Consists in 144 images captured in different dairy farms in North Italy, using the *Imago ECM Angouleme France Ultrasound Scanner*.

All cows analyzed were in any part of the estrous cycle, as long as there have passed at least twenty one days from the last delivery. All images were labeled (diagnosed) by the expert in order to use it as a gold standard for evaluating our algorithm, and manually segmented by the same person.

3.2 Performance Analysis

The absence of lumen in the US image is a binary indicator of endometritis. If no lumen is present in the image, the cow is healthy. Since our segmentation is done manually, the cows with no lumen present in the images are not considered in the automatic analysis. All results shown in this section are based only in images with lumen present. If we include all images, our performance indexes would rise.

As we said previously, we used $F_{value}(1)$ as the performance measurement in order to contemplate the imbalance problem.

Correlation. As a measure of correlation between the features and the labels we propose to use the Pearson correlation coefficient (R) [13].

In *dataset 1*, the correlation of the proposed features were slightly low, $R(i) \sim 0.3$. The best two features are the ones related to lumen thickness and the maximum thickness of endometrium normalized by the area. Using *dataset 2* the results are quite different, with higher correlations ($R(i) \sim 0.8$). The best features are related with the image data, such as descriptors of texture, followed by the lumen and endometrium thickness features.

The fact that the most correlated features depends on the dataset can be explained by the quality of the images in each dataset. Images of *dataset 2* have better definition, contrast and clearer textures. In order to exemplify this, Figure 4 shows typical images of both datasets. Example image from *dataset 1* is clearly blurred making the segmentation procedure very difficult even for an expert, and

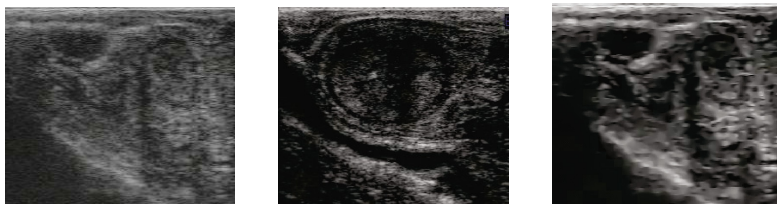


Fig. 4. Comparison between quality of both datasets. Both images corresponds to sick cows. Left: Example image of *dataset 1*. Middle: Example image of *dataset 2*. Right: anisotropic diffusion applied to the example image of *dataset 1*.

Table 1. 10-fold cross validation results

	Dataset 1		Dataset 2
	Without SMOTE	With SMOTE	
Correctly classified	181/252	346/400	142/144
Accuracy	0.7183	0.8650	0.9861
Precision	0.4423	0.9300	0.9855
Recall	0.3538	0.8230	0.9855
F-Value	0.4423	0.930	0.9855

shattering the texture structures. In order to overcome this problem, Anisotropic Diffusion [19] is considered. In this case the contrast is enhanced but texture destroyed (see Figure 4), so it is used only to aid in the manual segmentation.

Classification. To perform the evaluation a 10-fold cross validation was used; the optimal parameters (C and γ) were computed in each fold. The results of the classification obtained in each dataset are shown in Table 1, which shows a big difference in the performance of each dataset. This can be explained since the image related features, such as texture or LBP, present lower correlation with the labels in *dataset 1* because of its low quality, degrading the overall performance of the classifier. Also, *dataset 1* presents the most imbalanced classes, which causes a clear performance degradation. As can be seen, using SMOTE the results for this dataset are widely enhanced. On the other hand, in *dataset 2* the whole set of features provides a better discrimination, leading to a satisfactory performance.

4 Conclusions and Future Work

This work presents a machine learning application for the detection of endometritis in dairy cattle. An important part of this work is based on the analysis of anatomy and biology of the animals, in order to develop a feature extraction stage, that intends to describe the expert analysis in the diagnosis of the mentioned disease.

No cattle pre-selection was applied for this study, therefore intrinsic imbalance between classes is present, giving a snapshot of the state of cattle in visited farms. This classes imbalance plays an important role in the classification step, and is considered in the design of the classifier. Also an over-sampling technique (SMOTE) was used to overcome this problem in *dataset 1*.

The complete framework obtains successful results, suggesting that the feature extraction stage is capable of capture and discriminate the relevant characteristics for the classification.

This work is focused in interpretation of the relevant biological characteristic for endometritis diagnose, and the feature extraction that captures this information. As future work we plan to evaluate the performance with more sophisticated classification algorithms, such as LFS [5] or OFS [6]. Although the manual segmentation could be done by any minimally trained person, not necessarily veterinarian, we plan to implement a completely automatic classification system, including an automatic segmentation by adding shape priors, such as the one performed in [2].

As far as we know this is the first report of the use of an algorithm to predict uterus health. Taking into account the controversial definitions of sub-clinical endometritis and the difficulty in the diagnosis of sub-clinical endometritis, the automatic classification of the disease by image analysis may aid in the precision of the diagnosis as well as in the training of the veterinarians. Moreover, considering the massive use of drugs to treat postpartum uterine diseases in dairy cows (mainly that have been considered unnecessary, [20]) this may contribute to a more rational use of drugs especially in the dairy industry, which products are for human consumption.

Acknowledgments. This work was partially supported by grant ANII FMV 2_2011_1_7376.

References

1. Ahonen, T., Hadid, A., Pietikainen, M.: Face description with local binary patterns: Application to face recognition. *IEEE Transactions on Pattern Analysis and Machine Intelligence* 28(12), 2037–2041 (2006)
2. Arias, P., Sprechmann, P., Pini, A., Sanguinetti, G., Cancela, P., Fernández, A., Gómez, A., Randall, G.: Ultrasound image segmentation with shape priors: Application to automatic cattle rib-eye area estimation. *IEEE Transactions on Image Processing* 16(6), 1637–1645 (2007)
3. Barlund, C., Carruthers, T., Waldner, C., Palmer, C.: A comparison of diagnostic techniques for postpartum endometritis in dairy cattle. *Theriogenology* 69, 714–723 (2008)
4. Chawla, N.V., Bowyer, K.W., Hall, L.O., Kegelmeyer, W.P.: Smote: synthetic minority over-sampling technique. *arXiv preprint arXiv:1106.1813* (2011)
5. Di Martino, M., Fernández, A., Iturralde, P., Lecumberry, F.: Novel classifier scheme for imbalanced problems. *Pattern Recognition Letters* 34(10), 1146–1151 (2013)
6. Di Martino, M., Hernández, G., Fiori, M., Fernández, A.: A new framework for optimal classifier design. *Pattern Recognition* 46(8), 2249–2255 (2013)
7. Dolezel, R., Vecera, M., Palenik, T., Cech, S., Vyskocil, M.: Systematic clinical examination of early postpartum cows and treatment of puerperal metritis did not have any beneficial effect on subsequent reproductive performance. *Veterinarni Medicina* 53(2), 59 (2008)
8. Garcia, V., Sánchez, J.S., Mollineda, R.A.: On the suitability of numerical performance measures for class imbalance problems. In: *International Conference in Pattern Recognition Applications and Methods*, pp. 310–313 (2012)

9. Gilbert, R.O., Shin, S.T., Guard, C.L., Erb, H.N., Frajblat, M.: Prevalence of endometritis and its effects on reproductive performance of dairy cows. *Theriogenology* 64(9), 1879–1888 (2005)
10. Gnemmi, G.: Ultrasonography in bovine reproduction. Seminar of Poland Buiatric Association (2012)
11. Gnemmi, G., Ferrari, E., Maraboli, C.: Endometrite clinica e subclinica. Significato della diagnosi e prospettive terapeutiche. *Summa Veterinaria*, pp. 1–7 (September 2013)
12. Gnemmi, G., Maraboli, C.: Endometrite subclinica nel bovino da latte. *Summa Veterinaria*, pp. 38–42 (August 2010)
13. Guyon, I., Elisseeff, A.: An introduction to variable and feature selection. *The Journal of Machine Learning Research* 3, 1157–1182 (2003)
14. Khan, J.A., Kumar, P., Paramasivam, M., Yadav, R.S., Sahani, M.S., Sharma, S., Srinivasan, A., Singh, T.P.: Camel lactoferrin, a transferrin-cum-lactoferrin: crystal structure of camel apolactoferrin at 2.6 Å resolution and structural basis of its dual role. *Journal of Molecular Biology* 309(3), 751–761 (2001)
15. LeBlanc, S., Duffield, T., Leslie, K., Bateman, K., Keefe, G.P., Walton, J., Johnson, W.: Defining and diagnosing postpartum clinical endometritis and its impact on reproductive performance in dairy cows. *Journal of Dairy Science* 85(9), 2223–2236 (2002)
16. Lee, J.H., Seong, Y.K., Chang, C.H., Park, J., Park, M., Woo, K.G., Ko, E.Y.: Fourier-based shape feature extraction technique for computer-aided b-mode ultrasound diagnosis of breast tumor. In: Annual International Conference of the IEEE Engineering in Medicine and Biology Society (EMBC), pp. 6551–6554 (2012)
17. Lewis, G.S.: Uterine health and disorders. *Journal of Dairy Science* 80(5), 984–994 (1997)
18. Manning, C.D., Raghavan, P., Schütze, H.: Introduction to information retrieval, vol. 1. Cambridge University Press, Cambridge (2008)
19. Perona, P., Malik, J.: Scale-space and edge detection using anisotropic diffusion. *IEEE Transactions on Pattern Analysis and Machine Intelligence* 12, 629–639 (1990)
20. Pol, M., Ruegg, P.: Treatment practices and quantification of antimicrobial drug usage in conventional and organic dairy farms in wisconsin. *Journal of Dairy Science* 90(1), 249–261 (2007)
21. Scholkopf, B., Smola, A.: Learning with kernels (2002)
22. Sheldon, I.M., Lewis, G.S., LeBlanc, S., Gilbert, R.O.: Defining postpartum uterine disease in cattle. *Theriogenology* 65(8), 1516–1530 (2006)
23. Sheldon, I.M., Williams, E.J., Miller, A.N., Nash, D.M., Herath, S.: Uterine diseases in cattle after parturition. *The Veterinary Journal* 176(1), 115–121 (2008)
24. Sheldon, I., Cronin, J., Goetze, L., Donofrio, G., Schuberth, H.: Defining Postpartum Uterine Disease and the Mechanisms of Infection and Immunity in the Female Reproductive Tract in Cattle 81(6), 1025–1032 (2010)
25. Tailanian, M., Lecumberry, F., Gnemmi, G.: Measuring thickness profile between closed curves applied to endometritis detection on in dairy cattle. Tech. rep., Facultad de Ingeniería, IIE - Project ANII FMV 2 2011 1 7376 (2014), <http://iie.fing.edu.uy/publicaciones/2014/TLG14>
26. Thijssen, J., Starke, A., Weijers, G., Haudum, A., Herzog, K., Wohlsein, P., Rehage, J., De Korte, C.: Computer-aided b-mode ultrasound diagnosis of hepatic steatosis: a feasibility study. *IEEE Transactions on Ultrasonics, Ferroelectrics and Frequency Control* 55(6), 1343–1354 (2008)
27. Thijssen, J., Weijers, G., Starke, A., Haudum, A., Herzog, K., Rehage, J., De Korte, C.: Non-invasive staging of hepatic steatosis using computer-aided ultrasound diagnosis. In: Ultrasonics Symposium, IUS 2008, pp. 1987–1990. IEEE (November 2008)