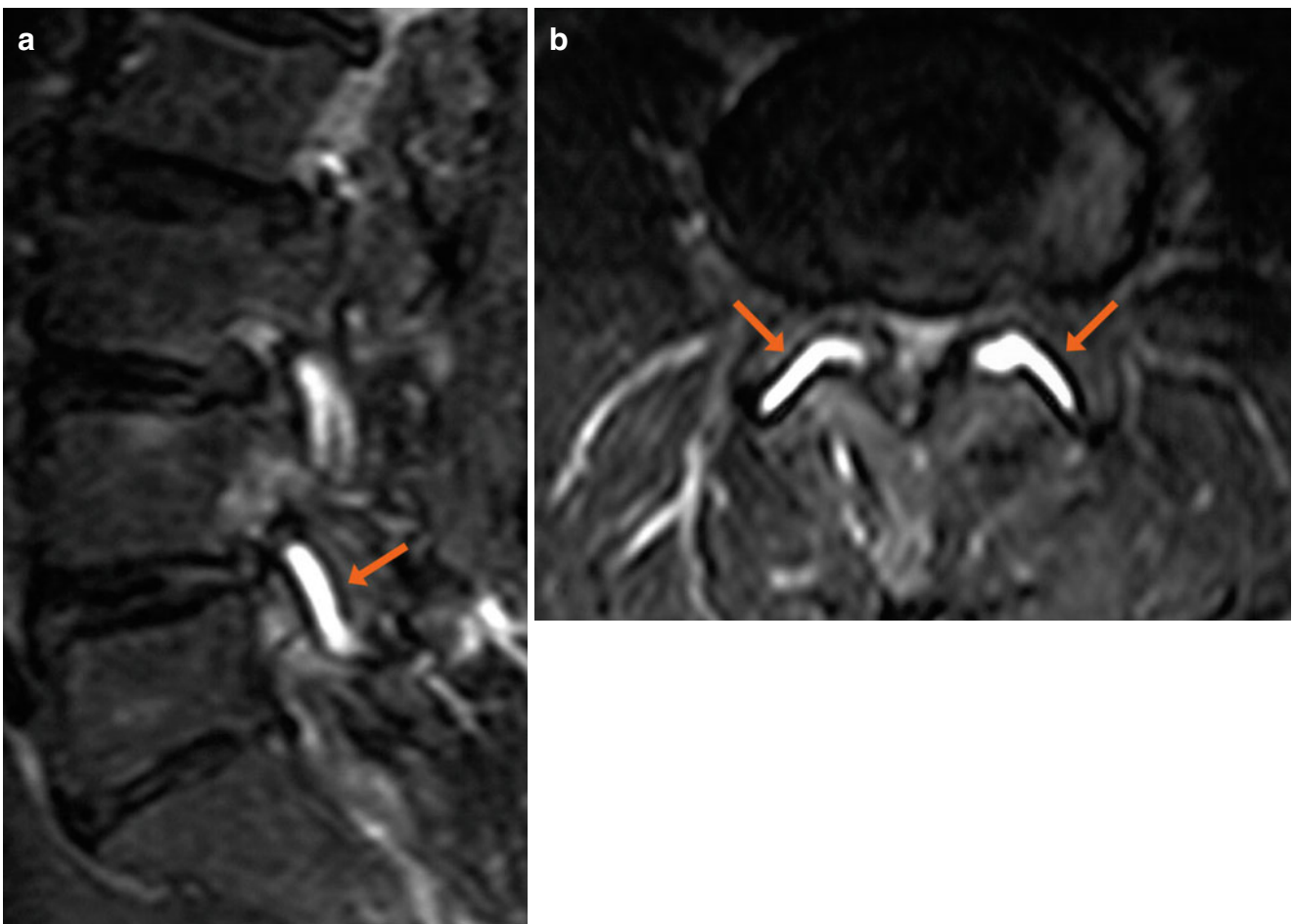


- A 68-year old male
- Chronic low back pain, exacerbated by flexion and extension
- History of chronic dorsal and lumbar pain



**Fig. 1** (a, b) Sagittal and axial TSE T2-weighted images with fat saturation (a, b). Facet joint effusion at L4/L5 bilaterally, with widening of the joint spaces (*arrows*)