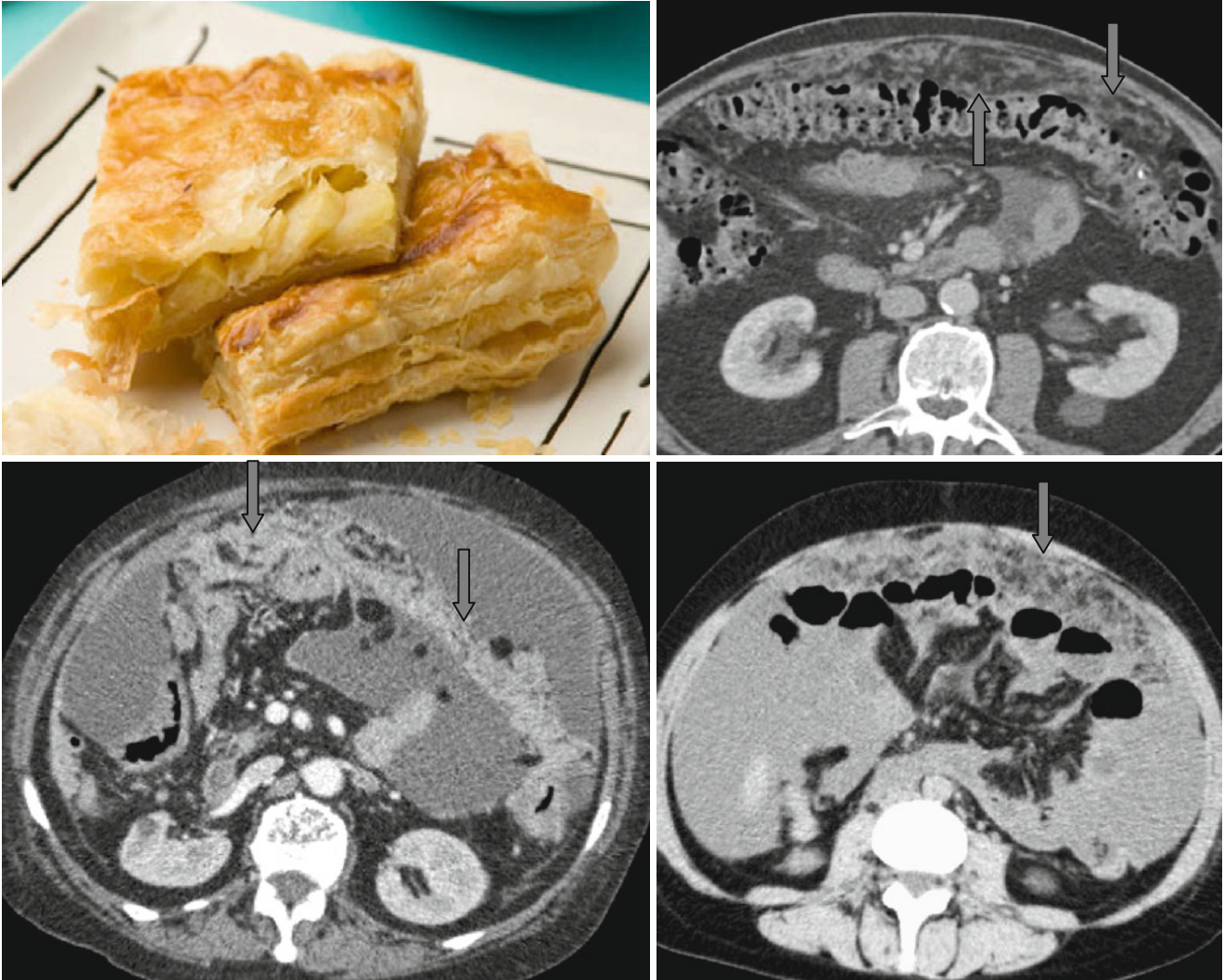


Omental Cake Sign



The pathologically thickened and infiltrated omentum forms the “*omental cake*” sign on tomograms (↑). After IV injection of contrast agent, the omentum enhances irregularly and shows the cellular structure imitating a layer cake. The most frequent causes for infiltration of the large omentum

are metastases from carcinomas of the ovaries, stomach, and colon. Also similar images of omental infiltration can be found in tuberculous peritonitis and, extremely seldom, in primary tumors of the large omentum (mesothelioma in particular).