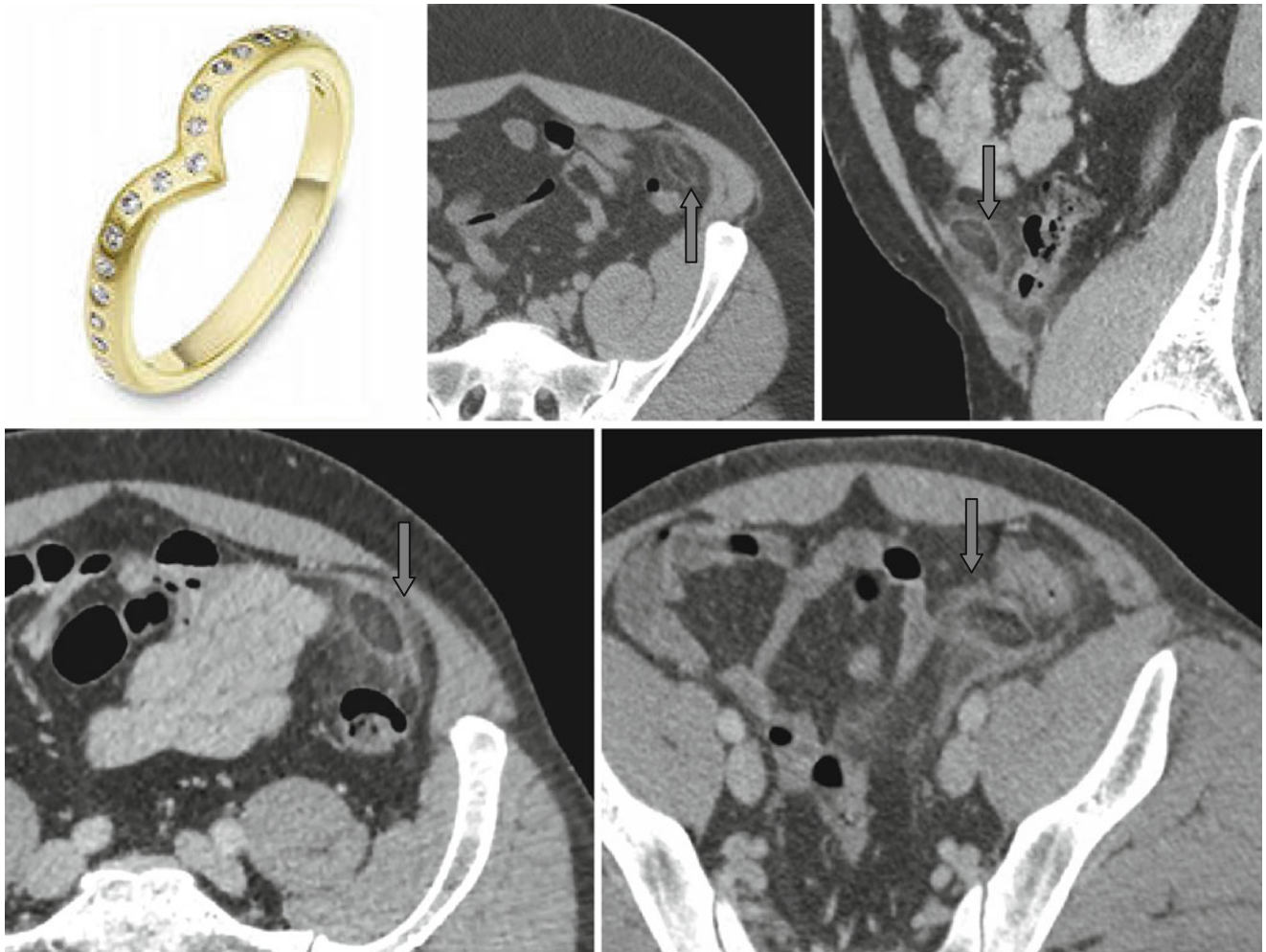


## Ring Sign



Acute inflammation or infarct of a mesenteric appendage (epiploic appendagitis) can be detected on tomograms as a structure of oval or irregular form containing fatty tissue and surrounded by a thin hyperdense ring – the “*ring*” sign

(↑). Signs of inflammation of surrounding fat can also be visible. A dense “point” may be seen in the center representing a thrombosed vein.