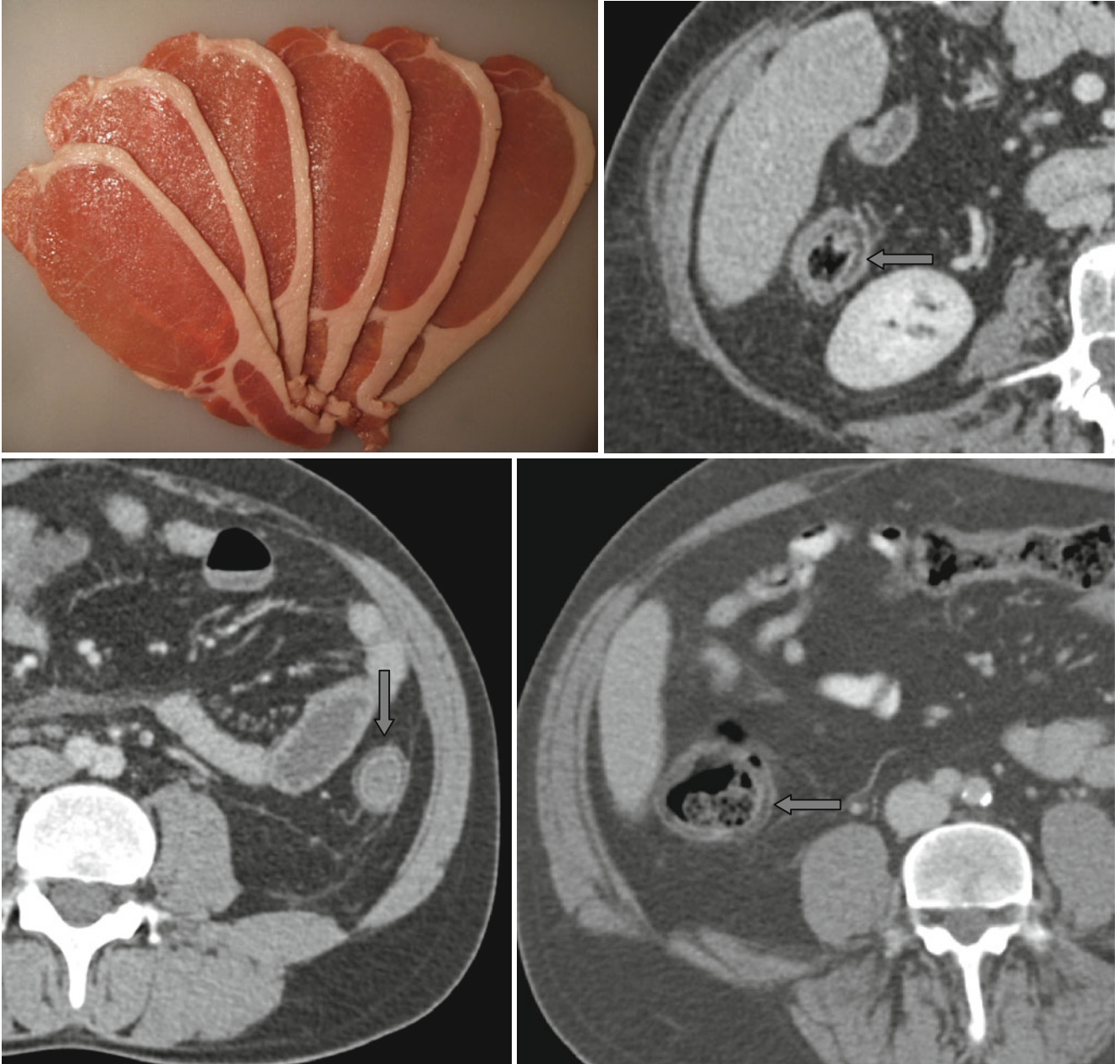


Fat Halo Sign



Fatty infiltration of the submucosal bowel layer – the “*fat halo*” sign (↑) – can be regarded as specific for inflammatory bowel diseases (Crohn disease, ulcerative colitis), but

unlike the “double halo” sign and the “target” sign, it indicates the chronic stage of disease.