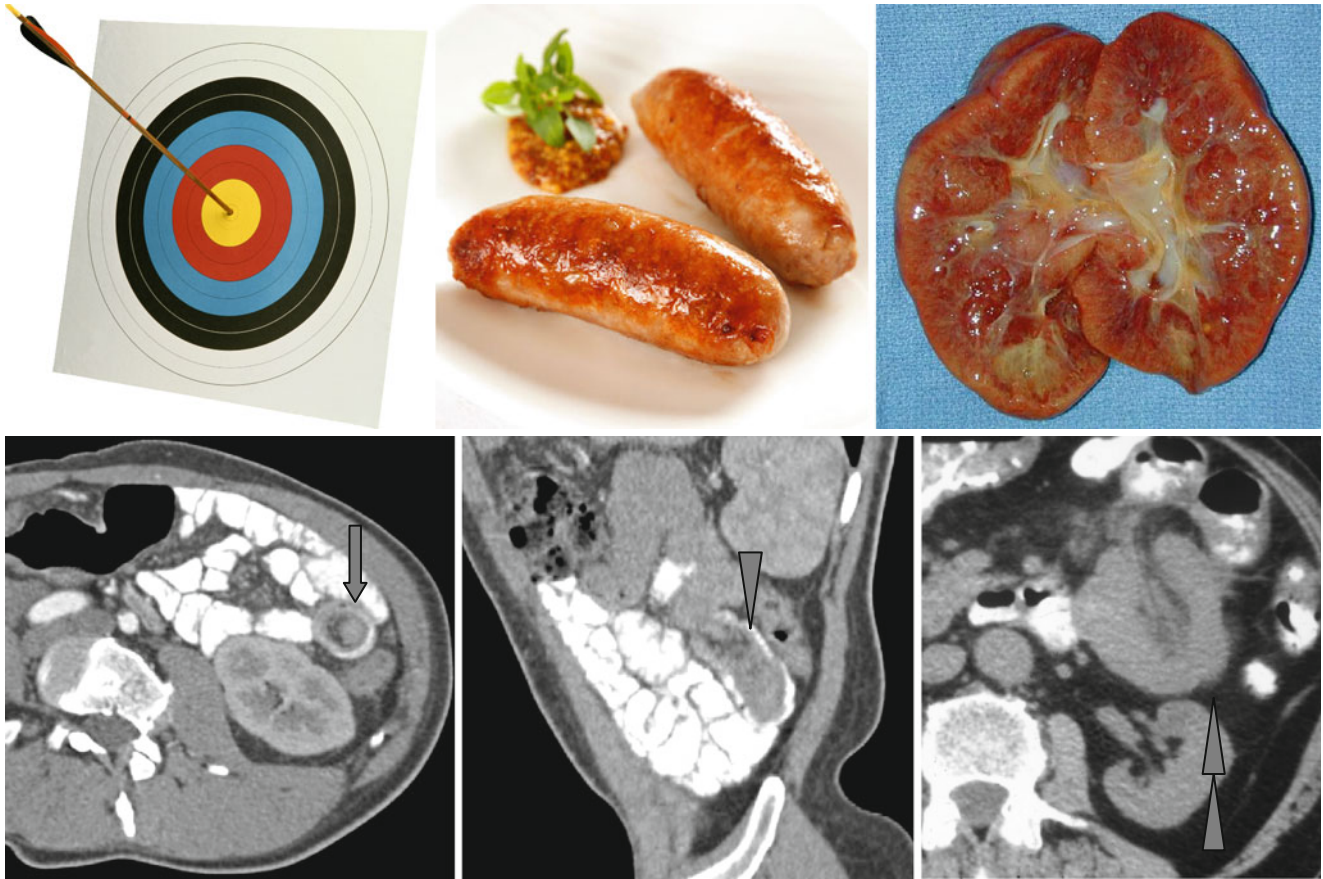


Target Sign, Sausage-Shaped Mass, and Reniform or Kidney-Shaped Bowel



Invagination is the prolapse of the intestine loop together with a part of the mesentery inside the neighboring segment of the bowel. Three variants of bowel image on tomograms are described with invaginations:

1. Soft tissue formation in the bowel with eccentric location of the mesentery with fatty density – the “target” sign (↑)
2. *Sausage-shaped mass* (Δ) with alternating sites of low and high density of the bowel wall, mesentery, fluid, gas, and contrast medium

3. *Reniform or kidney-shaped bowel* (▶▶) with thickened bowel walls and edematous mesentery

The first variant refers to initial manifestations with a minimal degree of obstruction, but the second and the third ones refer to late changes with ileus and ischemia.