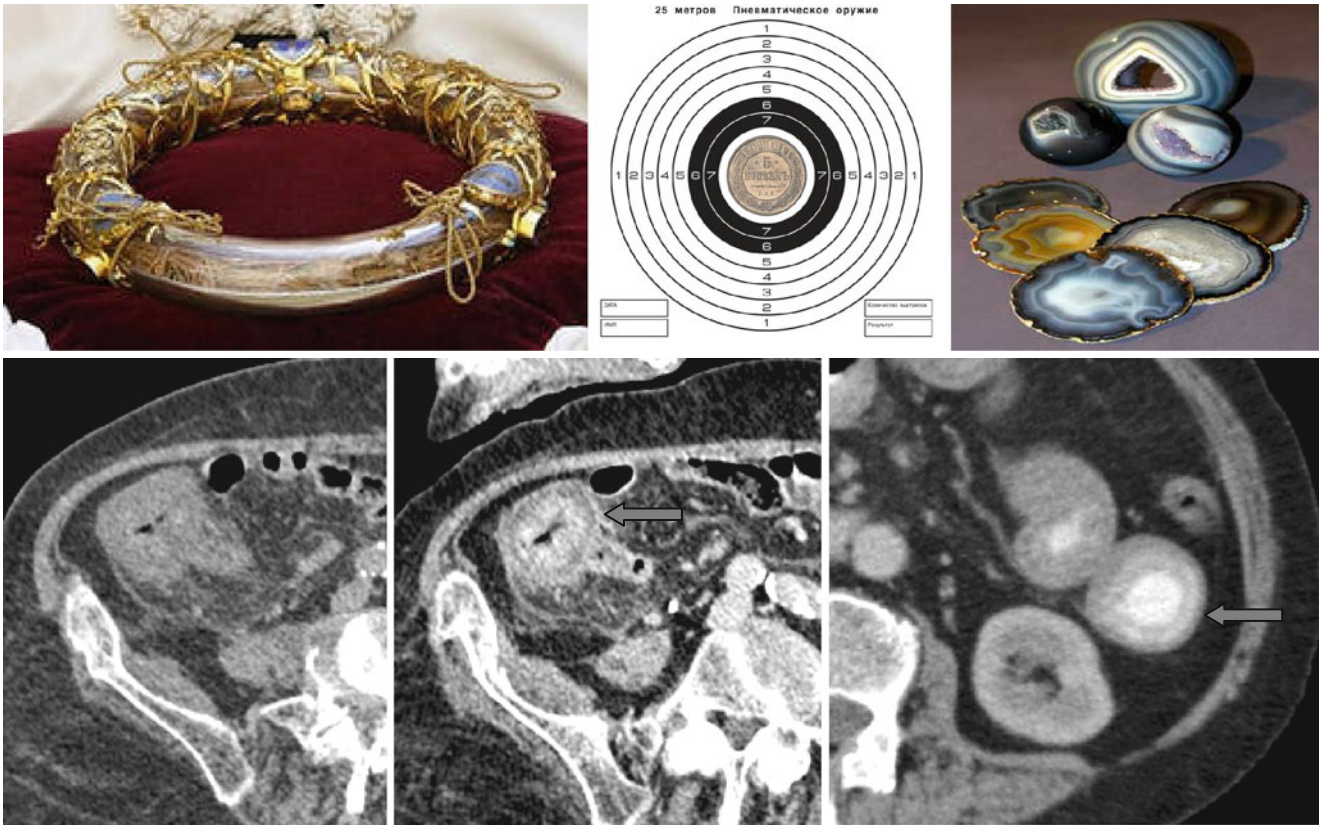


Stratified Attenuation, Double Halo Sign, and Target Sign



Stratified attenuation of bowel segments may take the form of a double circlet (with internal layer of low density and external layer of high density) forming the “*double halo*” sign or a target (with internal and external layers of high

density and middle zone of low density) forming the “*target*” sign (↑). These signs usually reflect acute inflammation or ischemia. The layers with high density mean hyperemia and the layers with low density mean edema.