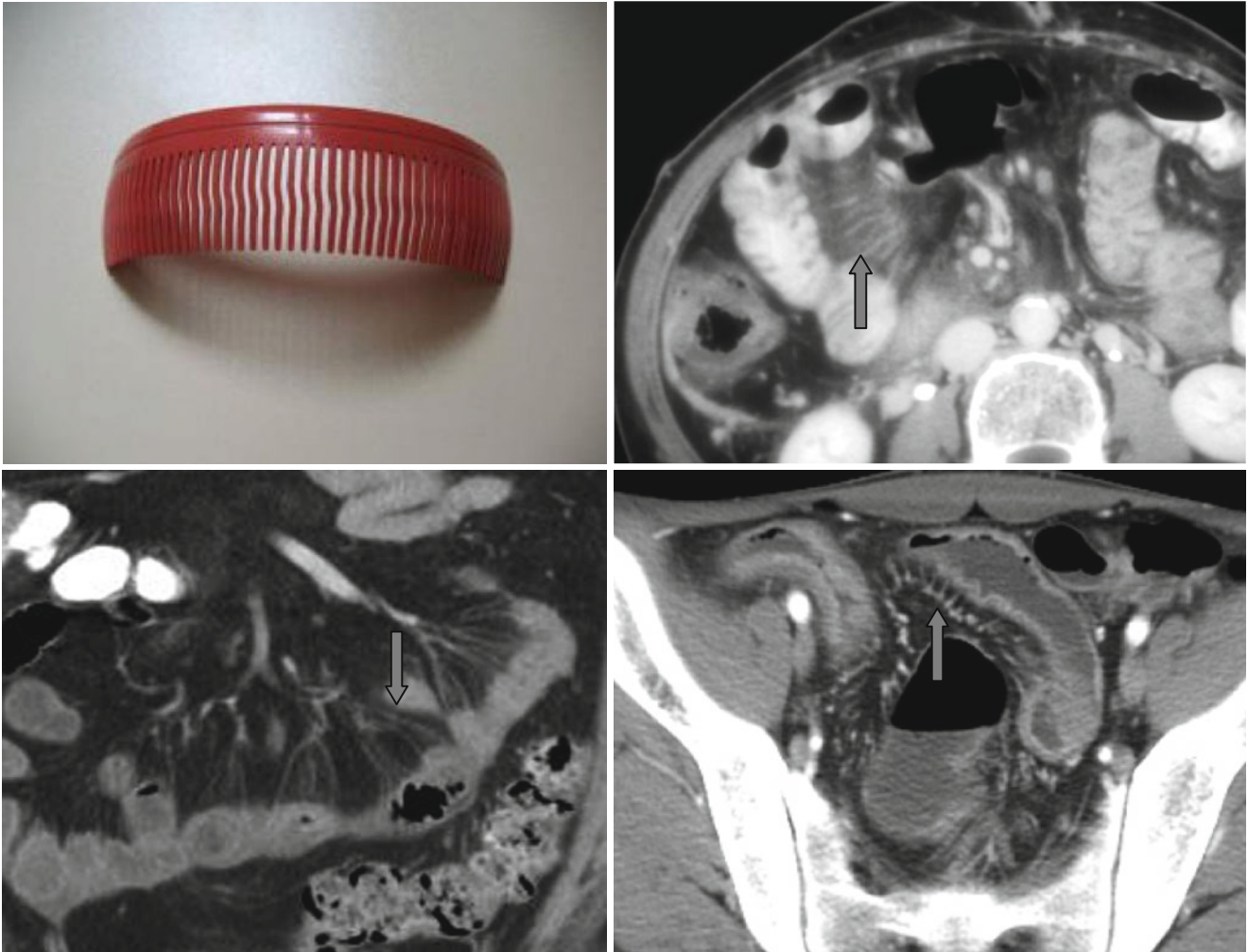


Comb Sign



The increases in mesenteric blood flow and perivascular inflammatory infiltration form the image of linear structures near the bowel on the side of the mesentery forming the

“*comb*” sign (↑). This sign is most often seen in Crohn disease and in ulcerative colitis. In any case it is the sign of active inflammatory process.