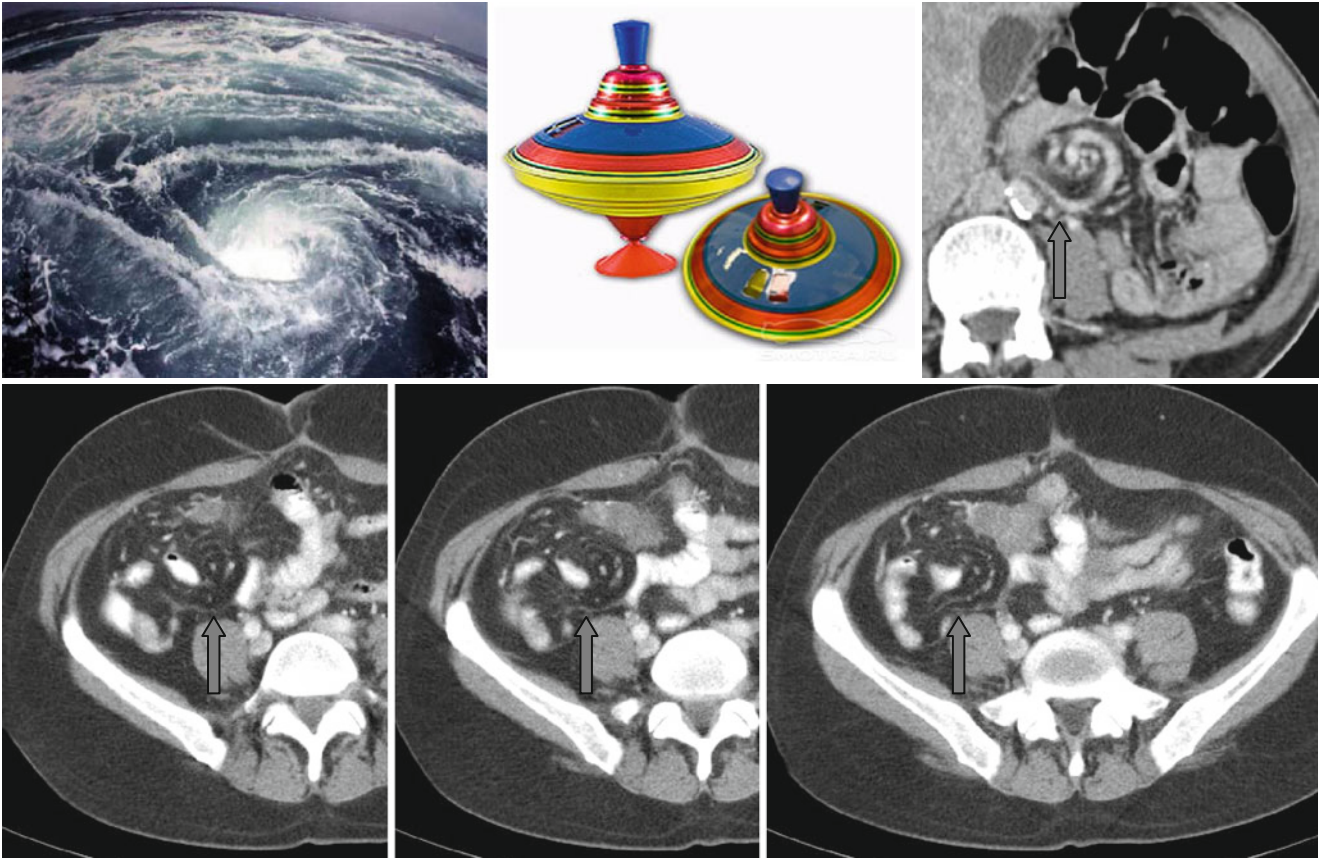


Whirlpool, Whirl, Swirl, and Whirling Sign



The “whirlpool” sign (also known as the “whirl,” “swirl,” and “whirling” sign) can be found in patients with small bowel volvulus (usually as a complication of bowel malrotation). On axial tomograms rotation of the intestine, mesentery, and superior mesenteric vein occurs around the superior mesenteric artery in a counterclockwise

direction (↑). Curved mesenteric vessels form the image of a whirlpool. This sign can be seen also at the cecal and sigmoid volvulus.

Most distinctly the rotation is distinguished when studying cine CT scans.