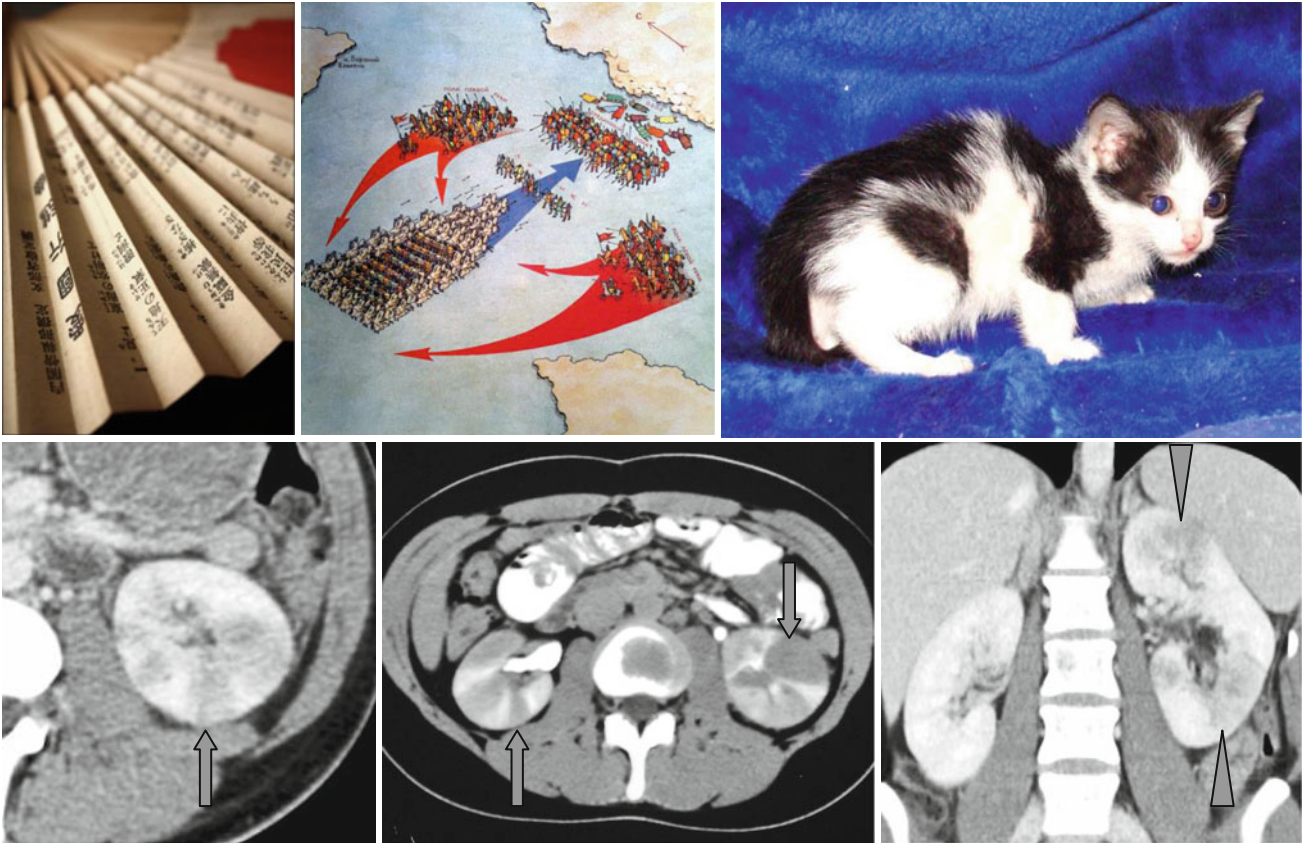


Fan Sign, Wedge-Shaped or Striated Enhancement, and Patchy Nephrogram



In acute pyelonephritis in the parenchymal phase of IV enhancement, fan- or wedge-like, striated, or patchy zones of low attenuation may be found forming the “fan” sign (↑), “wedge-shaped or striated enhancement”, or “patchy nephrogram” (Δ). These areas correspond to necrosis and

edema. In the delayed phase of enhancement, the zones of previously low density can slightly enhance. Similar changes in the kidneys occur in embolism, vasculitis, atherosclerosis, and trauma. Thus, clinical correlation is necessary for differentiation of these pathologic conditions.