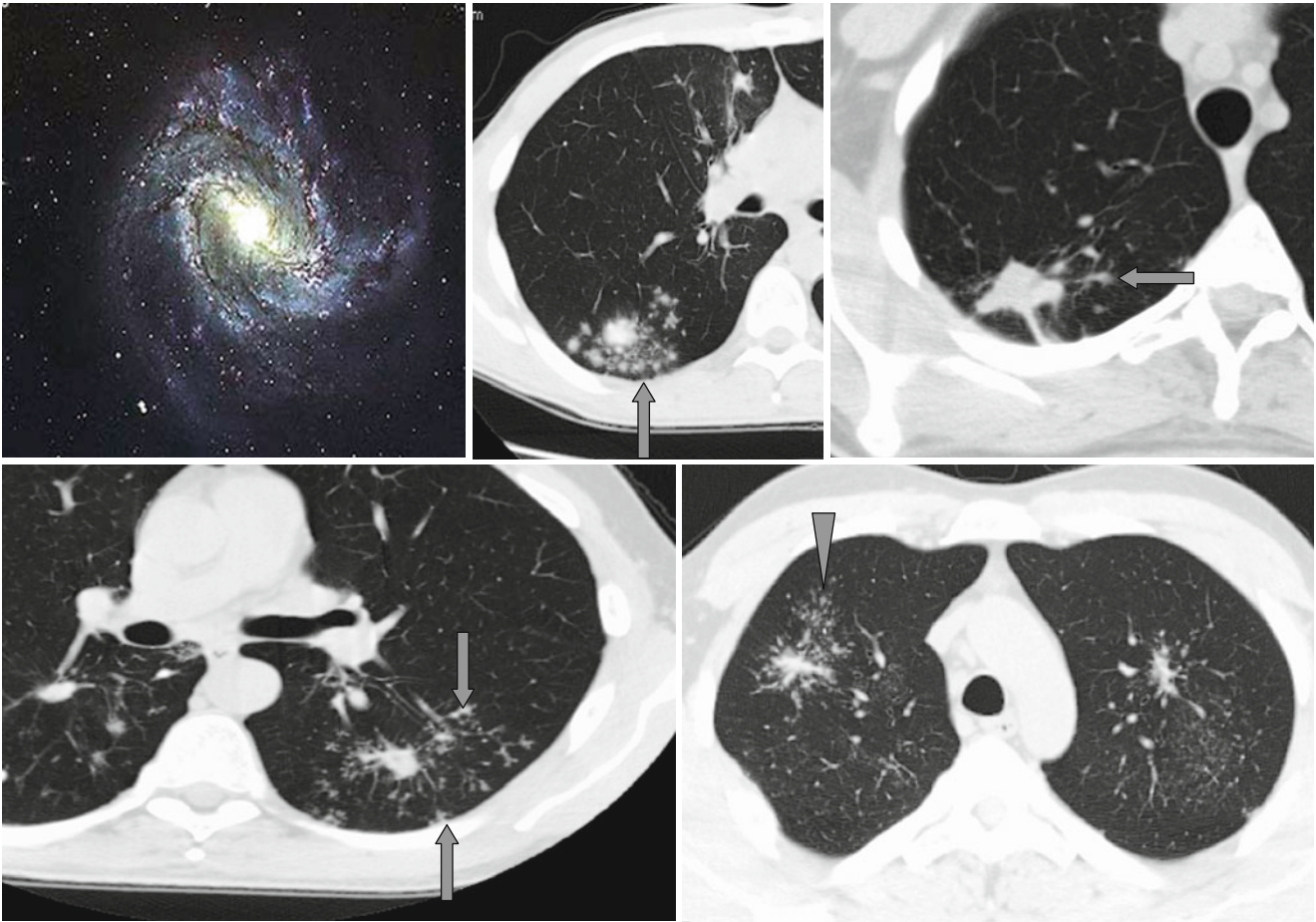


Satellite Foci and Galaxy Sign



The *satellite foci* (↑) can be found near lung nodules, and usually they are a sign of benign process (granulomatoses, tuberculosis). In patients with sarcoidosis the satellite

nodules are described as the “*galaxy*” sign (Δ). In rare cases the satellite nodules can also be found at carcinomas.