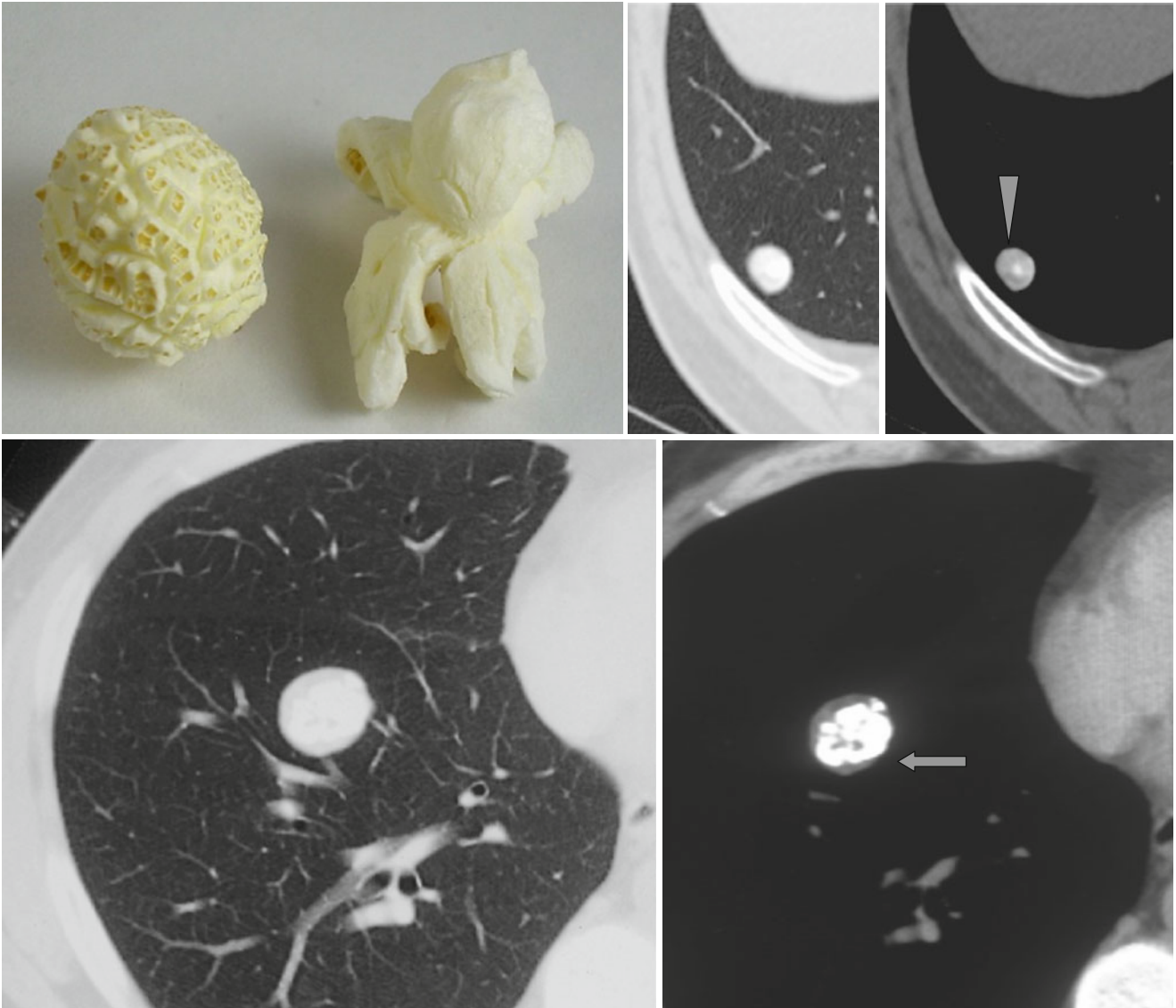


Popcorn Sign and Bull's Eye Calcifications



The conglomerate of formless calcifications occupying the central part of a lung nodule forms the “*popcorn*” sign (↑) characteristic of hamartoma. Dot-like calcification in the

center of a nodule is known as the *bull's eye calcification* (Δ) occurring in hamartomas and histoplasmosis, also possible in any granuloma.