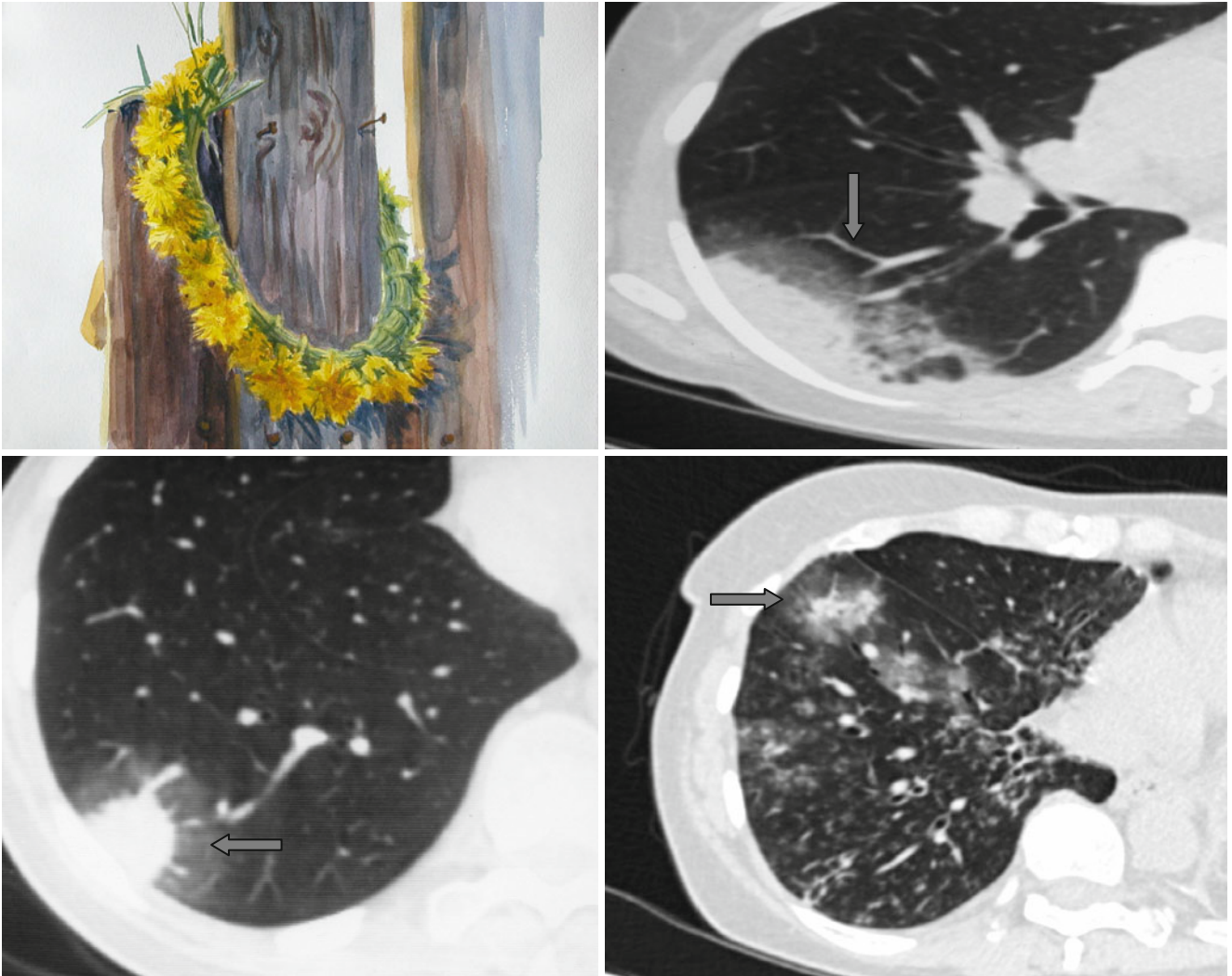


Halo Sign



The rim formed by a zone of “ground-glass” density (↑), which surrounds a consolidation or a group of nodules in a lung (the “halo” sign), can be seen in patients with aspergillosis (less common with other infections) and also around

adenocarcinomas (especially bronchoalveolar carcinomas). In aspergillosis, the halo is caused by hemorrhages. The halo around adenocarcinoma is formed by the tumor growth in the interstitial tissue.