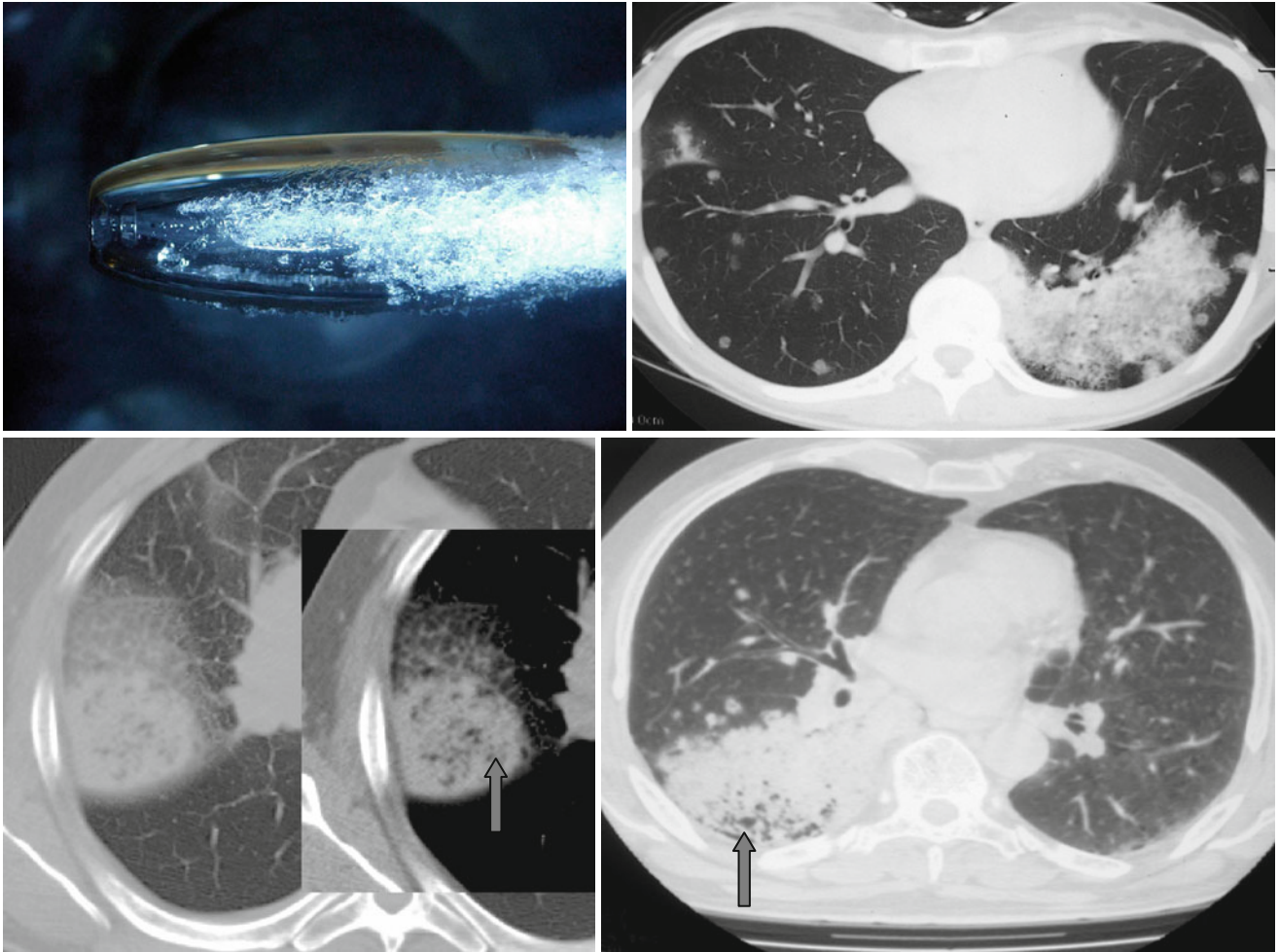


Air Bronchograms and Pseudocavitations



Air bronchograms and *pseudocavitations* (↑) are often visible in adenocarcinomas (bronchoalveolar carcinomas) and seldom occur in benign lung lesions. Air bronchograms can be also found in pneumonias, round atelectases, inside con-

glomerate masses in silicosis, and sarcoidosis. Fine lucencies against a neoplasm represent cystic sites filled with air (*pseudocavitations*).