

# Surgical Techniques for Orbital Tumors

# 11

Zeynel A. Karcioğlu

## Anesthesia in Orbital Tumor Patient

Many mid and deep orbital surgeries in adults and virtually all procedures in children are performed under general anesthesia; however, anterior orbit explorations and/or simple biopsies in adults can be performed with local anesthesia and intravenous sedation [1].

The administration of regional anesthetics, even when general anesthesia is used, containing epinephrine about 5–15 min prior to incision into the soft tissues of the surgical field contributes to vasoconstriction significantly. If nasal or sinus involvement is anticipated during the orbital exploration, it may be helpful to use a vasoconstrictive nasal spray and pack the nose with half-inch gauze-strip, soaked in Neosynephrine or another vasoconstrictive agent [2].

All local anesthetic solutions are prepared as weak hydrochloride salts to extend their shelf lives and to stabilize added vasoconstrictors. However, this weak acid assembly delays their onset of action and makes them painful on injection. Lidocaine (1% or 2%) is the most

widely used local anesthetic and produces the least amount of pain on injection. Anesthetics commonly utilized can be generally ordered on a scale from least to most painful for injection: lidocaine 1%, procaine 2%, bupivacaine 0.5%, and etidocaine 1%. Pain during injection varies with pH of solution, osmolality, lipid solubility, temperature, the speed of injection, size of needle, as well as other environmental and emotional patient-related factors [3, 4].

Addition of epinephrine (1:100,000, 1:200,000, 1:400,000) for vasoconstriction decreases the absorption rate, prolongs the action, but increases the pain of local anesthetics at injection. At the incision site, lidocaine with epinephrine is usually injected subcutaneously into deeper soft tissues. The use of a long-acting local anesthetic, administration of an IV steroid to minimize inflammation and utilization of a nonsteroidal anti-inflammatory drug on a regular basis will minimize the need for postoperative opioids, and this works well in ASA I and II patients.

The effect of local anesthetics begins approximately 5 and 4 min after injection without and with epinephrine respectively. The duration of the effect ranges from 1 to 2 h. The maximum recommended dose is 4.4 mg/kg without epinephrine and 7.0 mg/kg with epinephrine. Lidocaine, like all other local anesthetics, may lead to systemic toxicity with increased BP and heart rate, arrhythmias, dysrhythmias, and CNS signs and symptoms of drowsiness, seizures, and

**Electronic supplementary material** The online version of this chapter ([https://doi.org/10.1007/978-3-030-18757-6\\_11](https://doi.org/10.1007/978-3-030-18757-6_11)) contains supplementary material, which is available to authorized users.

Z. A. Karcioğlu (✉)  
Department of Ophthalmology, University  
of Virginia, Charlottesville, VA, USA  
e-mail: [zak8g@virginia.edu](mailto:zak8g@virginia.edu)

headaches. In patients who use nonselective beta blocker (B1, B2), the administration of a vasoconstrictor will act solely at the  $\alpha_1$  site, producing vasoconstriction. Epinephrine may not be used with patients who are on tricyclic antidepressants or MAO inhibitors. On the other hand, patients who are on the newer SSRIs such as Prozac may be given epinephrine.

Small doses of local anesthetics injected into the orbit and periorbital tissues may rarely produce serious adverse reactions similar to systemic toxicity such as confusion, convulsions, respiratory arrest, and cardiovascular changes. These reactions may be due to unintended intra-arterial injection of the local anesthetic with retrograde flow to the cerebral circulation. Patients receiving these blocks should be under constant observation. Resuscitative equipment and personnel for treating adverse reactions should be immediately available [5, 6].

---

### General Surgical Principles in Orbital Tumor Patient

The details of the lesions in individual compartments of the orbit should be ascertained together with the below listed general concepts of orbital surgery. The anatomic distributions of tumors in orbital compartments are not perfectly defined; however some lesions do have a tendency toward one region or another. These include, in the upper-outer quadrant (lacrimal gland fossa), dermoid cyst, lacrimal gland tumors, and lymphoma; in the upper-inner quadrant (lacrimal gland fossa), dermoid cyst, lacrimal gland tumors, and lymphoma; in the upper-inner quadrant, commonly mucocele; in the inferior orbit, basal cell carcinoma medially, and inflammatory or squamous lesions from perinasal sinuses centrally; in the lateral and posterior orbit, commonly cavernous malformations and nonspecific inflammatory disease; and, in the posterior and apical orbit, meningioma, cavernous malformations, Schwannoma, and inflammatory lesions (Tables 11.1 and 11.2). Understanding these tendencies may assist in planning the approach, as well as in preparing for the gross appearance of the lesion and the tactile characteristics of the capsule and/or internal contents of the mass.

The best position for orbital surgery is reverse Trendelenburg, which reduces arterial flow to the orbit and promoted venous return to the heart. The head should be positioned according to the planned orbitotomy. It is best to prep both sides allowing intra-operative comparison to opposite orbit for assessment of symmetry. If tissue harvesting from other sites (thigh, retro auricular area, fellow eyelid, etc.) will be performed, graft sites should also be prepared and covered with sterile towels. If the use of a microscope or endoscope is planned, the OR team and anesthesiologist should be notified beforehand. Refer to Fig. 11.1 for an example of hand-held instrument tray for common orbital surgeries.

### Incisions

Skin incisions of the eyelids and the periorbital area should ideally follow the relaxed skin tension lines (RSTLs) and are best placed in natural creases or other hidden locations such as the conjunctival fornix or the eyelid caruncle (Fig. 11.2) [7]. Prior to injection with local anesthetics, the incision line should be marked with a surgical pen. The skin incisions can be made with a Bard-Parker 15-C or a 3 mm, 30° sharp, disposable blade (e.g., Super Blade®). Ideally, the incision should cut only the skin, not the underlying subcutaneous tissues, as dissection can carry forward in a stepwise, layer-by-layer manner. In general, the skin incisions are made perpendicular to the skin surface; however, if an eyebrow incision is needed, the incision may be made at a 45° angle following the angulation of the hair follicles in a beveled manner to allow for hair growth through the incision after healing.

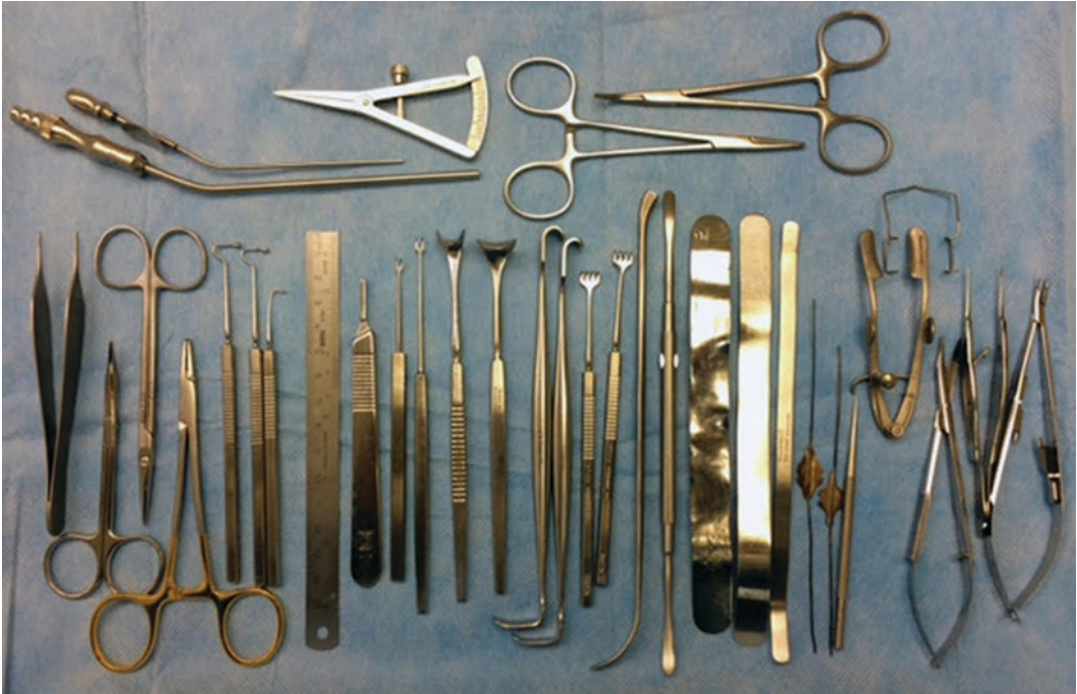The lazy-S incision, starting in the mid-eyelid crease is particularly useful to gain access to superior and lateral orbital space. Other surgeons convincingly claim that the transconjunctival inferior approach provides quicker surgical access to the intraconal zone with a low incidence of complications and a better aesthetic outcome than lateral orbitotomy. (Personal communication with Dr. Santosh Hanovar, ISOO Meeting 2019). Conjunctival incisions allow direct admission to the primarily inferior compartments of the

**Table 11.1** Space-occupying lesions of the orbit in anatomical compartments

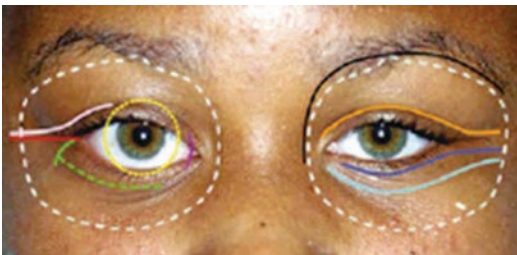Location of commonly encountered lesions	Proptosis	Associated findings	Surgical approach
Benign lacrimal fossa lesions (pleomorphic adenoma, cysts such as dermoid)	Inferior/nasal	Choroidal folds; disproportionately preserved EOM to lesion size	Lacrimal gland fossa exposure through lid-crease or brow incision
Malignant lacrimal fossa lesions (adenocarcinoma, adenoid cystic carcinoma)	Inferior/nasal	Pain; sensory deficit; poor motility; lymphadenopathy	Same approach may need to expand superiorly or laterally depending on the extent of tumor
Superior/inferior medial lesions (cysts such as dermoid, mucocele, LDS tumors, SCC from ethmoid cells)	Inferior/temporal	Usually w/o choroidal folds; associated trauma, sinusitis, pain; horizontal or diffuse EOM limitation	Transcutaneous (Lynch incision) or transcaruncular medial orbitotomy
Anterior lesions (lymphoma, cysts like dermoid, epithelial)	Mild proptosis away from the site of lesion	Lid/conjunctival involvement	Anterior orbit exposure according to the location of lesion
Benign muscle cone lesions (cavernous malformation, schwannoma)	Axial	Posterior choroidal folds; vein congestion; early disk edema; optic nerve dysfunction	Lateral orbitotomy
Extraconal and intraconal lesions (vascular hamartomas; rhabdomyosarcoma)	Massive without rule	Lid/conjunctival involvement; optic nerve dysfunction w or w/o disc edema; amblyopia	Lateral orbitotomy modified according to the location and size of lesion
Infiltrating lesions (orbital inflammatory syndromes; metastatic carcinoma)	Uneven/"frozen" proptosis; enophthalmos; severe motility dysfunction	Abnormal motility in all gazes; ON dysfunction, lymph nodes	Location oriented approach; core needle biopsy or FNAB or FACT
Inferior lesions (SCC from maxillary sinus, inflammatory lesions)	Superior/axial	Pain and/or sensory deficit in lower periorbital area; motility dysfunction	Inferior trans-conjunctival or subciliary skin approach w or w/o lateral crus incision ("swinging lid")
Posterior orbit, apical lesions (meningioma, glioma, paraganglioma)	Minimal axial, late proptosis	Optic nerve dysfunction; mild axial proptosis	Lateral orbitotomy; deep transorbital approach
Entire orbit such as solid/ cystic teratoma	Massive proptosis	Distortion of orbital anatomy; axial displacement of globe with marked chemosis	Usually requires exenteration; globe may be saved in rare cases

**Table 11.2** Orbital inflammations that may cause space-occupying lesions in the orbit

	Nonspecific orbital inflammatory syndrome (NSOIS)	Specific inflammations	Vasculitides	Connective tissue disorders
Infections				
Tuberculosis	Anterior	Sarcoidosis	Wegener's granulomatosis	Lupus erythematosus
Mucormycosis	Myositis	Sjögren's syndrome	Polyarteritis nodosa	Dermatomyositis
Viral Dacryoadenitis	Dacryoadenitis	Sclerosing orbital inflammation	Churg-Strauss syndrome	Rheumatoid arthritis
Echinococcosis, Cysticercosis	Tolosa hunt	HLA B27 related	Behçet's disease	Psoriatic
Allergic Aspergillosis	Diffuse	IgG4-related	Kimura's disease	Scleroderma



**Fig. 11.1** A typical tray containing commonly used hand-held instruments for orbital tumor surgery. Rarely utilized instruments such as rongeurs, Kerrison punch, mallet, chisel, and gouge are not included. Larger surgical apparatus like reciprocating saw, rotary drill, Bovie and bipolar cauterizers, cryo instruments and tips, and dermatomes are not depicted as well



**Fig. 11.2** Skin and conjunctival incisions for orbit surgery. The dotted white circle roughly corresponds to the bony margin of the orbit. Black: sub-brow incision in continuity with Lynch incision; orange: lid. Crease incision; purple: caruncular incision; red: lateral canthal incision; Blue: sub-ciliary incision; green: lateral crus incision (“swinging”), “Lid incision”; turquoise: lower lid incision; yellow: perilimbal incision; Pink: lazy-s incision within the lid crease of upper lid. (From Karcioğlu [29], with permission)

orbit with minimal external scarring. The addition of a lateral inferior cantholysis, converting to a swinging eyelid incision, can enhance access to the lateral orbit and midface. Any quadrant of the orbit can be approached through a segmental con-

junctival peritomy overlying the area. The intraconal space may easily be approached through perilimbal incisions through the sub-Tenon’s space. For the extraconal space one should use forniceal incisions, which are particularly useful medially and inferiorly [8].

The medial conjunctival approach (through the caruncle) allows ample access to the ethmoid/medial wall area of the orbit. Furthermore, the caruncular incision provides excellent access to the medial and posterior orbit [9, 10]. These conjunctival incisions can be combined to allow for an extended orbital exposure of the floor and medial wall.

The most commonly used medial and superior medial skin incisions include modifications of the Lynch approach and the sub-brow incision. Although the classic Lynch incision can leave visible scarring, it may be quite advantageous in some cases to provide access to the lacrimal drainage system (LDS), the ethmoid sinuses, and the nasal cavity.

Superior and superior lateral fornix incisions are not ordinarily used, to avoid traumatizing the palpebral portion of the lacrimal gland and the ductules.

Innovative techniques to enhance the surgical exposure of the posterior orbit and apex have been proposed by many plastic and craniofacial surgeons and neurosurgeons [11, 12]. However, most of these approaches require elaborate procedures and experienced surgical teams and should not be attempted in ordinary ophthalmic surgery settings.

Bone incisions (osteotomies) may offer certain advantages but again these techniques are rarely needed to be utilized for orbital biopsy and only in experienced hands. In orbital tumor surgery, the bone is removed for two main reasons: first, the removal of the marginal bone to provide a wider surgical field, such as in lateral orbitotomy. Secondly, the bone may need to be removed to control a malignancy advancing into the bone, such as adenoid cystic carcinoma of the lacrimal gland.

## Surgical Field

During orbital exploration, magnification and lighting are very important. A great majority of cases can be done under 3- to 5-power surgical loupes. A headlight combined with surgical loupes provides the best illumination.

## Exposure for Exploration

The orbit is a small anatomical chamber crowded with vital tissues that are suspended within a septal network that compartmentalizes the orbital structures and orbital fat. It may be quite inhospitable to the surgeon particularly when the additional volume is added to this tight space by a tumor and secondary edema.

From whatever direction, the orbital exploration commits the surgeon to a deep, three-dimensional field with poor visibility.

Furthermore, changes in the anatomic relationships between structures because of the orbit's conal shape add to the difficulty of the pursuit of the tumor. Therefore, adequate exposure of the surgical field is of utmost importance. The optimization of the exposure begins with the proper selection of initial incision and is maintained with precise positioning of the surgical retractors and placement of traction sutures. Continuous maneuvering employed during orbital exploration to gain ideal exposure often takes more time than the actual biopsy or removal of the tumor.

Proper placement of the patient's head, positioning of the surgeon and assistants, as well as optimum lighting and magnification are the key elements of success in orbital surgery. Patience is an important virtue in orbital dissection, to maintain a bloodless surgical field and adequate exposure of the pathology and the surrounding structures. Because of unanticipated shifting of the orbital fat, the surgeon should be familiar with continuous interruptions of the visibility. The fat can be retracted from the field and often the use of small neurosurgical patties keeps the retracted fat under control; however, the fat moves like water and small variations in position are translated into great perturbations in visualization. All surgical maneuvers should be done with minimum trauma, typically with blunt rather than sharp dissection.

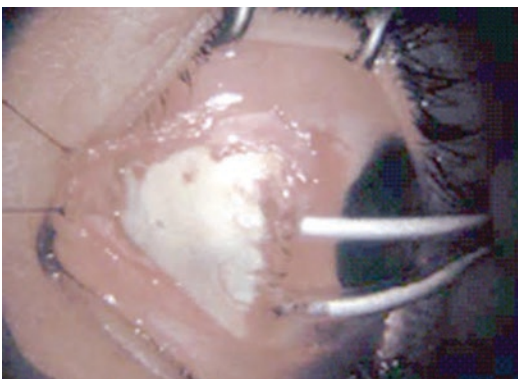
Most of the retraction requirements throughout the procedure are accomplished with the use of hand-held retractors. A wide range of retractors, including Desmarres, Semm, Ragnell, and malleable ribbon retractors (3/8–1 in. width), are used. In addition, rakes (Peck or Follet), muscle hooks (Graf or Jameson), and skin hooks (Joseph or Freer) function well for different levels of tissue retraction (Fig. 11.1).

Another method of improving the surgical visibility is to utilize sutures to pull tissues away from the field. One common application is to use 4–0 silk for eyelid retraction. It is also advisable to pass a marking suture under the extraocular muscles (EOM) to ensure that they can be identified during the later stages of the procedure. In partic-

ular, medial and inferior recti muscles should be anchored with sutures during orbital explorations of corresponding sites. Traction sutures may also be applied to the stumps of disinserted EOMs. A good example is the capture of the stump of the medial rectus during medial orbitotomy through the conjunctival approach. It is best to run a 5-0 Vicryl or Mersilene suture at the stump of the medial rectus muscle and cuff both ends of the suture with silicone tubing to avoid corneal and conjunctival damage during retraction of the globe (Fig. 11.3) (also see Videos 11.1 and 11.2).

Sutures may also be used to retract bone. For example, the zygomatic arch is attached to the temporalis fascia/muscle can be hinged laterally and posteriorly by traction sutures passed through pre-drilled holes in the bone. With this approach, the closure is quicker and the arch fits in its original position well, healing better and faster.

At all times, the orbital surgeon should maintain a mental correlation between the imaging of the lesion and its actual position within the orbit and should approach the lesion through appropriate planes of tissue. The importance of the definition of the plane of entry is aptly emphasized by Rootman, Stewart, and Goldberg: “Instead of entering directly into the pathologically involved tissue planes, the surgeon should begin the dissection in the more easily distracted and pliable normal tissues adjacent to the lesion” [13].



**Fig. 11.3** Silicone tubing cuffed over traction suture to protect underlying cornea and conjunctiva during the course of medial orbitotomy. (From Karcioğlu [29], with permission)

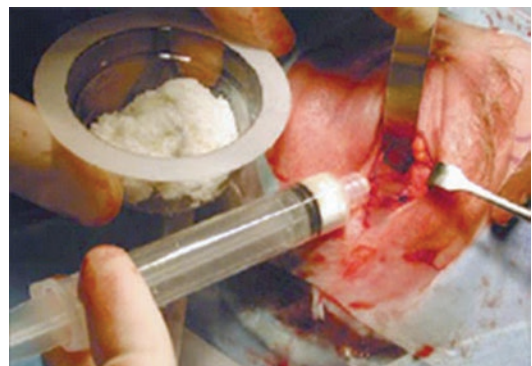This approach allows the distinct advantage of comparing the normal tissues and the abnormal areas in order to permit the ready identification of the pathology.

## Hemostasis

In case of bleeding the first thing to do is to determine if the hemorrhage experienced in the surgical field is due to a damaged blood vessel or to generalized oozing of blood. This can usually be accomplished by alternating suction and gentle pressure over a neurosurgical patty. Usually, a negligible amount of time allows vasoconstriction and subsequent clotting to occur in most cases of small unnamed vessels.

If brisk bleeding is experienced, the culprit blood vessel should be identified, isolated, and cauterized with an insulated bipolar cautery. If the bleeding is due to generalized oozing, it is beneficial to apply thrombin-soaked Gelfoam™ or surgical cottonoids. Neurosurgical cotton pads are preferable because they are easier to identify and remove once the oozing has stopped. Powdered Avitene® can also be packed into the surgical field or delivered by syringe in cases with persistent oozing; Avitene® should be irrigated gently at the end of the procedure (Fig. 11.4).

As mentioned earlier, hemostasis should be initiated by hypotensive anesthesia, as well as by injection of epinephrine-containing local



**Fig. 11.4** Application of Avitene® to control oozing blood in the surgical field. (From Karcioğlu [29], with permission)

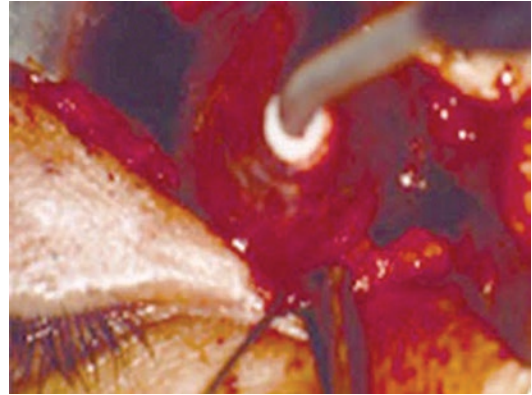
**Table 11.3** Hemostasis in orbital surgery

<i>Pre-surgical</i>
Reverse Trendelenburg position on the operating table
Hypotensive general anesthesia
Application or injection of chemical vasoconstrictors (epinephrine, cocaine, etc.)
<i>Surgical</i>
Application of strip gauze and/or neurosurgical paddies soaked with chemical vasoconstrictors and/or coagulators (Avitene®)
Thrombin-soaked gelatin sponge (Gelfoam®)
Oxidized regenerated cellulose (Surgicel®)
Bone wax for oozing in osteotomies
Cautery application (bipolar, unipolar, fine-tipped disposable)
Pressure by hand or hand-held instruments
<i>Post-surgical</i>
Gentle extubation at the end of the procedure without “bucking”
Application of pressure bandage over the orbit with head bandage with gauze
Immediate application of crushed ice on orbit in OR in plastic bag or surgical glove
Application of ice for 24–48 h after surgery

anesthetics. Intraoperative bleeding can be controlled with bipolar or unipolar coagulators; the fine-needle tip (Colorado tip®) is preferred. Furthermore, vascular ties, clips, and chemical adjuncts can be used to maintain hemostasis (Table 11.3).

## Orbital Biopsy

Orbital biopsy is a very important procedure, and in fact more than half of tumor-related surgeries are performed just to obtain an adequate tissue sample for diagnosis and management. Different biopsy techniques, including FNAB, core biopsy, and excisional biopsy, are utilized depending on the need of the patient [14]. Many papers have been written on biopsy procedures, tissue processing techniques, and benefits of special studies. The reader is referred to these references for detailed information. One imperative requisite for the surgeon is to contact the pathologist prior to surgery and inquire about specific processing requirements and the capabilities of the laboratory.



**Fig. 11.5** Cryoprobe attached to tumor, is being used as a handle during extraction of tumor. (From Karcioğlu [29], with permission)

## Tissue Removal/Ablation

In all quadrants of the orbit, once the sufficient exposure of well-delineated masses (and cysts) is accomplished the lesion is stabilized with forceps, cryoprobe, and/or sutures to be removed. This allows the surgeon to apply gentle traction while dissecting the surrounding tissue attachments to the lesion (Fig. 11.5).

The lesions of the anterior orbit are surgically approached directly over the lesion. About 80% of the mid and posterior orbital pathologies can be easily accessed surgically with time-honored techniques of lateral and conjunctival medial (caruncular) orbitotomies (Table 11.1 and Videos 11.1 and 11.2). Only the rare tumors in unusual locations in the orbit require special surgical methods including combined craniotomies which are not covered in this chapter.

Although the classical lateral orbitotomy approach with retraction or removal of the zygomatic arch is useful in many cases, benign orbital tumors of the intraconal space may be removed effectively through medial transconjunctival and superomedial lid crease incisions even with local anesthesia. According to some surgeons, this approach has a number of advantages over the lateral orbitotomy, including ease of dissection, incision-to-nerve distance, and angle of approach to the optic nerve [1, 15, 16].

Unlike well-encapsulated tumors, infiltrating lesions cannot be removed totally but can only be removed in a piecemeal fashion for diagnostic or debulking purposes. Partial removals can be accomplished by isolating areas of the tumor and excising sections that are not infiltrating vital structures.

Well encapsulated lesions can often be removed completely. Most small and medium size cysts are best dissected with an intact capsule, although it may be advisable in very large cysts to deflate the cystic structure for removal. In certain space-occupying lesions of the orbit, such as pleomorphic adenoma of the lacrimal gland, hemangiopericytoma, and echinococcal cysts, it would be compulsory to remove the lesion within its capsule to avoid seeding into the surgical field.

Innovative surgical techniques for the management of orbital mass lesions have been expanding in the literature. Such methods include direct embolization techniques via the superior ophthalmic vein for cavernous sinus-dural fistulas, image-guided orbital surgery, endoscopic orbitotomy, and percutaneous sclerotherapy [17–22]. These techniques can be extremely useful in specific situations, and however may require specific material and technical capacities that can be institution dependent.

---

## Complications of Orbit Surgery

### Intraoperative Complications

The most serious complication during surgery is the unintentional laceration of a vital structure such as a peripheral nerve, muscle, blood vessel, the optic nerve, or the globe. Although this kind of injury is rare, the damage should be repaired before the procedure is continued. Scleral lacerations are exceedingly rare and should be treated as an open globe repair. Optic nerve damage may not appear immediately and can be related to vascular occlusion or vasospasm. Vascular lacerations are difficult if not impossible to restore with an end-to-end anastomosis because of the small size of the orbital blood vessels and the difficulty in locating the severed ends. If a major peripheral nerve is cut accidentally, it is ideal to anastomose the nerve under high magnification (preferably

with the microscope) with 9-0 nylon suture from perineurium to perineurium after the cut ends of the nerve have been aligned. If anastomosis is not possible, the nerve edges should be approximated to facilitate healing. Tissue glue is another option if available. If an extraocular muscle is cut or damaged inadvertently, it should be approximated and sutured with a 6-0 Vicryl suture.

Lacerations to the nasolacrimal drainage system may also lead to postoperative problems. Here as well every attempt should be made to repair the laceration, and canalicular silicone stent should be placed in a position to maintain the patency of the LDS. If the damage is limited at the canaliculus level, both ends of the cut canaliculus should be aligned and repaired with fine sutures under the operating microscope. If the damage is serious, at the lacrimal sac or nasolacrimal duct level, and judged to be irreparable, a DCR may be the choice of treatment at the end of the orbital exploration or at a later date.

If dural laceration is suspected during surgery, it should be identified to rule out CSF leak. Although small lacerations can be repaired with direct suturing, the visualization is usually not good enough to allow this procedure. The best way to repair the dural rents is to apply free grafts from temporalis fascia or muscle, which can be applied with or without tissue adhesives. For small leaks, orbital fat may be sufficient to plug the leak. If the CSF leak cannot be controlled, neurosurgical consultation should be sought intraoperatively. A lumbar puncture may be of some help to reduce the CSF pressure and thereby allow the surgeon to control the leak better [23].

Intraoperative hemorrhage due to vascular laceration or generalized oozing is the most challenging part of orbital surgery, as it interferes with direct visualization. Therefore, intraoperative bleeding during orbit surgery should be addressed methodically until hemostasis is regained. The first objective is the identification of the bleeding source. Alternating suction and pressure by hand may accomplish this. If any obvious bleeding from blood vessels is detected, these can be cauterized or tied off. If no direct source can be seen, generalized pressure with epinephrine-soaked gauze or thrombin-soaked Gelfoam can be applied with gentle pressure.



Bleeding from the bone may be controlled with unipolar cautery. If this is not successful, bone wax may be applied. Excess bone wax should be carefully removed as it can lead to postoperative foreign body reaction [24].

## Postoperative Complications

### Emergent Postoperative Complications

One of the most serious complications in orbital surgery is a unilateral or (rarely bilateral) orbital hemorrhage leading to compartment syndrome and visual loss. The orbit is a small, non-expansile space, and an expanding hematoma can create a compartment syndrome, which is a potentially vision-threatening condition. The use of orbital drains is somewhat controversial, and their effect in preventing orbital compartment syndrome is not well established (Fig. 11.6).

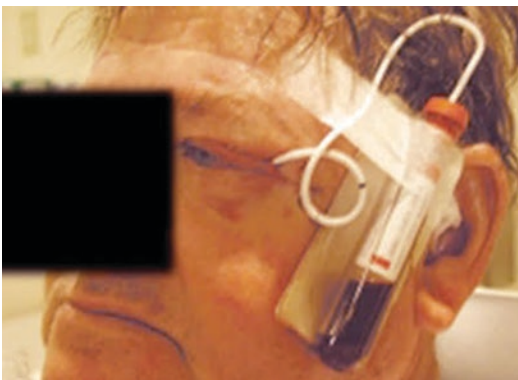Generous application of ice and elevation of the head of the bed during the first 24–48 h of the postoperative period may reduce the likelihood of orbital bleeding and can assist with swelling. However, postoperative hemorrhage may occur even in patients treated in this way, who do not have risk factors such as hypertension or hypocoagulability.

Physician's orders should be clearly written to alert the nursing staff to recognize symptoms of acute postoperative hemorrhage, including loss of vision, pain, and rapidly increasing proptosis. Small postoperative hematomas that produce some proptosis and chemosis but no pain or

afferent pupillary defect can be observed under conservative treatment. If a large postoperative hematoma is suspected, the eye should be examined immediately by checking the visual acuity, intraocular pressure, and pupillary light reflex. If the patient complains of visual loss in the presence of rapidly developing painful proptosis, one should check the intraocular pressure, which correlates with orbital pressure in the acute setting [25]. Even when the imaging studies do not reveal obvious nerve compression but the clinical symptoms suggest an acute increase in intra-orbital pressure, the patient should be managed urgently.

Acute increase in orbital pressure is an emergency. In case of suspicion of a postoperative bleed in a patient with a drain in place, adjustment and/or irrigation of the drain should be tried before surgical intervention. If the high pressure persists, it should be relieved surgically. Opening the surgical wound may be effective as an egress point for the hemorrhage. However, the simplest and the most effective way of relieving the orbital pressure is by performing a lateral canthotomy and cantholysis [26]. This should be performed without delay based on clinical findings [27].

Cantholysis splits the lateral canthal tendon in parallel and allows for access to the superior and inferior crus of the tendon, it does not relieve pressure in itself. In cantholysis procedure, the orbital volume expansion is best accomplished with the lysis of the inferior crus of the lateral canthal tendon. This should include generous portions of the inferior retinaculum, essentially 90° of the orbital rim. If the pressure is not relieved, the superior crus can be cut in the same fashion. When the canthotomy is done, the lids may not cover the cornea which should be protected with ointment, collagen shield, bandage contact lens, or light patching. If the increased orbital pressure cannot be relieved, the patient should be taken back to the operating room so that the wound can be opened to evacuate the blood. If active bleeding is observed, hemostasis should be accomplished and new drains should be placed before re-closure. The addition of mannitol and acetazolamide can be considered to lower the intraocular pressure as well.



**Fig. 11.6** Hemovac™ drain in position one day after surgery. (From Karcioğlu [29], with permission)

## Non-emergent Postoperative Complications

Excessive traction or blind dissection of the orbital tissues may damage the nerves, causing postoperative sensory and motor complications. In one study, the greatest incidence of complications was recorded in lateral orbitotomies (35%). Complications of lateral orbitotomy included extraocular motility problems, particularly abduction deficit (17.5%), and loss of pupillary reflex (10%). The majority of complications were associated with the lateral surgical approach to excise an intraconal mass and tumor type did not appear to be a factor. Ptosis may also be a problem following lateral and superior orbitotomy, typically resolving in weeks to months. However, damage to the superior division of the III CN and injury in the orbital apex can also produce long-term ptosis [28]. Anterior orbitotomy, not surprisingly, had much lower incidence of complications in only 3% of surgeries reported.

Dissection in the lateral orbit may injure the ciliary ganglion, particularly after removal of intraconal lesions, and the patient may develop dilated, nonreactive pupil postoperatively. This may take up to 6 months to resolve, or can be permanent. In superior medial orbitotomy, if the trochlea is injured, the patient may develop acquired Brown's syndrome postoperatively. This usually resolves spontaneously. In superior lateral orbitotomy, the lacrimal gland or its connecting ductules may be damaged, potentially resulting in dry eye. This is usually a permanent problem and should be managed with artificial tears, ointments, and punctal plugs.

Another long-term complication in any surgical procedure is scar formation, which in general can be minimized with strict attention to precise surgical technique. The surgical approach for orbital tumor biopsies is usually well planned and accomplished with relatively small skin incisions. Therefore, scars are seen less often after orbital tumor surgery than following treatment for other orbital problems, such as trauma and inflammation.

**Acknowledgments** We are grateful to Dr. Daniel Rootman, Assistant Professor, Orbital and Ophthalmic Plastic Surgery, Doheny Eye Institute, University of California, Los Angeles, for his contribution as the expert reviewer for this section. The author also appreciates the lifelong surgical counsel he has received from Dr. Bita Esmaeli of Houston, Texas, and Dr. J Chris Fleming of Memphis, Tennessee. He also warmly remembers Dr. Barrett G. Haik of New Orleans, Louisiana, a world leader in ocular and orbital oncology, as a great mentor and a valued friend. Dr. Barrett G. Haik died on July 22, 2016.

Videos 11.1 and 11.2 have been included with contribution from Santosh G Honavar MD, FACS Ocular Oncology Service, Centre for Sight, Banjara Hills, Hyderabad, India and Raksha Rao MS, FICO Department of Orbit and Ophthalmic Oncology, Narayana Nethralaya, Bangalore, India.

## References

- Goldberg RA, Rootman DB, Nassiri N, Shadpour JM. Orbital tumors excision without bony marginotomy under local and general anesthesia. *J Ophthalmol*. 2014;2014:1–5. <https://doi.org/10.1155/2014/424852>.
- Bilyk JR, Sutula FC. Anesthesia for ophthalmic plastic surgery. In: Stewart WB, editor. *Surgery of the eyelid, orbit and lacrimal system*, vol. 1. San Francisco: American Academy of Ophthalmology; 1993. p. 26–55.
- Morris R, McKay W, Mushlin P. Comparison of pain associated with intradermal and subcutaneous infiltration with various local anesthetic solutions. *Anesth Analg*. 1987;66(11):1180–2.
- Gupta A, Tomlins PJ, Ng A TW, Reuser TT. Alleviating pain in oculoplastic procedures by reducing the rate of injection of local anaesthetic. *Open Ophthalmol J*. 2015;9:156–8.
- Ascaso FJ, Peligero J, Longás J, Grzybowski A. Regional anesthesia of the eye, orbit, and periocular skin. *Clin Dermatol*. 2015;33(2):227–33.
- Kumar CM, Dowd TC. Complications of ophthalmic regional blocks: their treatment and prevention. *Ophthalmologica*. 2006;220(2):73–82.
- Borges AF. Relaxed skin tension lines (RSTL) versus other skin lines. *Plast Reconstr Surg*. 1984;73(1):144–50.
- Appling WD, Patrinely JR, Salzer TA. Transconjunctival approach vs subciliary skin-muscle flap approach for orbital fracture repair. *Arch Otolaryngol Head Neck Surg*. 1993;119(9):1000–7.
- Schor HI, Baylis HI, Goldberg RA, Perry JD. Transcaruncular approach to the medial orbit and orbital apex. *Ophthalmology*. 2000;107(8):1459–63.
- Moe KS. The precaruncular approach to the medial orbit. *Arch Facial Plast Surg*. 2003;5(6):483–7.

11. Kim JW, Yates BS, Goldberg RA. Total lateral orbitotomy. *Orbit*. 2009;28(6):320–7.
12. Goldberg RA, Shorr N, Arnold AC, Garcia GH. Deep transorbital approach to the apex and cavernous sinus. *Ophthalm Plast Reconstr Surg*. 1998;14(5):336–41.
13. Rootman J, Stewart B, Goldberg RA. *Orbital surgery: a conceptual approach*. Philadelphia: Lippincott-Raven; 1995.
14. Bourne TD, Karcioğlu ZA. Orbital biopsy. In: Karcioğlu ZA, editor. *Orbital tumors: diagnosis and treatment*. New York: Springer; 2015. p. 121–43.
15. Kiratlı H, Bulur B, Bilgiç S. Transconjunctival approach for retrobulbar intraconal orbital cavernous hemangiomas. Orbital surgeon's perspective. *Surg Neurol*. 2005;64:71–4.
16. Pelton RW, Patel BCK. Superomedial lid crease approach to the medial intraconal space: a new technique for access to the optic nerve and central space. *Ophthalm Plast Reconstr Surg*. 2001;17:241–53.
17. Goldberg RA, Goldey SH, Duckwiler G, Vinuela F. Management of cavernous sinus-dural fistulas. Indications and techniques for primary embolization via the superior ophthalmic vein. *Arch Ophthalmol*. 1996;114(6):707–14.
18. Karcioğlu ZA, Mascott CR. Computer-assisted image-guided orbit surgery. *Eur J Ophthalmol*. 2006;16:446–52.
19. Berger M, Char DH. Interactive image guidance for surgical localization of orbital apical tumors. *Orbit*. 2002;21:199–203.
20. Murchison AP, Rosen MR, Evans JJ, Bilyk JR. Endoscopic approach to the orbital apex and peri-orbital skull base. *Laryngoscope*. 2011;121:463–7.
21. Hill RH, Shiels WE, Foster JA, et al. Percutaneous drainage and ablation as first line therapy for macrocystic and microcystic orbital lymphatic malformations. *Ophthalm Plast Reconstr Surg*. 2012;28(2):119–25.
22. Naik MN, et al. Foam sclerotherapy for periorbital dermoid cysts. *Ophthalm Plast Reconstr Surg*. 2014;30(3):267–70.
23. Tse DT, Panje WR, Anderson RL. Cyanoacrylate adhesive used to stop CSF leaks during orbital surgery. *Arch Ophthalmol*. 1984;102(9):1337–9.
24. Karcioğlu ZA, Nasr AM. Diagnosis and management of orbital inflammation and infections secondary to foreign bodies: a clinical review. *Orbit*. 1998;17(4):247–69.
25. Nassr MA, Morris CL, Netland PA, Karcioğlu ZA. Intraocular pressure change in orbital disease. *Surv Ophthalmol*. 2009;54(5):519–44.
26. Goodall K, Brahma B, Bates A, Leatherbarrow B. Lateral canthotomy and inferior cantholysis: an effective method of urgent orbital decompression for sight threatening acute retrobulbar haemorrhage. *Injury*. 1999;30:485–90.
27. Oester AE Jr, Sahu P, Fowler B, Fleming JC. Radiographic predictors of visual outcome in orbital compartment syndrome. *Ophthalm Plast Reconstr Surg*. 2012;28(1):7–10.
28. Purgason PA, Hornblass A. Complications of surgery for orbital tumors. *Ophthalm Plast Reconstr Surg*. 1992;8(2):88–93.
29. Karcioğlu ZA. *Orbital tumors: clinical diagnosis and treatment*. 2nd ed. New York: Springer; 2015.

**Open Access** This chapter is licensed under the terms of the Creative Commons Attribution 4.0 International License (<http://creativecommons.org/licenses/by/4.0/>), which permits use, sharing, adaptation, distribution and reproduction in any medium or format, as long as you give appropriate credit to the original author(s) and the source, provide a link to the Creative Commons license and indicate if changes were made.

The images or other third party material in this chapter are included in the chapter's Creative Commons license, unless indicated otherwise in a credit line to the material. If material is not included in the chapter's Creative Commons license and your intended use is not permitted by statutory regulation or exceeds the permitted use, you will need to obtain permission directly from the copyright holder.

