



Characterizing Peritumoral Tissue Using DTI-Based Free Water Elimination

Abdol Aziz Ould Ismail¹(✉), Drew Parker¹,
Moises Hernandez-Fernandez¹, Steven Brem², Simon Alexander³,
Ofer Pasternak⁴, Emmanuel Caruyer⁵, and Ragini Verma¹

- ¹ Center for Biomedical Image Computing and Analytics (CBICA), Radiology,
University of Pennsylvania, Philadelphia, PA, USA
AbdolAziz.OuldIsmail@uphs.upenn.edu,
Ragini@pennmedicine.upenn.edu
- ² Neurosurgery, University of Pennsylvania, Philadelphia, PA, USA
- ³ Synaptive Medical Inc., Toronto, ON, Canada
- ⁴ Psychiatry and Radiology, Harvard Medical School, Boston, MA, USA
- ⁵ CNRS, IRISA, Brittany, France

Abstract. Finding an accurate microstructural characterization of the peritumoral region is essential to distinguish between edema and infiltration, enabling the distinction between tumor types, and to improve tractography in this region. Characterization of healthy versus pathological tissue is a key concern when modeling tissue microstructure in the peritumoral area, which is muddled by the presence of free water (e.g., edema). Although diffusion MRI (dMRI) is being used to obtain the microstructural characterization of tissue, most methods are based on advanced dMRI acquisition schemes that are infeasible in the clinical environment, which predominantly uses diffusion tensor imaging (DTI), and are mostly for healthy tissue. In this paper, we propose a novel approach for microstructural characterization of peritumoral tissue, that involves multi-compartment modeling and a robust free water elimination (FWE) method to improve the estimation of free water in both healthy and pathological tissue. As FWE requires the fitting of two compartments, it is an ill-posed problem in DTI acquisitions. Solving this problem requires an optimization routine, which in turn relies on an initialization step for finding a solution, which we optimally choose to model the presence of edema and infiltration unlike existing schemes. We have validated the method extensively on simulated data, and applied it to data from brain tumor patients to demonstrate the improvement in tractography in the peritumoral region, which is important for surgical planning.

Keywords: Diffusion tensor imaging (DTI) · Fractional anisotropy (FA) · Mean diffusivity (MD) · White matter (WM) · Grey matter (GM) · Peritumoral region · Free water (FW) · Volume fraction (VF) · Non-linear optimization · Tractography

1 Introduction

The characterization of tissue microstructure in the peritumoral region is crucial for accurate surgical planning (e.g., using tractography), to identify infiltration for targeted treatment, and to provide new radiomic features for distinguishing tumor subtypes. Accurate white matter (WM) microstructural modeling using diffusion magnetic resonance imaging (dMRI) has the potential to provide a characterization of the peritumoral tissue. Such microstructure modeling is expected to have a substantial impact on future clinical studies in pathologies.

A key aspect for exploring the microstructural properties is to estimate the free water component within a tissue of interest. Not accounting for free water can cause the fitted diffusion tensors to have an erroneously low fractional anisotropy (FA), causing some tracking algorithms to stop prematurely in the contaminated regions. Hence, a correct estimation of free water is crucial.

In one of the earliest attempts for estimating free water, a bi-tensor model was proposed [1], separating the derived diffusion signal into isotropic (free water) and tissue-based components. This approach acknowledged the fact that the bi-tensor model fitting has infinitely many solutions for single-shell data [2], and posited that the ill-posed nature of the problem could be addressed by appropriate initialization of the model parameters and by spatial regularization that stabilizes the fit. The regularized approach significantly contributed to the field of free water elimination (FWE), allowing a better reconstruction of healthy fornix tracts, as well as improving tractography in the peritumoral region. However, the initialization that was originally proposed is acquisition dependent [3]. In addition, there are various pathological conditions in which the initialization in [1] may lead to an inaccurate estimation of the free water compartment and diffusion indices (FA, MD) [4].

In this work, we propose a novel initialization approach based on the estimation of free water maps from simulated ground truth data. This initialization relies on prior and heuristic constraints that were validated across a range of simulated free water fractions, anisotropy levels, and underlying diffusivities. Such an approach allows for optimizing the FWE in the entire brain, including regions affected by pathologies such as edema and infiltration. Therefore, the initialization method that we propose is applicable to standard clinical acquisitions, enabling retrospective investigations and providing novel insight into peritumoral regions. As the method is applicable on any clinically acquired data, the free water map is expected to become a crucial feature in radiomics.

2 Methods

2.1 Free Water Elimination

The proposed FWE initialization is based on a bi-compartment model: a tensor for modeling the underlying tissue, and an isotropic free water compartment. Specifically, we fit [1]

$$A_i = fe^{-bq_i^T D q_i} + (1-f)e^{-bd} \quad (1)$$

where the first term models the tissue and the second term represents the free water compartment. f is the tissue volume fraction, A_i is the signal attenuation of the diffusion weighted image acquired along the i^{th} gradient direction, b is the amount of diffusion weighting, q_i is i^{th} gradient direction, D represents the diffusion tensor used for modeling the tissue compartment, and d is the diffusivity in the isotropic compartment, which is fixed at $3.0 \times 10^{-3} \text{ mm}^2/\text{s}$. Fitting this model using a single-shell dMRI acquisition is a problem with infinitely many solutions. Previously, the fitting was stabilized by using a regularizer post-initialization [1]. There, Pasternak *et al.* proposed an initial estimate of the tissue compartment f based on scaling the unweighted images (S_0) with respect to the mean signal of representative WM voxels (S_t) and CSF voxels (S_w) using:

$$f_{t=0} = 1 - \frac{\log(S_0/S_t)}{\log(S_w/S_t)} \quad (2)$$

In [1], f was additionally constrained within bounds that were enforced during the non-linear fit stage via

$$\frac{A_{\min} - e^{-bd}}{e^{-b\lambda_{\max}} - e^{-bd}} < f_{\lambda_{\min, \max}} < \frac{A_{\max} - e^{-bd}}{e^{-b\lambda_{\min}} - e^{-bd}} \quad (3)$$

where λ_{\max} and λ_{\min} are the expected maximal and minimal diffusivity of the tensor, A_{\max} and A_{\min} are the maximum and minimum measured signal attenuations within a region of interest. This initialization approach suppressed the free water in healthy tissue, yet in the final estimation in this approach as well as other FWE approaches it is clear that free water content in healthy WM tissue is low but not zero [1, 5]. Moreover, the initialization proposed in Eq. (2) is solely based on T2 contrast observed in b0 images. While this T2 contrast gives us information about the amount of free water, it may miss additional information that we can only infer using the diffusion-weighted attenuation.

An alternative approach is to constrain the corrected tissue signal attenuation by assuming that the mean diffusivity (MD) in the healthy tissue is around a fixed diffusivity, e.g., $MD_{\text{tissue}} = 0.60 \times 10^{-3} \text{ mm}^2/\text{s}$ [5, 6], and thus the free water compartment explains the increase in MD in voxels affected by partial voluming. As such:

$$f_{MD} = \frac{e^{-bMD} - e^{-bd}}{e^{-bMD_{\text{tissue}}} - e^{-bd}} \quad (4)$$

where MD is the mean diffusivity from the standard tensor fit in a voxel of interest.

Although such an approach improves the estimation in the healthy tissue, it struggles to characterize regions that are highly contaminated by free water or have tumor cells that restrict the diffusivity further in the peritumoral area, i.e., where MD_{tissue} is not a good initial value. The underlying problem in all these approaches, is that the initialization is designed to either address the healthy tissue or tissue with pathology, but not both.

To alleviate these issues, we propose an initialization to the FWE problem that is a hybrid between $f_{\lambda_{min,max}}$ and f_{MD} . Aiming to obtain a better estimation of the free water compartment in both healthy tissue as well as voxels contaminated by edema or partial voluming, we introduce an initialization that is a log-linear interpolation between $f_{\lambda_{min,max}}$ and f_{MD} . We propose:

$$f_{initial} = f_{MD}^{\alpha} \times f_{\lambda_{min,max}}^{1-\alpha} \quad (5)$$

where α is set to $\alpha = f_{t=0}$ (see Eq. (2)). That is, for tissue with healthy appearing T2, we constrain the free water using f_{MD} (Eq. (4)), and in regions that appear like CSF, or edematous in the T2 contrast, we estimate the free water compartment based on Eq. (3).

2.2 Evaluation

We will evaluate the different FWE initialization approaches on simulated data (where the ground truth is known) as well as on brain tumor patients. On the patients, we will evaluate the fit in the healthy tissue, defined as white matter outside the peritumoral region, as well as in peritumoral region, and its effect on tracking for the purposes of surgical planning.

2.2.1 Simulated Data

To have a sample with ground truth, simulated data was generated with varying ground truth mean diffusivities, anisotropy, and free water volume fractions (Table 1). These simulated datasets follow a bi-tensor model where one of the compartments represents tissue and the second is isotropic with a fixed diffusivity ($3.0 \times 10^{-3} \text{ mm}^2/\text{s}$) [7]. For the unweighted images, we calculate the transverse magnetization as a linear sum of the contribution of each compartment:

$$M_T = VF_{wm}\rho_{WM}\left(1 - e^{-TR/T1_{WM}}\right)e^{-TE/T2_{WM}} + VF_{CSF}\rho_{CSF}\left(1 - e^{-TR/T1_{CSF}}\right)e^{-TE/T2_{CSF}} \quad (6)$$

where VF is the volume fraction, ρ is the proton density, and TR/TE are repetition and echo times. For every experiment, we perform 10 noise realizations by adding Rician noise equivalent to SNR = 40.

Table 1. Parameters selected for simulating data to validate the proposed method

	Values	Number of experiments
MD values	$0.4-1.0 \times 10^{-3} \text{ mm}^2/\text{s}$	4
FA values	0–1	11
Free water volume fractions	0–1	11
Rotation of the tensor directions	–	10
Noise realizations	–	10
Total		48,400

2.2.2 Brain Tumor Datasets

138 brain tumor patients were included (88 glioblastoma/50 metastasis). The data was acquired on Siemens 3T Verio scanner with TR/TE = 5000/86 ms, $b = 1000 \text{ s/mm}^2$, 3 b_0 , and 30 gradient directions. Automatic tumor and peritumoral region segmentation was performed on coregistered T1, T2, T2-FLAIR and T1-contrast enhanced images using GLISTR [8].

2.3 Tractography

Tractography was performed, using Diffusion Toolkit [9], on the FWE tensor field as well as the standard tensor field, in voxels with FA values exceeding 0.2, using the 2nd order Runge-Kutta algorithm with an angle threshold of 45° and a step size of 1 mm. Five bundles of interest (corticospinal tract, inferior frontal, inferior fronto-occipital, uncinate and arcuate fasciculi) were extracted from each tractogram in each hemisphere, using the RecoBundles algorithm [10], with a pruning parameter of 7 mm. Finally, a “coverage measure” was defined and calculated for each patient and each of the two tractograms. “Coverage Measure” is the percentage of voxels in the peritumoral edema region containing a streamline from any of the ten bundles of interest.

3 Results

3.1 Evaluation on Simulated Data

We compare the proposed method to previous approaches [1, 4] that fit a bi-compartment model. Our results show that the FW compartment is estimated to be nearly 0 in the healthy WM, in the previous approaches (Fig. 1C). In simulated edema scenarios (volume fraction (VF) = 0.6), The proposed initialization of free water and FA is closer to the ground truth in simulated edematous/infiltrated regions (Fig. 1A–F), as compared to the other initialization approaches.

FWE in Simulated Data

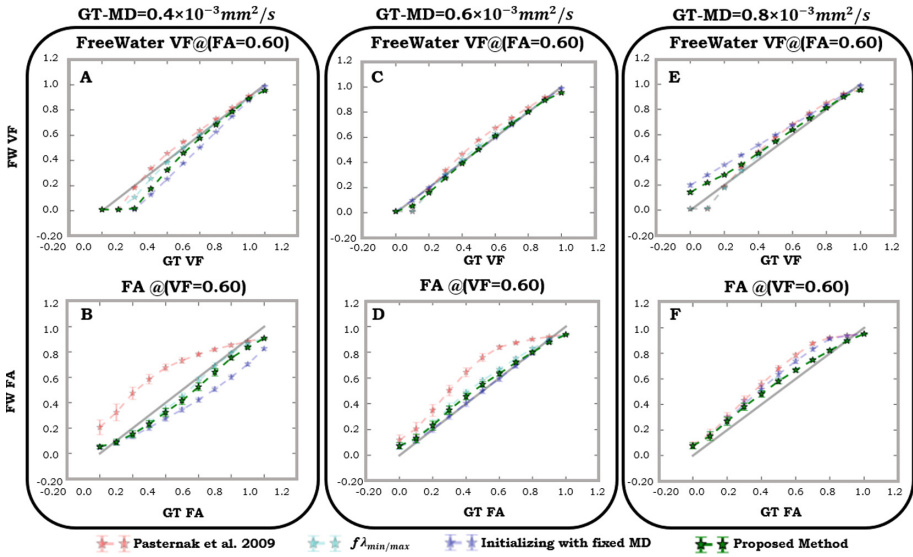


Fig. 1. Three different ground truth (GT) MD values (GT-MD) (1st, 2nd, and 3rd columns) were investigated using different GT FW and GT FA values. For details on the simulation parameters, see Table 1. Four FWE initializations were performed (Pasternak *et al.* [1], $f_{\lambda_{min,max}}$ (i.e., $\alpha = 0$), f_{MD} (i.e., $\alpha = 1$) and the proposed method with varying alpha). The free water (FW VF) and FA (FW FA) outputs of each method are compared to the corresponding ground truth values. The 1st row represents the investigation of the FW maps in a simulated WM across different FW fractions. The 2nd row is for FW FA maps for a simulated edema scenario (VF = 0.60).

3.2 In-Vivo Data: Application on Brain Tumor Datasets

Figure 2 shows the FW and FA maps, pre- and post-FWE, using the proposed approach, f_{MD} initialization, as well as $\alpha = 0$ and $\alpha = 1$. Several things are observed: (i) FA maps from the corrected tensors show that various approaches were successful in increasing FA in the edema region (Fig. 2A); (ii) FW is estimated to be nearly zero in many regions of healthy WM by previous approaches, as compared to our proposed method; (iii) a large number of physiologically implausible voxels (defined as $MD < 0.40 \times 10^{-3} \text{ mm}^2/\text{s}$ [5, 6]) were observed when using the method in [1] (Fig. 2C). Although this was alleviated by use of $\alpha = 0$, this approach underestimated the free water [5, 6] in almost the entire healthy WM (Fig. 2C). The proposed method, as well as the one that used $\alpha = 1$, were able to eliminate these implausible voxels, without underestimating the FW in the healthy tissue (Fig. 2C).

3.3 Tractography

Figure 3A shows the comparative results of tracking in the peritumoral regions, pre- and post-FWE (using the proposed initialization) showing that the streamlines were

able to travel through the peritumoral region more after FWE. Additionally, in Fig. 3B, a quantitative evaluation using our *coverage measure* shows that the tracking coverage in the peritumoral region is significantly improved with FWE.

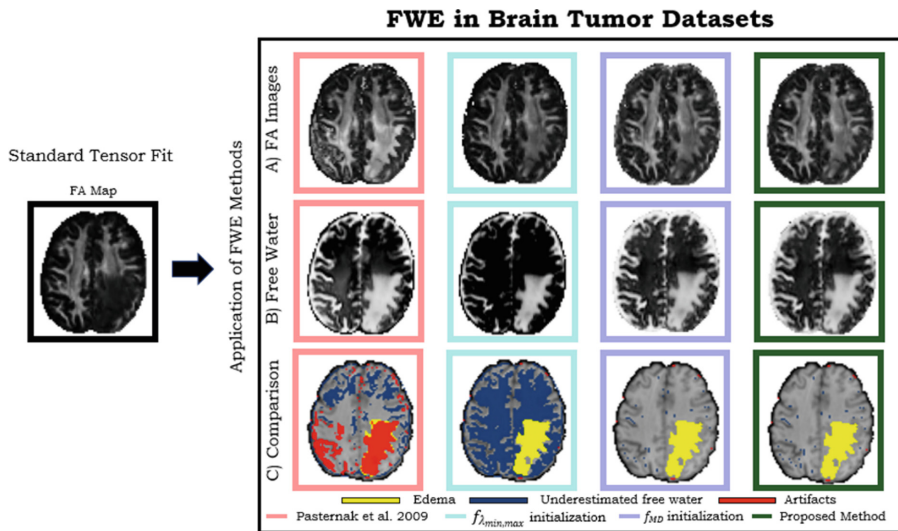


Fig. 2. (A) FA maps from the various FWE initializations. (B) Free water maps using different initialization strategies. (C) Location of implausible and voxels with underestimated FW (FW volume fraction < 0.02) in the different investigated methods.

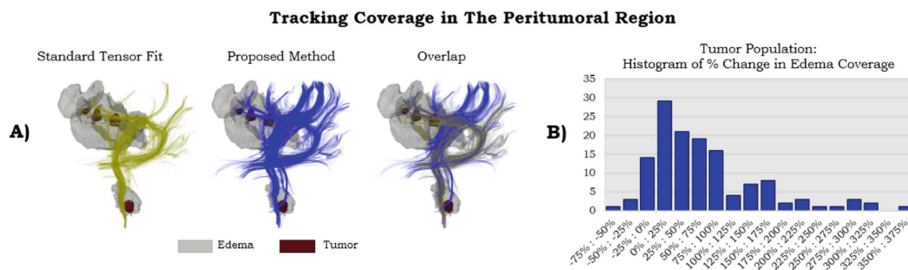


Fig. 3. (A) Comparison of tracking in the peri-tumoral region (gray blob), pre- and post FWE in the left arcuate and CST reconstructed in a tumor patient using the proposed initialization. In the overlap of the approaches, we see the significant increase of streamlines coverage in the edema. (B) Tracking coverage in the edema was computed before and after FWE. A paired t-test analysis of tractography showed a significant increase in peritumoral region coverage using FWE tractography ($t = 6.91, p < 1 \times 10^{-9}$). (Color figure online)

4 Discussion

In this manuscript, we proposed a novel initialization method for estimating the free water compartment from single-shell acquisitions. Our proposed method addresses initialization challenges of the two-compartment model, improves the fitting process and reduces implausible voxels in the FWE output.

Although there is a growing trend of dMRI Multi-shell protocols in the clinical environments, the single-shell acquisition is still the most frequent sequence in clinical studies. Here we have shown that traditional approaches for characterizing the tissue microstructure with free-water elimination in single shell data, struggle in many scenarios due to the lack of a proper initialization that accounts properly for both healthy tissue and tissue contaminated by edema or cancer cells. The findings of our novel approach demonstrate that interpolating diffusivity and T2 information, in the initialization, significantly improved the estimation in the healthy and contaminated tissues when compared to previous initialization methods [1, 4].

The fact that previous FWE initialization approaches [1, 4] estimated free water to be zero in healthy white matter, is evident both in the simulated data (Fig. 1C), as well as the healthy tissue regions in Fig. 2C. Initializations with f_{MD} and our proposed method, were able to produce values that are closer to the ground truth in healthy tissue (Fig. 2). However, simulations show that f_{MD} approach is misleading when the underlying diffusivity is different than that of the healthy tissue (Fig. 1A and B). This presents a clinical challenge in the case of the cytotoxic edema, where the underlying apparent diffusivity reduces significantly compared to that of the healthy tissue. On the other hand, the proposed approach yields a robust solution across different diffusivities in the simulated peritumoral region.

Furthermore, the proposed strategy for initializing the parameters of a bi-compartment model leads to a better characterization of the underlying white matter in areas affected by edema. This affects the results of tractography, allowing the reconstruction of tracts impacted by edema (Fig. 3). These findings may play an important role in the pre-surgical planning, where the non-invasive reconstruction of white matter tracts is critical, especially in the regions with edema, so as to not miss eloquent tracts. This provides a safer resection margin for the surgeon.

An interesting question to pursue in future work is how different optimization routines affect the accuracy of free water estimation. In this study we have used the Gradient Descent optimization algorithm. In the future, we will compare this algorithm with Levenberg-Marquardt algorithm, and moreover, we will apply a Bayesian approach for fitting the model, Markov Chain Monte Carlo (MCMC). Additionally, the differences that are evident in the peritumoral tissue in the metastatic tumors and the GBMs, suggest the potential of free water measures in differentiating tumor subtypes. This will be undertaken as future work.

References

1. Pasternak, O., Sochen, N., Gur, Y., Intrator, N., Assaf, Y.: Free water elimination and mapping from diffusion MRI. *Magn. Reson. Med.* **62**, 717–730 (2009)
2. Scherrer, B., Warfield, S.K.: Why multiple b-values are required for multi-tensor models: evaluation with a constrained log-Euclidean model. In: *ISBI 2010*, pp. 1389–1392 (2010)
3. Parker, D., Ould Ismail, A., Alexander, S., Verma, R.: The role of bias field correction in the free water elimination problem. In: *ISMRM*, June 2018
4. Ould Ismail, A., Parker, D., Alexander, S., Caruyer, E., Pasternak, O., Verma, R.: Free watER iNvariant Estimation of Tensor (FERNET): addressing the issue of edema in clinically feasible acquisitions. In: *ISMRM*, June 2018
5. Hoy, A.R., Koay, C.G., Kecskemeti, S.R., Alexander, A.L.: Optimization of a free water elimination two-compartment model for diffusion tensor imaging. *NeuroImage* **31**(103), 323–333 (2014)
6. Kodiweera, C., Wu, Y.C.: Data of NODDI diffusion metrics in the brain and computer simulation of hybrid diffusion imaging (HYDI) acquisition scheme. *Data Brief* **1**(7), 1131–1138 (2016)
7. Garyfallidis, E., et al.: Dipy, a library for the analysis of diffusion MRI data. *Front. Neuroinform.* **21**(8), 8 (2014)
8. Gooya, A., et al.: GLISTR: glioma image segmentation and registration. *IEEE Trans. Med. Imaging* **31**(10), 1941–1954 (2012)
9. Wang, R., Benner, T., Sorensen, A.G., Wedeen, V.J.: Diffusion toolkit: a software package for diffusion imaging data processing and tractography. In: *Proceedings of the International Society for Magnetic Resonance in Medicine 2007*, vol. 15, no. 3720 (2007)
10. Garyfallidis, E., et al.: Recognition of white matter bundles using local and global streamline-based registration and clustering. *NeuroImage* **170**, 283–295 (2017)