MHV-A59 PATHOGENESIS IN MICE

Ehud Lavi, Donald H. Gilden, Maureen K. Highkin, and Susan R. Weiss

The Multiple Sclerosis Research Center of the Wistar Institute of Anatomy and Biology and the Departments of Neurology and Microbiology, University of Pennsylvania School of Medicine, Philadelphia, PA 19104 USA

INTRODUCTION

Coronaviruses produce both acute and chronic diseases in various animal species. A recent review summarizes the biology and pathogenesis of coronaviruses.[1] Of special interest is the chronic demyelinating disease produced by mouse hepatitis virus (MHV) in rodents. This model has been used to study the mechanisms of virus-induced demyelination. Information acquired from such an experimental system may shed light on the pathogenesis of human demyelinating disease.

Experimental infection of weanling mice with wild-type MHV-JHM produces an acute panencephalitis with 20-50% mortality; demyelinating disease is found in the survivors.[2] In older mice (12 weeks old) there is no mortality and 46% develop chronic demyelinating disease.[3] Experimental inoculation of 4-5 week old mice with a temperature-sensitive mutant of JHM (ts-8) results in decreased mortality and increased demyelination.[4,5] Why JHM-ts8 preferentially produces chronic demyelination is not known. This may be due to the predilection of ts-8 for growth in non-neuronal central nervous system (CNS) cells in vitro.[6] In the same study another strain of MHV (A59) was also shown to replicate better in non-neuronal cells than in neurons.

MHV-A59 was first discovered in 1961 when mice, inoculated with mouse leukemia virus, developed an unexpected hepatitis.[7] MHV-A59 that was isolated from the liver of these mice produced hepatitis in various mouse strains of different ages. When

P. J. M. Rottier et al. (eds.), *Molecular Biology and Pathogenesis of Coronaviruses*

inoculated intracerebrally (i.c.) into suckling rats, MHV-A59 produced acute necrotizing encephalitis and hydrocephalus.[8] Only recently has the ability of this hepatotropic strain to produce demyelination been appreciated.[9,10] We describe here a detailed study of MHV-A59 pathogenesis in 4-6 week old C57BL/6 mice.

MATERIALS AND METHODS

Virus and Animals

MHV-A59, originally supplied by Dr. J. Leibowitz, was plaque-purified three times in mouse 17CL-1 cells. Stock virus contained $2x10^7$ plaque-forming units (pfu)/ml. Certified MHV-free 4-6-week-old C57BL/6 mice (Jackson laboratories) were used. The absence of antibodies against MHV was confirmed by an indirect immunofluorescence (IF) assay of randomly sampled sera (see below). Mice were inoculated (i.c.) with 0.03ml of different amounts of the stock virus diluted in PBS containing 0.75% BSA. For intraperitoneal (i.p.) inoculation, 0.5 ml of diluted virus was used. For intranasal inoculation (i.n.), 0.2 ml of the virus was applied to the nostril of lightly anesthetized mice which were observed until the virus was inhaled. Intragastric (i.g.) inoculation was performed by injection of 0.2 ml of the virus through an oral-gastric tube. Clinical, virological, histological and IF studies were performed as previously described.[11,12] In addition, some mice were perfused with 0.1M PBS (pH 7.4) containing 1% each of glutaraldehyde and formaldehyde. Spinal cords were post-fixed in osmium tetroxide, dehydrated and embedded in Epon. One μm sections were stained with toluidine blue for light microscopy.[13] Thin sections for EM were stained with uranyl acetate and lead citrate.

Growth of MHV-A59 in Infected Tissue and Blood

Serial ten-fold dilutions of homogenized brain, spinal cord, liver or heparinized blood were prepared in Dulbeccos modified Eagle medium supplemented with 2% fetal calf serum and were titrated by plaque assay in 17CL-1 cells.[14]

Immunofluorescence

The indirect IF antibody method[15] was used, as previously described for infected mouse tissue[12] with a 1:10 dilution of mouse anti-A59 hyperimmune serum and a 1:10 dilution of fluorescein isothiocyanate-conjugated goat anti-mouse immunoglobulin G (Cappel, Downingtown, PA). Controls were provided by the substitution of normal mouse serum for hyperimmune serum; uninfected mouse cells and tissue were also stained with hyperimmune anti-MHV-A59 serum.

Serology

Anti-MHV-A59 antibodies in sera of infected mice were determined by indirect IF on MHV-A59 infected 17CL-1 cells. Uninfected cells were stained with the same sera. Sera from infected mice were also tested for neutralization by the constant-virus-varying-serum method for plaque reduction.[16]

RESULTS

Intracerebral Inoculation

Mice that were inoculated with 1.2×10^3 pfu developed mild hind limb paralysis and ataxia 2-6 weeks post infection (PI); peak disease occurred at 3-4 weeks. None of the mice died. Histological examination revealed acute mild meningoencephalitis during the second week PI but no evidence of acute hepatitis. However, all the mice had chronic demyelinating lesions in the brain and spinal cord 25-60 days PI (Table 1).

Inoculation with 3×10^3 pfu produced a biphasic disease (Table 1). During the second week PI, all the mice developed a hunched position, ruffled fur and became lethargic. The clinical condition of the mice improved during the third week PI. A second phase started during the fourth week PI with neurological signs of hind limb or four limb spastic paralysis and ataxic gait. The peak of the second phase was during the second month PI and most of the mice had continued mild hind limb paralysis for the remainder of the ten month observation period. Mice died both during the acute phase (35%) and also at the beginning of the second phase (15%). During the acute phase histological examination revealed mild meningoencephalitis and acute massive hepatitis with multiple necrotic foci in the liver. Occasionally acute myelitis was seen. Late disease was characterized by lesions confined to the white matter in the brain and spinal cord (Fig. 1). Primary demyelination was revealed by ballooning and stripping of myelin sheaths from otherwise preserved axons and by phagocytosis of myelin by macrophages. This resulted in numerous demyelinated bare axons (Fig. 2). A short period of viremia developed during the second and third days PI. Virus could be recovered from the brain 2-25 days PI, from the spinal cord 3-11 days PI and from the liver on day 5 PI. MHV-A59 antigen was initially detected by IF in the meninges and ependyma 2-3 days PI, and in the parenchyma from 3 days to 3 months PI. Serum IF and neutralizing antibodies against MHV-A59 were first detected 7 days PI and reached peak titers (1:80-1:160) 2-8 weeks PI. Antibodies were still detected at 1:40 5 months PI.

A dose of 3×10^4 pfu produced severe acute disease with ruffled fur, hunched position and lethargy. All the mice died by

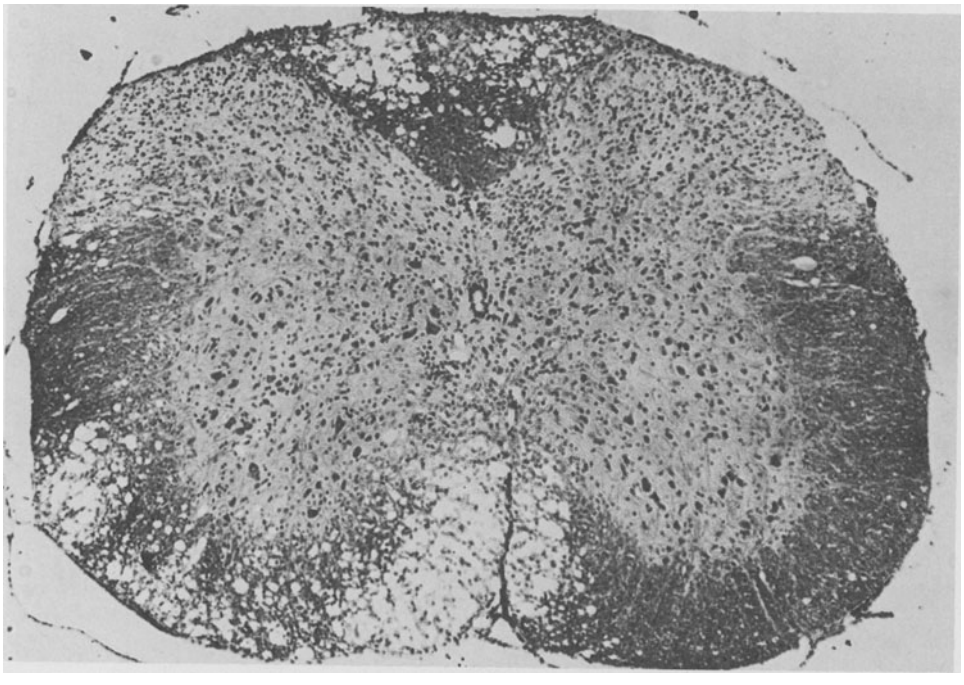

Fig. 1. Transverse section of mouse spinal cord 60 days after intracerebral inoculation with $3x10^3$ pfu MHV-A59. Note primary damage to white matter. Hematoxylin and Eosin. x200

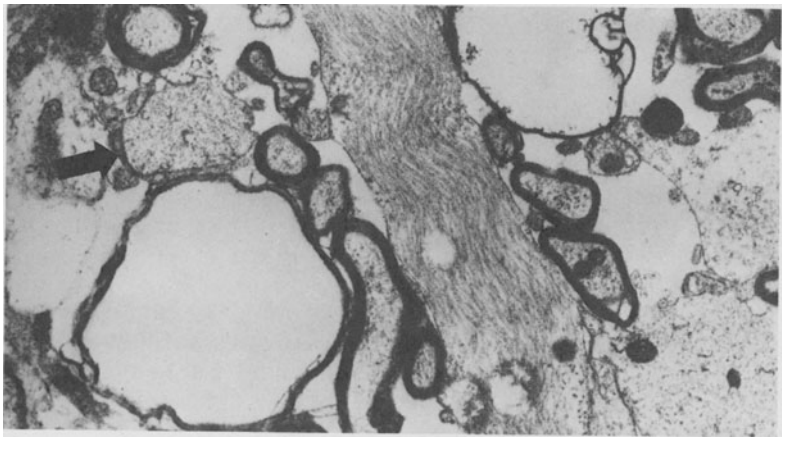

Fig. 2. Electron micrograph of spinal cord white matter from a mouse 60 days after intracerebral inoculation with $3x10^3$ pfu of MHV-A59. This field contains normal myelinated fibers, a single baare axon (arrow) and a vertically oriented glial fiber. x7000

the end of the second week PI. Histological examination showed severe acute hepatitis and moderate meningoencephalitis (Table 1).

Intraperitoneal Inoculation

A dose of $3x10^3$ pfu did not kill or produce any clinical disease or pathological changes during the two month PI observation period.

A dose of $3x10^4$ pfu also did not kill or produce clinical signs; however, discrete foci of hepatic necrosis were found in the absence of CNS involvement. IF antibodies against MHV-A59 were found at a titer of 1:80 in the serum of mice 30 days PI.

A dose of $3x10^5$ pfu produced moderate to severe acute disease. The majority of the mice developed hunched position and ruffled fur; 20% died. IF antibodies against MHV-A59 were detected at a titer of 1:160 in the serum of mice 30 days PI. Virus was recovered from the liver of mice ($1.2x10^4$ pfu/gr) at day 5 PI, but could not be recovered from the blood.

A dose of $3x10^6$ pfu led to severe acute disease with 100% mortality. Histological examination showed severe hepatitis with massive diffuse necrotic lesions in the liver. There was no CNS involvement.

Intranasal Inoculation

A dose of $3x10^6$ produced mild clinical disease during the second week PI characterized by mildly hunched position and ruffled fur in some of the mice; 1/20 died (Table 1). Histological examination revealed inflammatory infiltration in the livers, lungs and meninges 4 days PI. By 7 days PI all the mice developed mild hepatitis and severe meningoencephalitis. Mononuclear infiltration and perivascular cuffing were seen in the meninges, choroid plexus and in the brain. Microglial proliferation was also observed diffusely. Necrotic lesions were pronounced in cortical and thalamic areas. By 30 days PI, lesions were found only in the cerebral (50%) and spinal cord (70%) white matter. The white matter lesions were similar to those produced by the i:c. inoculation. By 60 days PI only one mouse out of ten showed white matter lesions in the spinal cord. IF anti-MHV-A59 antibodies were detected from 7-60 days PI (1:20-1:40).

Intragastric Inoculation

Mice did not get sick or die, however 50% of the mice developed a few circumscribed areas of inflammation in the liver adjacent to portal veins. In one of 6 mice, acute meningoencephalitis was

found. None of the mice developed chronic white matter lesions (Table 1). IF anti-MHV-A59 antibodies were detected 10-30 days PI (1:20-1:40).

DISCUSSION

The relevance of coronaviruses to human demyelinating diseases has been investigated because of the following findings: the detection of coronavirus-like particles by EM in the brain of one MS patient[17]; the isolation of two coronaviruses in mice and from mouse cell lines inoculated with MS brain tissue[18]; and the detection of intrathecal synthesis of antibodies against coronaviruses in MS patient[19]. We present here a model system of MHV-A59 infection in mice in which to study the relationship between coronaviruses and demyelination

MHV-A59 is considered mainly hepatotropic and only weakly neurotropic[7,9]. We show here for the first time that by i.c. inoculation of 4-6-week-old C57BL/6 mice with 1.2×10^3 pfu of MHV-A59 it is possible to produce disease that is exclusively in the CNS. Moreover, by the i.n. route of inoculation, which may mimic natural infection, we produced a nonfatal disease mainly in the CNS, with only mild liver involvement.

The clinical and pathological findings after i.c. inoculation with MHV-A59 were dose dependent. An amount of 3×10^4 pfu caused acute panencephalitis and hepatitis that killed 100% mice. A dose of 3×10^3 pfu caused biphasic disease. Mice that survived the acute phase developed chronic demyelinating disease. A dose of 1.2×10^3 pfu led to subacute demyelinating disease without involvement of the liver.

I.P. inoculation of MHV-A59 produced only hepatitis without involvement of the CNS. It is of interest that the dose required for production of severe liver disease by i.c. inoculation (3×10^3 pfu) did not produce any pathological changes when inoculated i.p. The amounts that were used for the production of liver disease by i.p. inoculation were markedly higher than the doses that were used for the induction of liver disease by i.c. inoculation. A possible explanation for this phenomenon lies in the fact that peritoneal macrophages from different mouse strains (including C57BL/6) are capable of suppressing MHV replication[20]. These cells provide the first defense mechanism against the invasion of MHV into the peritoneal cavity. Because the brain is a lymphoid-free organ, macrophages are not present to suppress MHV replication after it is inoculated intracerebrally.

Table 1. The Pathogenesis of MHV-A59 in C57BL/6 Mice by Different Routes of Inoculation

Route of Inoc.[a]	Number of Mice	Dose of Inoc.[b]	Mortality[c]	Histology[d] HEPAT.	AC.ME.	CHR.DEMY.	Clinical Signs[e]
I.C.	30	1.2×10^3	0	0	100	100	Mild chronic disease.
	30	3×10^3	50	100	100	100	Biphasic disease: moderate-severe acute disease, moderate-severe chronic disease.
	10	3×10^4	100	100	100	–	Severe acute disease.
I.P.	10	3×10^3	0	0	0	0	None
	10	3×10^4	0	100	0	0	None
	10	3×10^5	20	100	0	0	Moderate-severe acute disease.
	5	3×10^6	100	100	0	0	Severe acute disease.
I.N.	30	3×10^6	5	100	100	70	Mild acute disease.
I.G.	10	3×10^6	0	50	10	0	None

a - Route of inoculation: i.c. - intracerebral, i.p. - intraperitoneal, i.n. - intranasal, i.g. - intragastric.
b - Dose of inoculation as expressed in pfu/inoculum.
c - Mortality and histological findings are expressed in percentage of mice out of total in that category.
d - Hepat. - hepatitis, Ac.Me. - acute meningoencephalitis, Chr.Demy. - chronic demyelination.
e - Acute disease: hunched position, ruffled fur, lethargy. Chronic disease: hind limb or 4 limb spastic paralysis and/or ataxic gait.

The i.n. inoculation resulted in invasion of MHV-A59 not only into the lung and liver but also into the CNS, indicating that MHV-A59 is neurotropic as well as hepatotropic. Whether virus enters the brain via the olfactory nerves or via the blood is not yet clear. The weak response to intragastric inoculation suggests that it may be less important than intranasal-acquired infection of MHV-A59 in mouse colonies.

In conclusion, we demonstrated that the ability of the A59 strain of MHV to produce demyelination is dependent both on dose and route of inoculation. These biological properties of MHV-A59 provide a useful model system for further study of the mechanism of virus-induced demyelination.

ACKNOWLEDGEMENTS

The authors wish to thank Dr. Lucy B. Rorke for assistance with the pathological work. This work was supported by grants RG-1421-A-1 and RG-894-C3 from the National Multiple Sclerosis Society and grants AI 17418 and NS 11037 from the National Institutes of Health. E. Lavi was the recipient of a Penn-Israel Wexler Fellowship award and was supported in part by the Kroc Foundation.

REFERENCES

1. H. Wege, S. Siddell, V. ter-Meulen, The Biology and pathogenesis of coronaviruses, Advances in Virology and Immunology, 99:165-200 (1982).
2. L. P. Weiner, Pathogenesis of demyelination induced by mouse hepatitis virus (JHM), Arch. Neurol., 28:298-303 (1973).
3. S. A. Stohlman, L. P. Weiner, Chronic central nervous system demyelination in mice after JHM virus infection, Neurology, 31:38-44 (1981).
4. M. V. Haspel, P. W. Lampert, M. B. A. Oldstone, Temperature-sensitive mutants of mouse hepatitis virus produce a high incidence of demyelination, Proc. Natl. Acad. Sci. USA, 75:4033-4036 (1978).
5. R. L. Knobler, P. W. Lampert, M. B. A. Oldstone, Virus persistence and recurring demyelination produced by a temperature-sensitive mutant of MHV-4, Nature, 298:279-280 (1982).
6. M. E. Dubois-Dalcq, E. W. Doller, M. V. Haspel, K. V. Holmes, Cell tropism and expression of mouse hepatitis virus in mouse spinal cord cultures, Virology, 119:317-331 (1982).
7. R. A. Manaker, C. V. Piczak, A. A. Miller, M. F. Stanton, A hepatitis virus complicating studies with mouse leukemia, J. Nat. Cancer Inst., 27:29-51 (1961).

8. N. Hirano, N. Goto, T. Ogawa, K. Ono, T. Murakami, K. Fujiwara, Hydrocephalus in suckling rats infected intracerebrally with mouse hepatitis virus MHV-A59, Microbiol. Immunol., 24:825-834 (1980).
9. J. A. Robb, C. W. Bond, J. L. Leibowitz, Pathogenic murine coronaviruses III. Biological and biochemical characterization of temperature-sensitive mutants of JHMV, Virology, 94:385-399 (1979).
10. E. Lavi, D. H. Gilden, Z. Wroblewska, L. B. Rorke, S. W. Weiss, Experimental demyelination produced by the A59 strain of mouse hepatitis virus, (abs), Neurol., (Suppl.), 33:106 (1983)
11. L. B. Rorke, D. H. Gilden, Z. Wroblewska, J. S. Wolinsky, Experimental panencephalitis induced in suckling mice by parainfluenza type I (6/96) virus. I. Clinical and pathological features, J. Neuropath. Exp. Neurol., 35:247-258 (1976).
12. D. H. Gilden, Z. Wroblewska, M. Chesler, M. Wellish, F. S. Lief, J. S. Wolinsky, L. B. Rorke, Experimental panencephalitis induced in suckling mice by parainfluenza 1 (6/94) virus. II. Virologic studies, J. Neuropath. Exp. Neurol., 35:259-270 (1976).
13. J. R. Martin, Spinal cord and optic nerve demyelination in experimental herpes simplex virus type 2 infection, J. Neuropath. Exp. Neurol., 41:253-265 (1982).
14. S. R. Weiss, J. L. Leibowitz, Comparison of the RNAs of murine and human coronaviruses, in: "Biochemistry and Biology of Coronaviruses," V. ter Meulen, S. Siddell and H. Wege, eds., Plenum Press, New York, 245-259 (1981).
15. M. Goldman, Fluorescent antibody methods, Academic Press, New York, 157-158 (1969).
16. E. H. Lennette, N. J. Schmidt, Diagnostic procedures for viral and rickettsial infections, American Public Health Assc., New York, 446, (1969).
17. R. Tanaka, Y. Iwasaki, H. Koprowski, Intracisternal virus-like particles in brain of a multiple sclerosis patient, J. Neurol. Sci., 128:121-126 (1976).
18. J. S. Burks, B. L. Devald, L. D. Jankovsky, J. C. Gerdes, Two coronaviruses isolated from central nervous system tissue of two multiple sclerosis patients, Science, 209:933-934 (1980).
19. A. Salmi, B. Ziola, T. Hovi, M. Reunanen, Antibodies to coronaviruses OC43 and 229E in multiple sclerosis patients, Neurology, 32:292-295 (1982).
20. S. A. Stohlman, J. F. Frelinger, Macrophages and Resistence to JHM virus CNS infection, in: "Biochemistry and Biology of Coronaviruses," V. ter Meulen, S. Siddell and H. Wege, eds., Plenum Press, New York, 387-398 (1981).