

Case Study 27

Posterior Scleritis

MH is a 21-year-old man who complained of pain behind his left eye and reduction in vision. Examination found a slightly elevated lesion temporal to the macula. A malignant tumor was included among the diagnostic possibilities. B-scan revealed choroidal and lateral rectus tendon thickening (Fig. 1). This picture was felt most consistent with posterior scleritis with involvement of the lateral rectus tendon, and the patient responded rapidly to a tapering dose of prednisone.

Suspicious conjunctival lesions can sometimes be associated with intraocular or orbital processes.

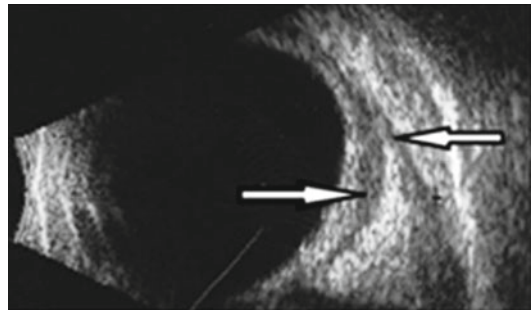


FIG. 1 B-scan of subtenon's lucency (*first arrow*) with adjacent lateral rectus tendon thickening (*second arrow*)