

Erratum

Urogynecology: Evidence-Based Clinical Practice Kate H. Moore

ISBN 978-1-4471-4290-4

On page 43, Figure 4.6 has been changed, as it was formerly incorrect. However, the legend is the same.

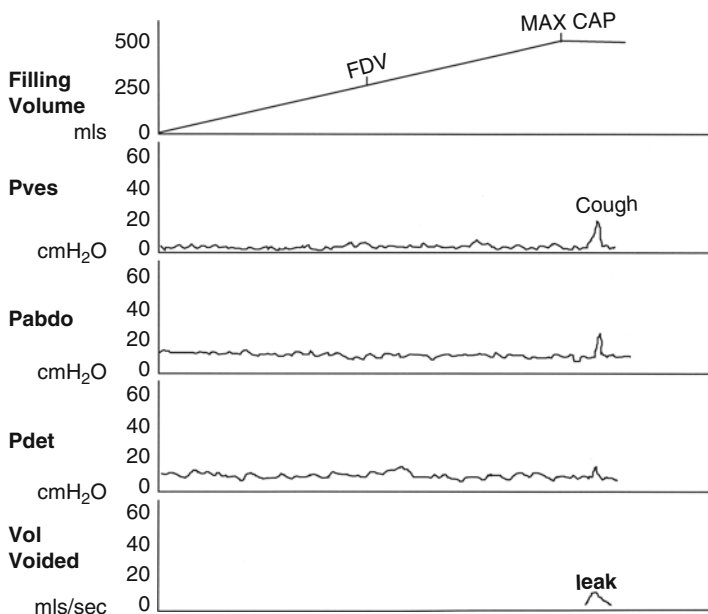


FIGURE 4.6 Urodynamic stress incontinence, with a normal FDV, SDV, and MCC, no detrusor contractions (Pves and Pdet remain flat) but obvious leak of fluid with cough

On page 44, Figure 4.7 has been changed, as it was formerly incorrect. However, the legend is the same.

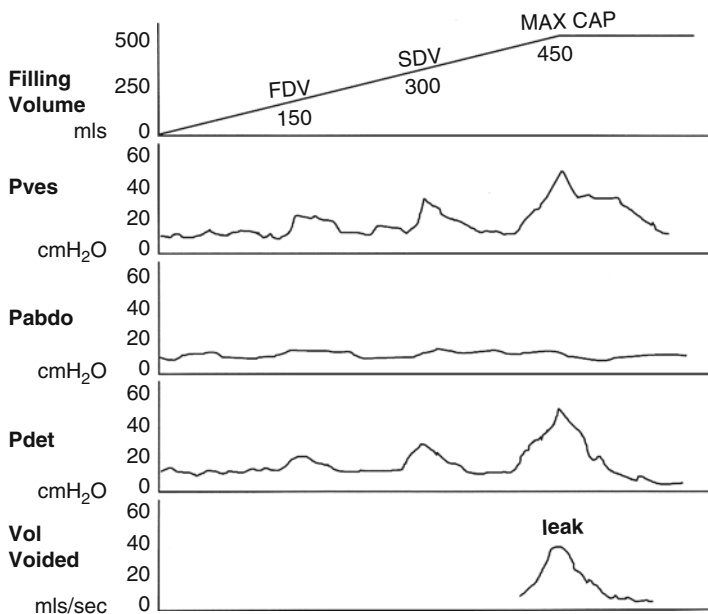


FIGURE 4.7 Detrusor overactivity with systolic waves of detrusor contractions, seen at FDV and at MCC. Stress leak does not occur