



## Correction to: Neuronopathic Gaucher disease presenting with microcytic hypochromic anemia

Eun Ah Kim<sup>1</sup> · Young Tae Lim<sup>1</sup> · Jeong Ok Hah<sup>2</sup> · Young Bae Sohn<sup>3</sup> · Yu Kyung Kim<sup>4</sup> · Joon Hyuk Choi<sup>5</sup> · Sae Yoon Kim<sup>1</sup> · Kyung Mi Jang<sup>1</sup> · JiYoung Ahn<sup>1</sup> · Jae Min Lee<sup>1</sup> 

Published online: 10 January 2019  
© Japanese Society of Hematology 2019

**Correction to: International Journal of Hematology**  
<https://doi.org/10.1007/s12185-018-2559-3>

In the original publication of this article, Fig. 2 was published incorrectly. The correct Fig. 2 is given in the following page.

**Publisher's Note** Springer Nature remains neutral with regard to jurisdictional claims in published maps and institutional affiliations.

---

The original article can be found online at <https://doi.org/10.1007/s12185-018-2559-3>.

---

✉ Jae Min Lee  
mopic@hanmail.net

- <sup>1</sup> Department of Pediatrics, Yeungnam University College of Medicine, Daegu, Republic of Korea
- <sup>2</sup> Department of Pediatrics, Daegu Fatima Hospital, Daegu, Republic of Korea
- <sup>3</sup> Department of Medical Genetics, Ajou University Hospital, Ajou University School of Medicine, Suwon, Republic of Korea
- <sup>4</sup> Department of Clinical Pathology, School of Medicine, Kyungpook National University, Daegu, Republic of Korea
- <sup>5</sup> Department of Pathology, Yeungnam University College of Medicine, Daegu, Republic of Korea

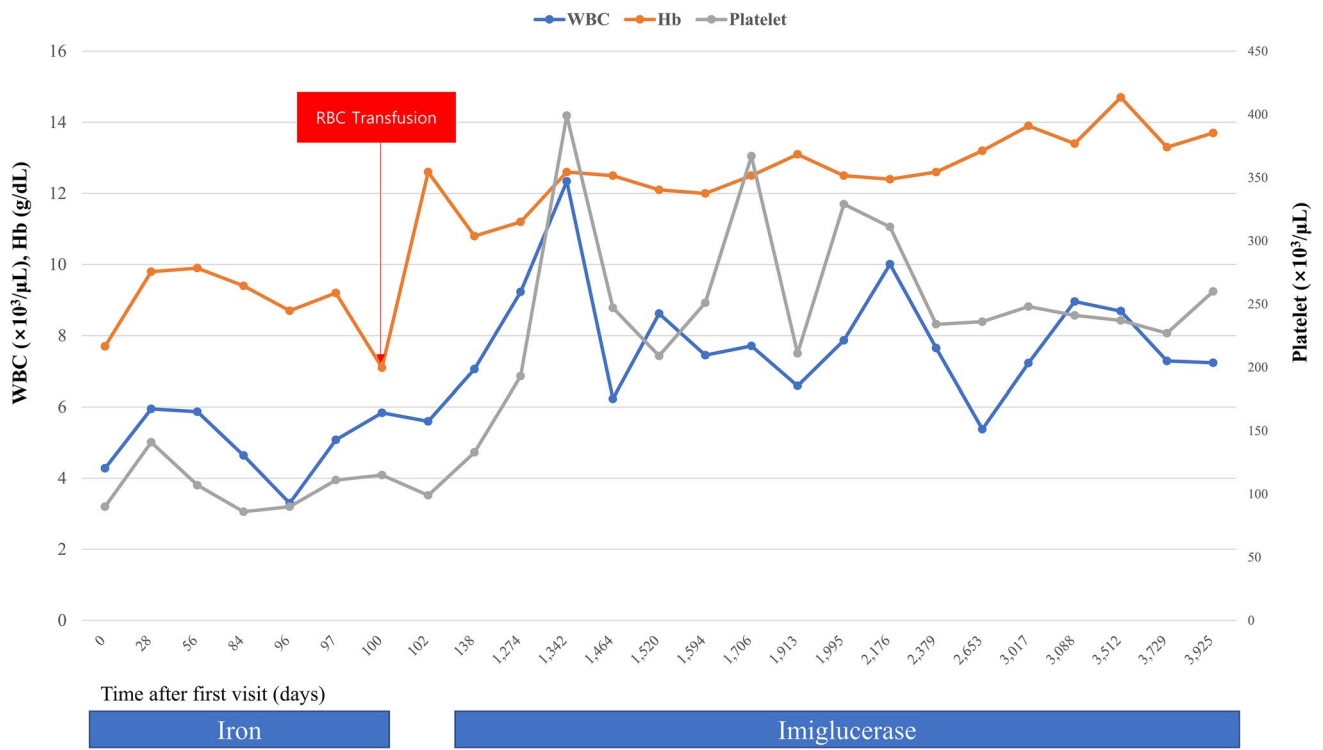


Fig. 2 Hematologic profile change during ERT, RBC TF, and red blood cell transfusion