General Thoracic and Cardiovascular Surgery (2018) 66:577–580
https://doi.org/10.1007/s11748-018-0924-z

CASE REPORT

Use of Bioglue™ to seal a difficult to treat air leak in a complicated empyema patient

Vasileios Kouritas[1] · Emmanouel Kefaloyannis[1] · Peter Tcherveniakov[1]

Received: 14 November 2017 / Accepted: 9 April 2018 / Published online: 25 April 2018

Abstract
Surgical sealants have been used in thoracic surgery in an effort to reduce air leak duration, intercostal drain duration, length of stay and complications. They are instilled over a defect usually treated with other means. We herein present the technique of controlling a difficult to treat defect by directly instilling Bioglue™ alone into a crater, caused during empyema Video-assisted thoracic surgery in a 50-year-old patient with a trapped lung. This deep crater had caused a significant air leak rendering intraoperative ventilation challenging. After instillation, the dependent lung was kept blocked. With this technique, the Bioglue™ polymerized and the air leak was dramatically decreased making ventilation and eventually extubation of the patient feasible. Instillation of Bioglue™ directly into a large lung defect could be a choice of action to decrease complicated air leaks, otherwise impossible to treat with other means, in patients with trapped lung.

Keywords Bioglue™ · Empyema · Air leak · Complicated defect · Trapped lung

Introduction

Tissue sealants are used in thoracic surgery, after lung resections, in an effort to decrease the intercostal drain stay, air leak duration and length of stay. The use of such sealants has been shown to be safe and effective. Their use usually augments other means of controlling air leaks, i.e., stapling or suturing [1, 2].

We herein present the technique of instilling Bioglue™ directly into the lung defect in an attempt to cease a significant air leak in a complex empyema patient.

Case presentation

A 50-year-old male was referred to our department for surgical management of a left chest empyema (Fig. 1a, b). *Escherichia coli* was cultured from previous pleural aspiration. The patient had previously received conservative treatment (antibiotics with meropenem and ultrasound guided drain for 2 weeks in a peripheral hospital) and required admission to the intensive care unit (1 week).

His past medical history was significant and included laryngeal cancer with laryngectomy and permanent tracheostomy, schizophrenia, severe COPD and drug abuse. His nutritious status was poor, with a performance status of 2/3. His preoperative albumin level was 14 g/L and his lymphocyte absolute count was 700 (/mm^3). A weight loss of 12 kg was documented (since initial admission to another peripheral hospital). His inflammatory markers were high with a neutrophil count of 21.400 (/mm^3) and a C-reactive protein value of 323 mg/dL. He was continuously pyrexial, with a fever of above 38.5 °C.

The patient was taken through a preoperative anesthesiology review and was rendered high risk. Upon evaluation, consensus noted that he would not withstand one-lung ventilation. It was decided that a simple washout with single lumen endotracheal tube intubation would be performed for the initial control of the infection.

During the procedure, a 2-cm single VATS incision was performed over the dependent area over the lateral chest and a 30° 10-mm camera was introduced. The lung was trapped with a thick cortex and was firmly adherent at the apex. Many thin-walled loculations were divided. Upon division of an adhesion, a deep "crater-like" defect was created, resulting in a significant air leak causing inability

✉ Vasileios Kouritas
vasileios@doctors.org.uk

[1] Department of Thoracic Surgery, St. James's University Hospital, Leeds LS9 7TF, UK

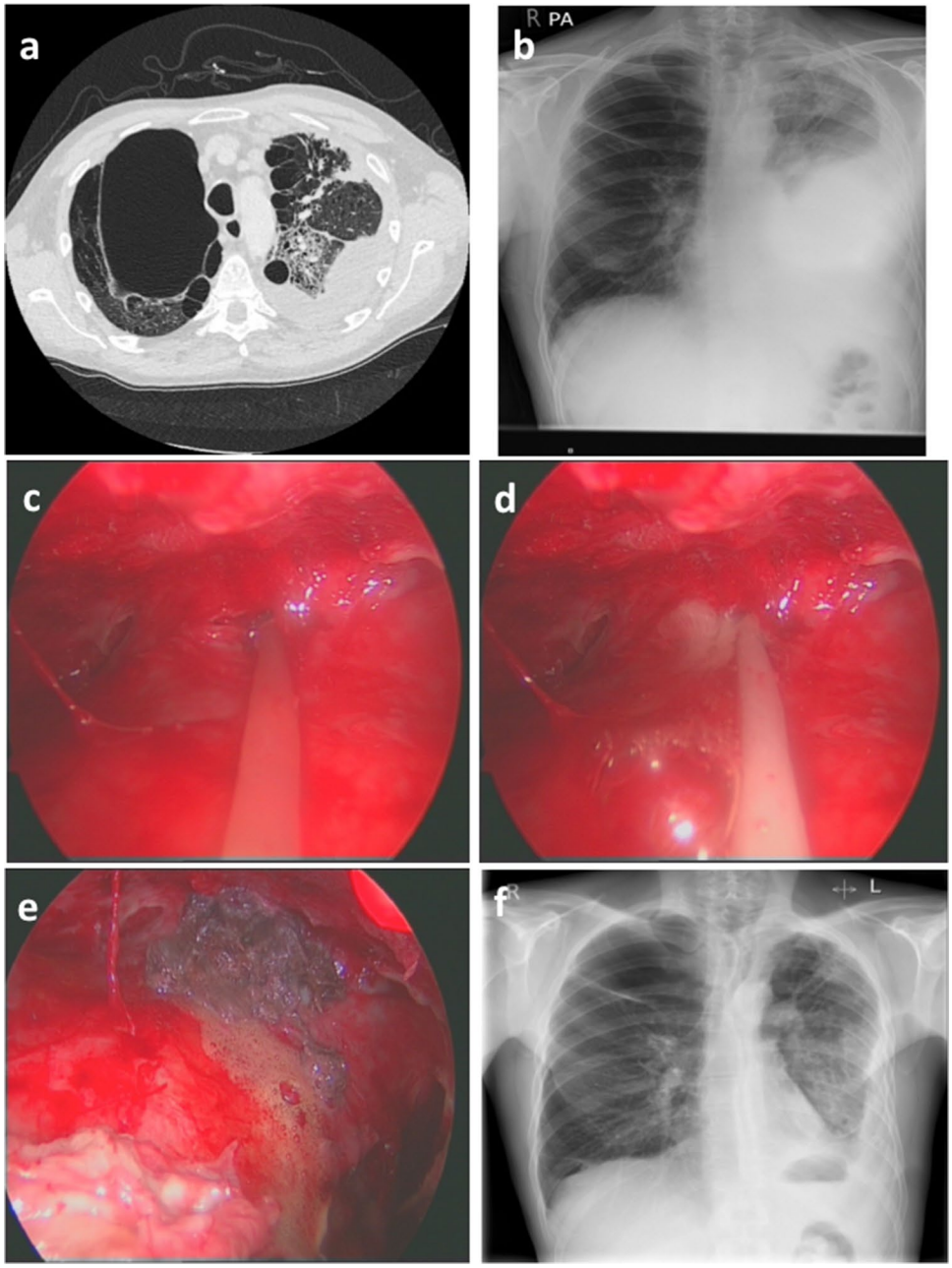

Fig. 1 Preoperative CT scan and chest X-Ray (**a, b**), instillation of the Bioglue™ technique (**c**–**e**) and postoperative result of the presented case (**f**)

to ventilate the patient on two lungs. A left-sided bronchial block was inserted temporarily to achieve ventilation.

With the left lung blocked, 10 mL of Bioglue™ (Cryolife Inc., USA) were instilled directly into the defect (into the deep crater), which was then covered with Surgicel™ (Ethicon USA, Fig. 1c–e). The left lung remained blocked, allowing time for the glue to polymerize and simultaneously a washout was conducted. Two 28Fr drains were inserted, the Surgicel™ was removed and closure was expedited as the patient started desaturating since the left lung remained blocked until extubation.

The patient remained in the high dependency unit for 2 days postoperatively and was apyrexial after the procedure. His inflammatory markers showed improvement from POD2 (normalized on POD4). He remained on antibiotics for 3 weeks. He was transferred to the ward on POD3 and his nutrition also showed improvement, with his albumin increasing to 38 mg/L before discharge.

Immediately postoperatively the air leak was small and completely ceased on POD6 where after the patient was discharged without drains (Fig. 1f).

Discussion

We herein present the technique of filling up a "hole"-like defect with Bioglue™ in an attempt to cease significant air leaks in complicated thoracic surgery cases. After instillation, the patient remains on one-lung ventilation and is extubated if possible without unblocking the treated lung or without going on two-lung ventilation. This technique can provide an alternative course of action in complex cases where there is an injury in a trapped lung causing significant air leak, which is difficult to control with other means. To our knowledge, this is the first time that this technique is been presented.

An injury in a trapped lung can be troublesome, as the inability of the lung to totally re-expand and re-occupy the whole pleural cavity cannot seal off the air leak. In some of these cases, it may be difficult to even ventilate the patient on two lungs, with the anesthetist facing a challenging extubation, due to the significant air leak through the defect. In our case, filling up the defect with Bioglue™ considerably decreased the air leak making extubation of the patient feasible.

An important air leak in a non-expanding lung could logically incur longer air leak duration, longer intercostal drain stay, longer in-hospital stay and possibly morbidity. With the presented technique, the air leak decreased immediately and dramatically, enabling the patient to be ventilated initially and to be discharged without intercostal drains avoiding in this way further complications.

In the presented case suturing of the defect, if at all feasible, would result in further air leak. Full decortication could not be performed, as the patient was too unwell to withstand an extensive operation. Insertion of endobronchial valves was not an option, as there were no available valves in stock and two-lung ventilation, which is necessary to identify the leaking bronchi, was not feasible. Additionally, another technique of sealing off the defect would have been to create a muscle flap, which then could be superimposed over the laceration. Unfortunately, in this instance, a fast solution was necessitated, as the patient could not be ventilated. The reported technique can be life saving in cases of a trapped lung with a big defect, which is causing inability to ventilate.

When attempting to cease air leaks, the common application of similar products is by spreading it over the stapling lines or the defects [3]. Lately, to minimize the spreading of glue outside the field of interest (air leak), a frame was suggested to be used [4]. According to the presented technique, the Bioglue™ could not only be used on superficial parenchymal lacerations or as a reinforcement of anastomosis/suturing lines but alternatively could be instilled directly into the big "crater-like" defect while the lung remains collapsed to allow the glue product to polymerize. By instilling the glue into the defect rather than on top of it could prevent spreading outside the field of interest.

The Bioglue™ is widely used as a hemostatic agent (in specific countries) but it does posses a product certificate to be used on soft tissues, the lung parenchyma included, when there is failure of other conventional techniques to address the problem. Despite the fact that the glue is a foreign body and induces an inflammatory response, it has not been proven to interfere with the healing process [5, 6].

The use of these glue in infected environments can be dubious, as it could promote infection. Its use, however, has tentatively been expanded to treat cases of bronchopleural fistulas, rendering its use safe in infected environments [7]. In our case, the use of Bioglue™ was used in an emergency manner as there were no alternatives to achieve ventilation of the patient. The postoperative improvement of the inflammatory status of the patient supports the notion that Bioglue™ is safe to be used in infected environments.

Conclusion

In conclusion, in cases where a clinically significant and deep lung laceration cannot be sealed with other means, the instillation of Bioglue™ directly within the defect and maintaining the dependent lung blocked, could be a vital option and alternative course of action.

Compliance with ethical standards

Conflict of interest VK, EK and PT have declared that no conflict of interest exists.

References

1. Park BJ, Snider JM, Bates NR, Cassivi SD, Jett GK, Sonett JR, Toloza EM. Prospective evaluation of biodegradable polymeric sealant for intraoperative air leaks. J Cardiothorac Surg. 2016;11:168.
2. Belda-Sanchís J, Serra-Mitjans M, Iglesias Sentis M, Rami R. Surgical sealant for preventing air leaks after pulmonary resections in patients with lung cancer. Cochrane Database Syst Rev. 2010;1:CD003051.
3. Kawai H, Harada K, Ohta H, Tokushima T, Oka S. Prevention of alveolar air leakage after video-assisted thoracic surgery:

comparison of the efficacy of methods involving the use of fibrin glue. Thorac Cardiovasc Surg. 2012;60:351–5.
4. Bures M, Zardo P, Länger F, Zhang R. Improved application technique of albumin-glutaraldehyde glue for repair of superficial lung defects. J Cardiothorac Surg. 2016;11:149.
5. Herget GW, Kassa M, Riede UN, Lu Y, Brethner L, Hasse J. Experimental use of an albumin-glutaraldehyde tissue adhesive for sealing pulmonary parenchyma and bronchial anastomoses. Eur J Cardiothorac Surg. 2001;19:4–9.
6. Wertzel H, Wagner B, Stricker A, Swoboda L, Hasse J, Lange W, Freudenberg N. Experimental gluing of lung parenchyma in rats. Thorac Cardiovasc Surg. 1997;45:83–7.
7. Potaris K, Mihos P, Gakidis I. Preliminary results with the use of an albumin-glutaraldehyde tissue adhesive in lung surgery. Med Sci Monit. 2003;9:79–83.