European Journal of Nuclear Medicine and Molecular Imaging (2018) 45:816–821
https://doi.org/10.1007/s00259-018-3943-1

EDITORIAL

Life is not black and white, nor just Shades of Gray

T. Beyer[1] · R. J. Hicks[2] · L. S. Freudenberg[3]

Received: 29 December 2017 / Accepted: 5 January 2018 / Published online: 8 February 2018

"We look at the present through a rear-view mirror. We march backwards into the future."
Marshall McLuhan, 1967 [1]

Healthcare underpins the wellbeing of mankind. It is manifested by our ability to diagnose disease and to treat patients effectively. Naturally, the better we understand a disease, the more accurate we can be in its diagnosis and the more effectively we can be in treating it. Over the centuries, our skills in these domains have continually improved. Today, our diagnostic armamentarium includes multiple, noninvasive imaging methods, including computed tomography (CT), magnetic resonance imaging (MRI) [2], single photon emission computed tomography (SPECT) and positron emission tomography (PET) [3]. Although we tend to dichotomize these into anatomical and molecular or functional imaging modalities, there is often physiological and chemical information that can be derived from the former and anatomical structure can be recognized in the latter.

All of these imaging modalities are exciting instrumentational and methodological approaches to diagnosing and characterizing diseases [4]. Anatomical and functional imaging coexisted for decades until, in the 1990s, the use of combined "anato-metabolic" imaging [5] was proposed and subsequently resulted in the introduction of combined SPECT/CT [6], PET/CT [7] and then PET/MR systems [8] in the first decade of the twenty-first century. Although the adoption of these hybrid imaging systems has varied widely over time and across regions, their clinical traction has grown with resulting diagnostic benefit across a variety of clinical applications [9–11].

The ultimate goal of technological progress in diagnostic medicine should be to maximize diagnostic quality and, thus, positively influence patient management and benefit wellbeing. Yet it is noticeable from evidence in the literature and our own insights into the clinical practice of our expert colleagues that hybrid imaging is often not used to its full potential due to failure to integrate complementary medical expertise for the maximum benefit of patients. While there is much focus on reducing radiation exposure according to principles known by the acronym ALARA (as low as reasonably achievable), we believe that similar attention should be given to the clinical performance of imaging tests, which could be termed AHADA (as high as diagnostically achievable).

At the time of stand-alone anatomical and molecular medicine imaging, radiology and nuclear medicine progressively moved apart and came to be represented by different professional societies in most countries. When hybrid imaging was introduced in the form of SPECT/CT, PET/CT and – perhaps most vividly – PET/MR, both groups were taken by surprise. While hybrid imaging originated from pioneering work in the nuclear medicine community with cross-disciplinary teams of physicists, engineers and medical doctors [12], perceptions of how hybrid imaging technologies might be used were subject to an ownership bias [13]. Such bias was born and voiced with the introduction of the whole-body PET/CT concept in the late 1990s, as illustrated by comments such as: "I think fusion is overblown in reputation. Good nuclear medicine physicians can correlate just as well using internal landmarks", and "Many nuclear medicine physicians interpret CT images more accurately than trained radiologists" [14]. Later, during the clinical adoption of hybrid imaging, comments such as these were made: "PET/CT is the death of nuclear medicine" (personal communication; anonymous delegate at the Annual Meeting of the German Nuclear Medicine Society, 2000), or "We estimate that there is a need to look at CT scans in

✉ T. Beyer
thomas.beyer@meduniwien.ac.at

[1] QIMP Group, Centre Medical Physics and Biomedical Engineering, Medical University Vienna, Währinger Str 18-20/4L, 1090 Vienna, Austria

[2] The Sir Peter MacCallum Department of Oncology, The University of Melbourne, Melbourne 3000, Australia

[3] ZRN Rheinland, Ueberseite 88, 41352 Korschenbroich, Germany

roughly 20% of patients. … PET/CT will have only a modest objective impact" [15]. Conversely, many radiologists felt that PET provided simply another form of contrast enhancement for high-resolution structural imaging.

Although, hybrid imaging accounts for only a comparatively small part of diagnostic medicine, it has contributed to growing friction between radiologists and nuclear medicine physicians. While common-sense suggests that hybrid imaging data should be interpreted by experts in both anatomical and molecular imaging, professionals from either background, or their respective societies, have often shown little willingness or ability to work together and their approach has often been antagonistic rather than collaborative. This antagonism has been strengthened further by billing and regulatory requirements that have frequently preferred workflow scenarios in which radiology expertise and nuclear medicine expertise are clearly separated. Not only does such a requirement block an integrated adoption of hybrid imaging, but it also yields separate reports for the CT, or MRI and PET, or SPECT portion; a nuisance to the referring physician.

Hybrid imaging comes with a number of advantages over stand-alone imaging. On the nuclear medicine side, the advantages include better localization of molecular imaging findings [16], replacing the "poor man's CT" of ^{68}Ge-based transmission scans for both this purpose [17], and the ability to provide more efficient attenuation correction [18, 19]. Accordingly, the majority of studies performed in nuclear medicine facilities utilize a "low-dose CT" with little attention paid to the full capabilities of combined imaging. Radiology practices tend, on the other hand, to perform CT or MR examinations using protocols identical to those for stand-alone studies and reference "PET contrast" only in so far as it confirms radiological findings. Although only a minority of groups have adapted PET/CT acquisition protocols to optimize information obtained from both the nuclear medicine and the radiology perspective they have documented convincing positive results [20, 21]. And while the "nuclear medicine approach" dominates in Europe and the "radiology approach" is more common in the US, the paucity of truly combined reporting of hybrid imaging is independent of geographical location [22, 23].

Whole-body PET/CT was introduced in 2001 and multiple generations and updates of PET/CT have since improved diagnostic image quality. Nevertheless, an international survey performed in 2011 demonstrated that the majority of PET/CT users still employed CT contrast agents in only a small proportion of patients [22]. Likewise, in a survey performed in 2014 among international SPECT/CT users, an overwhelming majority of respondents wanted to employ their SPECT/CT system as a SPECT system with attenuation correction and coarse anatomical localization rather than to implement closer integration of radiology-driven imaging perspectives [23]. Finally, one of the first clinical papers on PET/MR promoted the sufficiency of a "low-signal" sequence, typically used for MR-based attenuation correction [24], synonymous to a low-dose CT scan, for the anatomical localization of the PET findings [25]. These are but a few examples of the disconnect between the diagnostic professions at the apogee of combined imaging, which coincides with the most deterring phase of interaction between the two professions (Table 1).

Nevertheless, in Europe at least, both professional groups have recognized the need for appropriately trained clinical readers in hybrid imaging and that there is overlapping responsibility for developing practice quality guidelines. Consequently, a white paper was published by the European Association of Nuclear Medicine (EANM; www.eanm.org) and the European Society of Radiology (ESR; www.esr.org) as a "result of the working party negotiations of EANM and ESR delegations throughout … 2005 and … 2007". This paper, which was published in both leading European journals for radiology [26] and nuclear medicine [27], stated explicitly that "new multimodality imaging systems … require the competency and accreditation of individuals from both nuclear medicine and radiology". Moreover, in light of the physical combination of anato-metabolic imaging methods, the demarcation of both associated professions was referred to as having "become less evident as newer imaging techniques have been introduced". This echoed a desire to bring the two specialties closer together. This was an aspiration first articulated as early as 1999: "Fused PET/CT imaging should strengthen and improve the relationship between PET specialists and radiologists" [14].

Following the publication of the white paper, a more cooperative period existed for a time. This involved several high-level efforts to integrate complementary professionals into teaching and training efforts at annual meetings. Notwithstanding these – mainly local – cooperation efforts, professional societies have recently expressed a stronger intention to control hybrid imaging, thereby ignoring the potential benefits of truly combined imaging [11]. Further, such attempts to segregate the specialties jeopardize the implementation of hybrid imaging as an integral part of a convergent approach to medicine (http://www.convergencerevolution.net/).

We suggest that the conflicts around hybrid imaging that we witness today (Table 1) originate to a large extent from nostalgia for the practice of imaging prior to the availability of hybrid imaging and entrenched modes of thought developed during the training of some older clinicians. To assess how such views affect the new generation of young professionals who have been exposed only to this period of merging technologies and practices, we have set out to probe opinions regarding hybrid imaging and collaboration or separation of the specialties of radiology and nuclear medicine. Specifically, we have initiated an international survey "Hybrid Imaging Training" following the organization of a hybrid imaging course

Table 1 Four phases of professional interactions over combined imaging

Year	Phase	Description
2000–2005	Segregation	Two groups of users: as little nuclear medicine involvement with radiology and joint group cross-fertilization as possible
2005–2010	White paper	Consensus papers of European associations of radiology and nuclear medicine, recognizing the need to cooperate over hybrid imaging
2010–2015	Joining efforts	Major professional associations organize joint sessions in their respective annual meetings and create a shared faculty
2015 to today	Separation	Termination of joint efforts; aggressive statements; stand-still of joint training efforts

(http://eshi-society.org/courses/) (http://www.esor.org/cms/website.php?id=/en/programmes/esor_courses_for_edir/hybrid_imaging.htm). The survey was launched through an extensive email distribution and was advocated through the Aunt Minnie community on 2 October 2017. In total, 248 eligible responses were collected between 2 October and 16 October 2017.

Responses were received mainly from Europe (78%). Most respondents worked in a radiology department (48%). One fourth of the respondents had not yet achieved board certification, one fifth were certified in nuclear medicine and a slightly smaller proportion were dual-certified. Half of the respondents said they had up to 4 years of experience with hybrid imaging while one third indicated no experience at all. Most interestingly, the majority (72%) commented that there were too few hybrid imaging experts available in their country. Only 16% considered there were as many hybrid experts as needed. Less than half the respondents (43%) indicated they were very confident in reporting hybrid images (Fig. 1). Three quarters of the respondents were in favour of a curriculum enabling subspecialization in hybrid imaging (75% worldwide, 73% in Europe). Interestingly, most opponents were radiologists by training. When asked about a joint curriculum along the lines of the suggested training options laid out in the white paper [26, 27], 87% responded positively, with the proportion of proponents increasing somewhat with years of professional experience. Both responses are in line with the survey conducted among EANM and ESR members in 2010, in which 77% and 85%, respectively, supported an interdisciplinary training programme [28]. This survey confirms our personal experience that the majority of medical professionals in the domains of both radiology and nuclear medicine want to engage in continuous education on hybrid imaging and there is ongoing interest in joint training programmes.

In theory, such joint training programmes should be developed by the professional societies with a curriculum that acknowledges the need to pair complementary expertise for interpreting combined imaging. This would mandate cooperation of the respective societies. Figure 2a shows the average ratings of survey respondents of the level of cooperation (*1* very low, *10* very high) between the two specialties at the local, national and European levels. Not surprisingly, the overall level of satisfaction with the degree of cooperation was low. The same observation was made across responses from European countries only (Fig 2b).

Even though our survey indicated that over half (54%) of respondents were unaware of the white paper [26, 27], two main messages were apparent. First, users were aware that imaging has become much more multidisciplinary, and felt that radiology and nuclear medicine experts should team up. Second, users want to see a range of accessible high-level training models that were described by the white paper as "a prerequisite for high-quality image interpretation with hybrid systems". Training options may extend from integrated training in both specialties (dual certification), as pursued by some centres in the smaller category of joint users (Table 1), or adding a subspecialization after completing a full training in one specialty, up to a common trunk scenario, as one possible future scenario, which has been introduced in The Netherlands [29] and that some argue should be implemented elsewhere [30].

Looking at the clinical hybrid imaging landscape today, we are reminded of the concept of "habitus" [31] introduced by Bourdieu and Loïc [32], who described habitus as:

> A system of embodied dispositions, tendencies that organize the ways in which individuals perceive the social world around them and react to it. These dispositions are usually shared by people with similar background […] and reflect the "lived reality" to which individuals are socialized, their individual experience and objective opportunities. Thus, the habitus represents the way group culture and personal history shape the body and the mind, and as a result, shape social action in the present.

We believe that fundamental differences in physiology and anatomy has led to different habitus in the two specialist fields with respect to imaging, patient care, and self-perception. One specific feedback from the above survey was: "Nuclear medicine physicians are better physicians; radiologists are better imagers". Perhaps this type of statement in the light of clinical hybrid imaging lends itself to the definition of a new mindset for hybrid "anato-

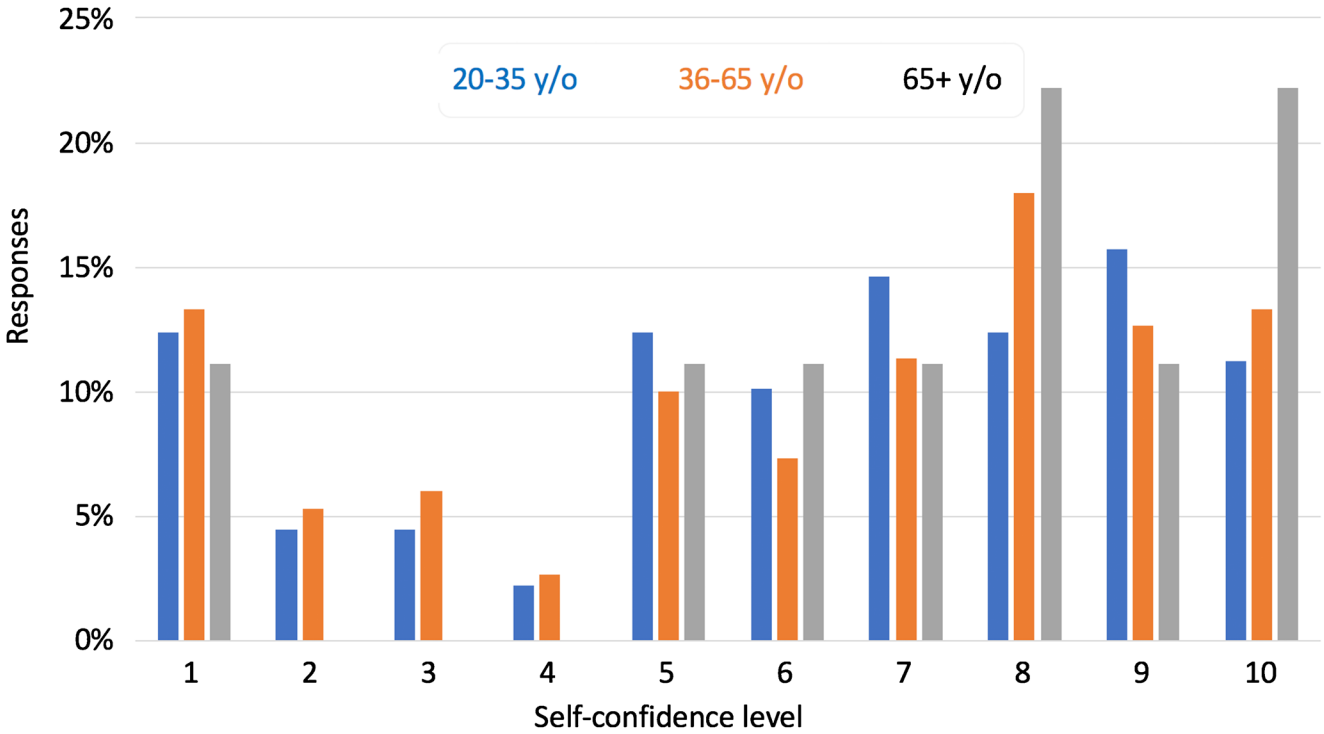

Fig. 1 Self-confidence of respondents in reporting hybrid images (*1* no confidence, *10* very confident) per age category

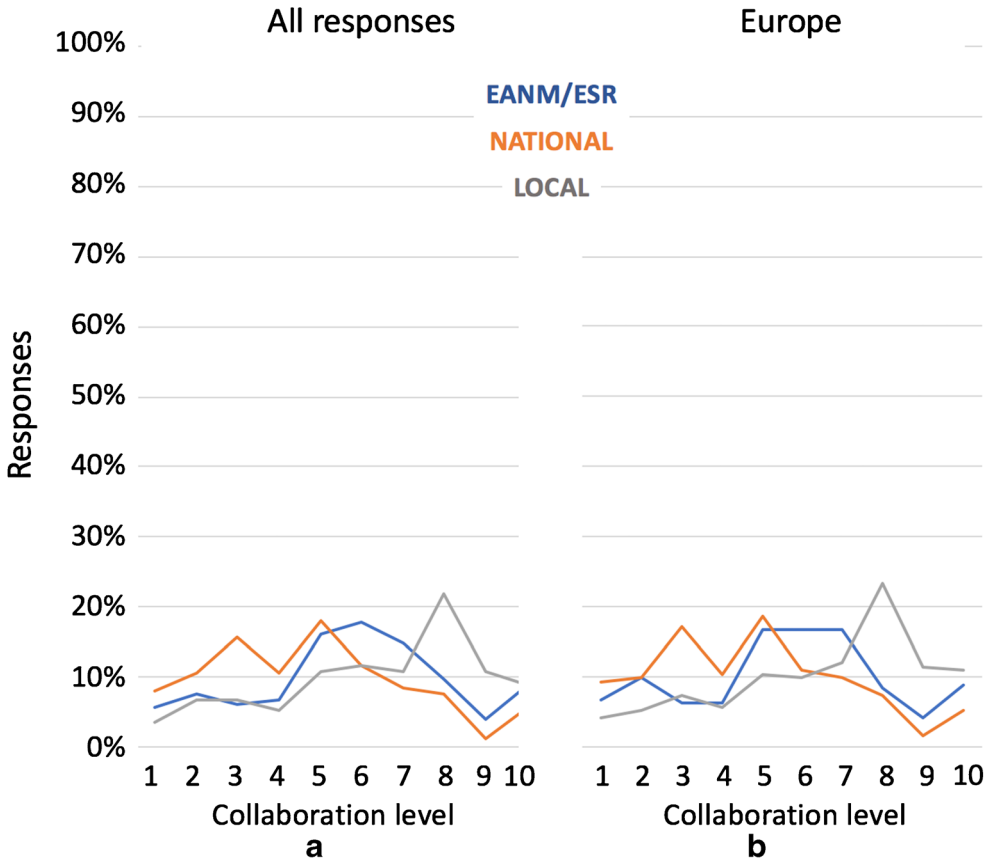

Fig. 2 Levels of collaboration (*1* very low, *10* very high) between radiologists and nuclear medicine specialists at the local (on-site), national and European levels: **a** all 248 respondents; **b** European respondents only

metabolic imagers", which could be addressed from the start through more intense collaboration, or, even better and more sustainably, by a joint training and education path that would help bridge the minds of nuclear medicine physicians and radiologists, since we are certain that they do both care about their patients.

Let us recall that the white paper of 2007 closed by stating "Both organizations [ESR and EANM] are committed to working together for the future benefit of both specialties" [26, 27]; this statement has not yet materialized and also fails to recognize that our common goal should be patient-focused care, not professional hegemony over imaging technologies. Common sense and healthcare requirements mark the need for cooperation between the two specialties and a persistent wish for a strategy towards interdisciplinary training [28, 33, 34] or alternative forms of restructured training modules to account for multimodality imaging [35]. As early adopters of hybrid imaging, we suggest that we should seek to explore the numerous opportunities of hybrid imaging for the benefit of patient management and healthcare systems. We should seize the opportunities of presenting high-sensitivity molecular information in judiciously tailored anatomical and morphological reference frames. The best diagnostic quality obtained and presented in a clinically viable context will help engage therapists in finding the optimum therapy for every patient. At the same time, hybrid imagers, and not just single-imaging experts, must engage with other medical specialties in an attempt to merge knowledge about diseases to build models that help predict and assess the disease of other patients in the future. Indeed, big data could get even bigger with hybrid images.

If we continue with the existing professional impasse by thinking along the lines of "What can hybrid Imaging do for me?" rather than asking "What can we do with hybrid Imaging for others?", we will harm ourselves, but most importantly we will do a disservice to society and our patients. Hybrid imaging examinations are faster, more convenient for patients and, frequently, provide better diagnostic quality because of the conjoined use of complementary image information. In short, hybrid imaging is more than the sum of its parts [36]. It is time that we appreciate the potential of the technologies that progress has provided us with and that we conceive an environment that brings these technologies, in this case hybrid imaging, to their optimum traction. The world is not black and white, nor shades of gray; hybrid imaging brings colour to the fore with illumination of the path for the individual patient being key.

Compliance with ethical standards

Conflicts of interest None.

Ethical approval This article does not describe any studies with human participants performed by any of the authors.

References

1. McLuhan M, Fiore Q. The medium is the massage: an inventory of effects. New York: Bantam Books; 1967.
2. Brant W, Helms C. Fundamentals of diagnostic radiology. Philadelphia: Lippincott Williams & Wilkins; 2007.
3. Valk PE, Bailey DL, Townsend DW, Maisey MN. Positron emission tomography. Basic science and clinical practice. London: Springer; 2003.
4. James ML, Gambhir SS. A molecular imaging primer: modalities, imaging agents, and applications. Physiol Rev. 2012;92(2):897–965.
5. Wahl RL, Quint LE, Cieslak RD, Aisen AM, Koeppe RA, Meyer CR. "Anatometabolic" tumor imaging: fusion of FDG PET with CT or MRI to localize foci of increased activity. J Nucl Med. 1993;34:1190–7.
6. Patton JA, Delbeke D, Sandler MP. Image fusion using an integrated, dual-head coincidence camera with X-ray tube-based attenuation maps. J Nucl Med. 2000;41(8):1364–8.
7. Beyer T, Townsend DW, Brun T, Kinahan PE, Charron M, Roddy R, et al. A combined PET/CT tomograph for clinical oncology. J Nucl Med. 2000;41(8):1369–79.
8. Schlemmer H, Pichler BJ, Schmand M, Burbar Z, Michel C, Ladebeck R, et al. Simultaneous MR/PET imaging of the human brain: feasibility study. Radiology. 2008;248(3):1028–35.
9. Bockisch A, Freudenberg LS, Schmidt D, Kuwert T. Hybrid imaging by SPECT/CT and PET/CT: proven outcomes in cancer imaging. Semin Nucl Med. 2009;39(4):276–89.
10. Beyer T, Veit-Haibach P. State-of-the-art SPECT/CT: technology, methodology and applications-defining a new role for an undervalued multimodality imaging technique. Eur J Nucl Med Mol Imaging. 2014;41(Suppl 1):S1–2.
11. Bailey D, Pichler BJ, Gückel B, Antoch G, Barthel H, Bhujwalla ZM, et al. Combined PET/MRI: global warming – summary report of the 6th International Workshop on PET/MRI, March 27–29, 2017, Tübingen, Germany. Mol Imaging Biol. 2018;20(1):4–20.
12. Townsend D. Multimodality imaging of structure and function. Phys Med Biol. 2008;53(4):R1–R39.
13. Beyer T, Freudenberg LS, Czernin J, Townsend DW. The future of hybrid imaging – part 3: PET/MR, small-animal imaging and beyond. Insights Imaging. 2011;2(3):235–46.
14. Wagner H. Fused image tomography: where do we go from here? J Nucl Med. 1999;40(9):30N–1N.
15. Jager P, Slart RH, Corstens F, Oyen WJ, Hoekstra O, Teule J. PET-CT: a matter of opinion? Eur J Nucl Med. 2003;30(3):470–1.
16. Hany TF, Steinert HC, Goerres GW, Buck A, von Schulthess GK. PET diagnostic accuracy: improvement with in-line PET-CT system: initial results. Radiology. 2002;225(2):575–81.
17. Kinahan P, Hasegawa B, Beyer T. X-ray based attenuation correction for PET/CT scanners. Semin Nucl Med. 2003;XXXIII(3):166–79.
18. Kinahan PE, Townsend DW, Beyer T, Sashin D. Attenuation correction for a combined 3D PET/CT scanner. Med Phys. 1998;25(10):2046–53.
19. LaCroix KJ, Tsui BM, Hasegawa BH, Brown JK. Investigation of the use of X-ray CT images for attenuation compensation in SPECT. IEEE Trans Nucl Sci. 1994;41:2793–9.
20. Antoch G, Freudenberg LS, Beyer T, Bockisch A, Debatin JF. To enhance or not to enhance? 18F-FDG and CT contrast agents in dual-modality 18F-FDG PET/CT. J Nucl Med. 2004;45(Suppl 1):56S–65S.
21. Pfannenberg A, Aschoff P, Brechtel K, Müller M, Klein M, Bares R, et al. Value of contrast-enhanced multiphase CT in combined PET/CT protocols for oncological imaging. Br J Radiol. 2007;80(954):437–45.

22. Beyer T, Czernin J, Freudenberg L. Variations in clinical PET/CT operations: results from an international survey among active PET/CT users. J Nucl Med. 2011;52(2):303–10.
23. Wieder H, Freudenberg LS, Czernin J, Navar BN, Israel O, Beyer T. Variations of clinical SPECT/CT operations: an international survey. Nuklearmedizin. 2012;51(4):154–60.
24. Wagenknecht G, Kaiser HJ, Mottaghy FM, Herzog H. MRI for attenuation correction in PET: methods and challenges. MAGMA. 2013;26(1):99–113.
25. Eiber M, Martinez-Möller A, Souvatzoglou M, Holzapfel K, Pickhard A, Löffelbein D, et al. Value of a Dixon-based MR/PET attenuation correction sequence for the localization and evaluation of PET-positive lesions. Eur J Nucl Med Mol Imaging. 2011;38(9):1691–701.
26. Gourtsoyiannis N, McCall I, Reiser M, Silberman B, Bischof Delaloye A, Carrió I, et al. White paper of the European Society of Radiology (ESR) and the European Association of Nuclear Medicine (EANM) on multimodality imaging. Eur Radiol. 2007;17(8):1926–30.
27. Bischof Delaloye A, Carrió I, Cuocolo A, Knapp W, Gourtsoyiannis N, McCall I, et al. White paper of the European Association of Nuclear Medicine (EANM) and the European Society of Radiology (ESR) on multimodality imaging. Eur J Nucl Med Mol Imaging. 2007;34(8):1147–51.
28. European Association of Nuclear Medicine (EANM); European Society of Radiology (ESR). Multimodality imaging training curriculum – parts II and III. Eur J Nucl Med Mol Imaging. 2012;39(4):557–62.
29. van Schaik J, Bennink R. Integrated residency in radiology and nuclear medicine in the Netherlands. J Nucl Med. 2017;58(7):9N–11N.
30. Mankoff D, Pryma D. Nuclear medicine training: what now? J Nucl Med. 2017;58(10):1536–8.
31. Wikipedia. Habitus (sociology). 2017. https://en.wikipedia.org/w/index.php?title=Habitus_(sociology)&oldid=808327001. Accessed 31 Jan 2018.
32. Bourdieu P, Loïc J. An invitation to reflexive sociology. Chicago: University of Chicago Press; 1992.
33. Frey KA, Royal HD, Di Carli MF, Dillehay GL, Gordon L, Mankoff DA, et al. ABNM position statement: nuclear medicine professional competency and scope of practice. J Nucl Med. 2011;52(6):994–7.
34. Delbeke D, Royal HD, Frey KA, Graham MM, Segall GM. SNMMI/ABNM joint position statement on optimizing training in nuclear medicine in the era of hybrid imaging. J Nucl Med. 2012;53(9):1490–4.
35. Stegger L, Schäfers M, Weckesser M, Schober O. EANM-ESR white paper on multimodality imaging. Eur J Nucl Med Mol Imaging. 2008;35(3):677–80.
36. Beyer T, Bockisch A, Schober O. 1 + 1 = 3. Nuklearmedizin. 2005;44(Suppl 1):S1.