References

1 *Brimacombe J, Berry A.* Insertion of the laryngeal mask airway - a prospective study of four techniques. Anaesth Intensive Care 1993; 21: 89–92.

2 *Asai T.* Difficulty in insertion of the laryngeal mask. *In*: Latto IP, Vaughan RS (Eds.). Difficulties in Tracheal Intubation, 2nd ed. Philadelphia: W.B. Saunders, 1997: 177–96.

3 *Brain AIJ, Yerghese C, Addy EV, Kapila A, Brimacombe J.* The intubating laryngeal mask. II: Preliminary clinical report of a new means of intubating the trachea. Br J Anaesth 1997; 79: 704–9.

Lower extremity temperature disparity after retroperitoneal dissection

To the Editor:

Combined chemotherapy and radical surgery are employed to treat patients with testicular carcinoma. Scardino and Skinner have demonstrated bleomycin and cisplatinum therapy followed by thoracoabdominal dissection to be curative.[1] Surgery involves resection of retroperitoneal tissue and lymphatics from the pelvis to the diaphragm.[2,3] Postoperatively, 30 - 40 % of these patients present with temperature disparity between the lower extremities.

A temperature difference of this type raises concern about a cold extremity and possible vascular insufficiency or embolic complication - and can result in extensive additional workup. Furthermore, heparinization may be considered and increase the risk of postoperative bleeding. On examining these patients, we have found that the warmer leg is on the same side as the surgery, and Doppler studies consistently fail to demonstrate vascular abnormalities. Surgical dissection involves removal of retroperitoneal tissue which may include sympathetic ganglia and nerve fibres. This results in vasodilatation and production of warmth in the ipsilateral lower extremity. The temperature difference is typically 2 to 3°C and partially resolves over several weeks.

Lower extremity temperature disparity can result from (i) less warmth in one extremity secondary to decreased blood supply or from (ii) relatively more warmth in one extremity secondary to comparatively increased blood flow (as discussed here). Clinically, discriminating between these two etiologies is difficult because expected postoperative temperature variability makes it impossible to label one limb's temperature as *normal.*

Delbert R. Black MD MS
Andrew S. Kassinove MD JD
Maged Mikhail MD
John Stein MD
Duraiyah Thangathurai MD
Los Angeles, USA

References

1 *Scardino PT, Skinner DG.* Germ-cell tumors of the testis: improved results in a prospective study using combined modality therapy and biochemical tumor markers. Surgery 1979; 86: 86–93.

2 *Scardino PT.* Thoracoabdominal retroperitoneal lymphadenectomy for testicular cancer. *In:* Crawford ED, Borden TA (Eds.). Genitourinary Cancer Surgery. Philadelphia: Lea & Febiger, 1982: 271–89.

3 *Fujioka T, Nomura K, Okamoto T, Aoki H, Ohhori T, Kubo T.* Retroperitoneal lymph node dissection for testicular tumors using the thoracoabdominal approach. Int Surg 1993; 78: 154–8.

Interscalene brachial plexus block and pulmonary function

To the Editor:

We compared the effects of posterior and lateral approaches to Interscalene Brachial Plexus Block (IBPB) on respiratory function. Fifty consecutive ASA I-II patients, scheduled for elective upper extremity surgery were studied. Arterial blood pressure, ECG and peripheral oxygen saturation were monitored during the surgical procedure. The subjects were randomly allocated in two groups of 25. Interscalene brachial plexus block was performed by the lateral approach of Winnie[1] in group I and by the posterior approach of Pippa *et al.*[2] in group 2. In both groups 40 ml of anesthetic solution (20 ml prilocaine 1% and 20 ml bupivacaine 0.5% were administered. Respiratory function measurements were performed in the operation room using Autospiro AS 500 apparatus (Minato, Japan). Forced vital capacity (FVC), Forced Expiratory Volume at first second (FEV_1), and

TABLE Decrease (%) in respiratory function after IBPB.

	2 min		*5 min*		*10 min*		*15 min*		*30 min*	
Group	I	II	I	II	I	II	I	II	I	II
FVC	13.4*	15.5*	17.0*	21.0*	20.3*	22.2*	25.3*	30.1*	25.6*	32.2*
FEV_1	11.8*	11.1*	15.0*	19.1*	19.6*	24.4*	24.1*	29.1*	25.2*	31.1*
VC	18.7*	18.8*	24.0*	31.0*	27.1*	33.8*	28.2*	38.2*	29.5*	37.3*

* $P < 0.05$ compared with baseline measurements.

Vital Capacity (VC) tests were performed just before and at 2, 5, 10, 15 and 30 min following IBPB. Statistical analysis of the results was made using Student=s t test and ANOVA.

Following IBPB respiratory function decreased by approximately 13-38 % (Table) but SpO_2 did not decrease below 90%. In both groups there were no cardiovascular changes or other adverse effects. Our results are in accordance with Gottardis *et al.*, Urmey *et al.* and Dagli *et al.*[3B5]

Both approaches to IBPB produce moderate but similar decreases in respiratory function.

Ercan Kurt MD
M. Erdal Güzeldemir MD
Ankara, Turkey

References

1 *Winnie AP.* Interscalene brachial plexus block. Anesth Analg 1970; 49: 455–66.
2 *Pippa P, Cominelli E, Marinelli C, Aito S.* Brachial plexus block using the posterior approach. Eur J Anaesthesiol 1990; 7: 411–20.
3 *Urmey WF, Gloeggler PJ.* Pulmonary function changes during interscalene brachial plexus block: effects of decreasing local anesthetic injection volume. Reg Anesth 1993; 18: 244–9.
4 *Gottardis M, Luger T, Flörl C, et al.* Spirometry, blood gas analysis and ultrasonography of the diaphragm after Winnie's interscalene brachial plexus block. Eur J Anaesthesiol 1993; 10: 367–9.
5 *Dagli G, Güzeldemir ME, Acar HV.* The effects and side effects of interscalene brachial plexus blockade by posterior approach. Reg Anesth Pain Med 1998; 23:87–91.

A "last ditch" airway, revisited

To the Editor:

When faced with unanticipated airway loss, and in the position of "can't intubate, can't ventilate" one may have to resort to cricothyroidotomy to regain access to the airway.[1] If a commercial cricothyroidotomy kit is not readily available, the ability to improvise may be life-saving. Fisher has described an effective improvised cricothyroidotomy cannula consisting of the spike that connects one of the arms of a Y-type blood administration set to the solution bag.[2] Whereas the availability of Y-type blood tubing is usually limited to critical care settings, "single" intravenous tubing sets are more widely distributed in hospitals, ambulances and even some private medical and dental offices.

We suggest that the spike from a 'single' fluid administration set can be used as an improvised cricothyroidotomy cannula:

1. Cut the drip chamber ~3 cm distal to the spike.
2. After pre-incising the skin over the cricothyroid membrane, stabilize the trachea with one hand and insert the spike through the cricothyroid membrane into the trachea.[2]
3. Aspirate from the spike to confirm placement in the trachea. Note that the barrel of most 5cc syringes would provide a sealed fit in the cut end of the drip chamber (Figure).
4. Ventilate as necessary by fitting the 22 mm gas outlet of a self-inflating bag over the cut end of the drip chamber (Figure).

The internal diameter of the spike is the same as that tested by Fisher.[2] It's airflow characteristics are therefore expected to be the same.

Nick Blanas BSC DDS
Joseph A. Fisher MD FRCPC
Toronto, Ontario.

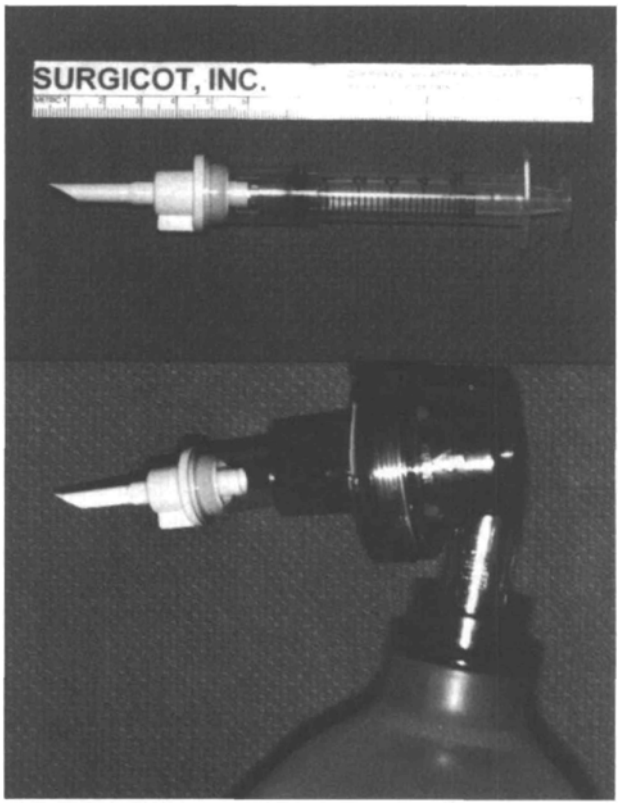

FIGURE Improvised cricothyroidotomy cannula