An MRI Study of Bone Erosions Healing in the Wrist and Metacarpophalangeal Joints of Patients with Rheumatoid Arthritis

Francesca Barbieri[1](✉), Veronica Tomatis[1], Giuseppe Zampogna[1], Elena Aleo[2], Valentina Prono[2], Stefania Migone[2], Patrizia Parascandolo[3], Lorenzo Cesario[3], Gianni Viano[3], and Marco Amedeo Cimmino[1]

[1] Dipartimento di Medicina Interna, Clinica Reumatologica, Genoa, Italy
{francesca.barbieri,cimmino}@unige.it,
veronicatomatis@alice.it, gzampogna@libero.it
[2] Divisione di Radiologia, Università di Genova, Genoa, Italy
{elena.aleo,stefania.migone}@libero.it,
valentina.prono@gmail.com
[3] Softeco Sismat S.r.l., Via de Marini 1, Genoa, Italy
{patrizia.parascandolo,lorenzo.cesario,gianni.viano}@softeco.it

Abstract. Bone erosions, considered the hallmark of rheumatoid arthritis (RA), are shown more accurately by MRI than by conventional radiography (CR). Erosions healing is exceptional when studied by CR. This study is concerned with an extremity-dedicated MRI evaluation of erosion changes in patients with RA followed over time. Wrist and metacarpo-phalangeal (MCP) joints of 57 RA patients were imaged with a dedicated-extremity, 0.2 T MRI at baseline and follow up. A decrease of the RAMRIS erosion score indicating erosion healing, calculated both by conventional visual judgement and by a semi-automated method, was seen in 7 (12.3%) patients at the wrist and in 3 (5.3%) at the MCPs. In the same locations, RAMRIS was unchanged in 17 (29.8%) and 31 (54.4%) patients, and worsened in 33 (57.9%) and 17 (29.8%), respectively. Healing of erosions occurs, although rarely, in patients with RA when studied with sensitive imaging techniques, such as MRI.

Keywords: Rheumatoid arthritis · Magnetic resonance imaging · Erosion · Bone · Bone segmentation · Rheumascore

1 Introduction

Bone erosions have been always considered the hallmark of rheumatoid arthritis (RA) [1]. Advanced imaging techniques, such as computed tomography, MRI, and, at least in several joint areas, ultrasonography have shown increased sensitivity for demonstration of erosions in comparison with conventional radiography [2]. In addition, modern follow-up of erosions requires high sensitivity to change in view of the increased capability of new therapeutic strategies to promote their improvement [3]. Erosions healing in patients with RA is considered exceptional when studied by conventional radiology [4]. Modern and sensitive imaging techniques can appreciate

V. Murino et al. (Eds.): ICIAP 2015 Workshops, LNCS 9281, pp. 129–134, 2015.
DOI: 10.1007/978-3-319-23222-5_16

more subtle changes of bone morphology due to their multiplanar capacity. The calculation of the volume of erosions is traditionally performed in a semiquantitative way based on the subjective evaluation of the reader. A more reproducible method based on automated bone segmentation could be of help in this task. This study is concerned with an extremity-dedicated MRI evaluation of erosion changes in patients with RA followed over time. A comparison between the traditional erosion score and a novel automated one is also described.

2 Patients and Methods

Fifty-seven patients affected by RA (42 women, median age 52 years, range 20-73 years, median disease duration 22 months, range 1-420 months) diagnosed according to the 1987 revised ACR criteria [5] were studied. Disease activity was evaluated by calculating the disease activity score based on 28 joints (DAS 28) [6]. The following laboratory investigations were performed at the time of MRI examinations: erythrocyte sedimentation rate (ESR), C-reactive protein (CRP), IgM rheumatoid factor (RF), and anti citrullinated peptide antibodies (APCA). In the interval between the two MRI examinations, the patients underwent standard antirheumatic treatment, including glucocorticoids, synthetic disease modifying antirheumatic drugs (DMARDs), and biological drugs. The detailed description of these therapies and of their efficacy is beyond the scope of this paper, which is concerned with the evaluation of the changes of bone lesions.

Wrist and metacarpophalangeal (MCP) joints were imaged with a dedicated-extremity, 0.2 T MRI (Artoscan, Esaote, Genova, Italy) at baseline and after a median of 15 months (range 6-121 months). A turbo T1-weighted three dimensional sequence (T3-D T1) in the coronal plane, with subsequent multiplanar reconstructions on the axial and sagittal planes was used; slice thickness was 0.6 mm, TR 860 ms, TE 26 ms, and number of excitations (NEX) 1. Bone studied included the 2nd to 5th MCPs, the 1st to 5th metacarpal bases, the 8 wrist bones, and the distal radius and ulna. Erosions were scored according to the RAMRIS [7]. Each bone was scored from 0 to 10 where 0 corresponded to a normal bone and scores from 1 to 10 were attributed by deciles of percentage of articular bone eroded. As an example, a bone with an erosion involving 10% of it is given a score of 1. They were evaluated in 23 regions in the hand and wrist, for a total score of 0–230.

A semi-automated 3D reconstruction was performed using a tool for computer-aided diagnosis (RheumaSCORE, Softeco Sismat Srl, Genova, Italy) for the segmentation of wrist/hand bones, 3D reconstruction and automatic calculation of the bone volume [8]. The user “paints” some “clues” in the anatomical element to segment, with all parameters automatically adjusted by the software. Starting from the reconstructed bones, the program calculates bones’ volume, erosion’s volume and the RAMRIS for erosions.

3 Results

Thirty/57 (52.6%) patients were RF positive and 34/57 (59.6%) APCA positive. Median ESR was 40 mm/h (range 7-120 mm/h) and median CRP was 6.9 mg/dL (range 0.6-128 mg/dL).

A decrease of the RAMRIS erosion score of at least one point, indicating erosion healing, was seen in 7 (12.3%) patients at the wrist and in 3 (5.3%) at the MCPs.

Two examples of erosion healings are shown in Figures 1 and 2. In Fig. 1, it is more correct to define the structural change of the bone with the generic term of lesion, because at least part of it may be due to bone marrow edema (osteitis) rather than to a true erosion. This is suggested by the complete disappearance of the large lesion of the metacarpal basis, an uncommon event for true erosions. An unchanged RAMRIS was seen in 17 (29.8%) patients at the wrist and in 31 (54.4%) at the MCPs, and a worsened one was observed in 33 (57.9%) and 17 (29.8%) patients, respectively. Altogether 1288 bones were evaluated (840 wrist and 448 MCP bones). A decrease of at least one point in the RAMRIS for erosions was observed in 32 (3.8%) wrist bones and in 7 (1.6%) MCPs. The bones with more frequent healing were 2nd metacarpal basis (0.7%), triquetrum (0.6%), 2nd (0.5%) and 5th (0.74%) metacarpal heads. Fig. 3 shows a scheme of the more frequent sites of erosion healing ordered on a color map with at the opposite ends green, indicating a high frequency of healing, and red indicating that healing is less frequent, although present. Three patients with improved global RAMRIS had, however, worsening of the erosions in at least one wrist bone. Three patients with unchanged RAMRIS and 7 with worsening RAMRIS had erosion healing in at least one wrist bone. The same finding was observed at the MCPs level in 2 and 1 patients, respectively. Finally 5 patients with unchanged RAMRIS had worsening of the erosions at the wrist and 2 patients at the MCPs.

The bones with erosion healing were given a RAMRIS value by both traditional visual evaluation and by using the RheumaSCORE. The correlation between the methods is reported in Fig. 4, where concordance is shown in green and discordance in red for the 25 patients in whom erosion changes were seen. The x axis reports the different bones studied. Concordance was present if the reader and RheumaSCORE gave the identical RAMRIS score to the erosion. Discordance occurred in all remaining cases.

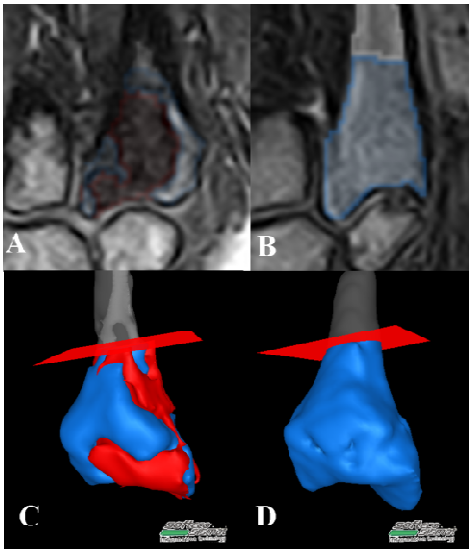

Fig. 1. Baseline and follow up MRI examinations (A, B) and corresponding 3D models (C, D) for the 2nd metacarpal basis. The bone lesion is shown in red, the normal bone in blue.

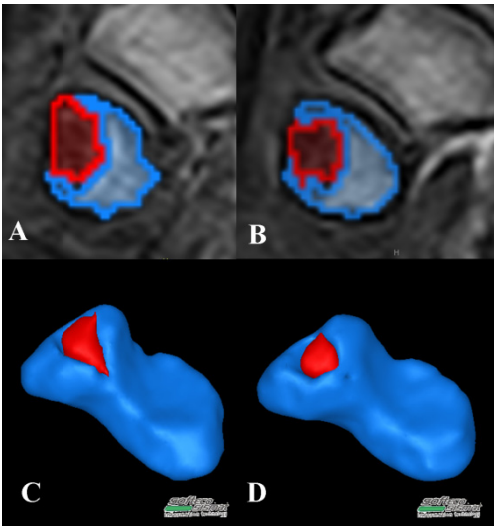

Fig. 2. Baseline and follow up MRI examinations (A, B) and corresponding 3D models (C, D) for the scaphoid. Erosion in red, bone in blue.

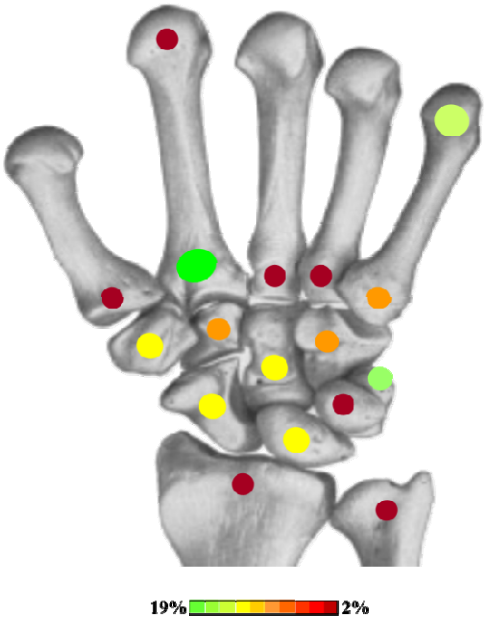

Fig. 3. Color map of the locations where RAMRIS erosion score improvement was seen. Green dots correspond to the highest frequency of lesion improvement, red ones to the lowest frequency.

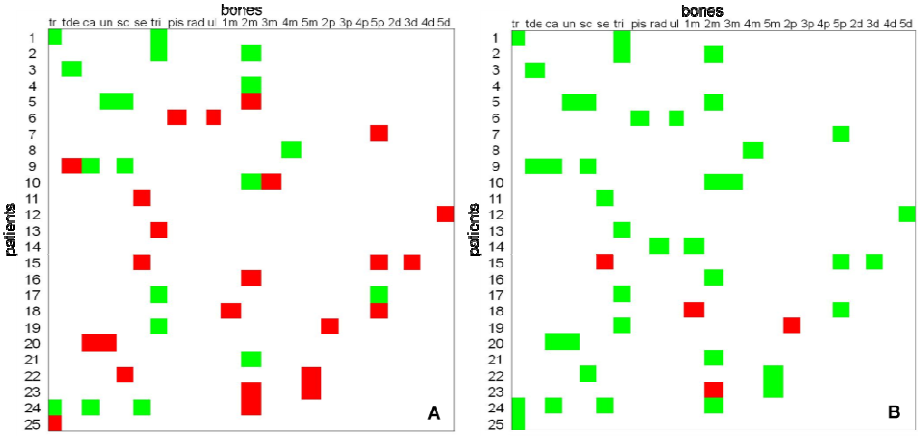

Fig. 4. Correlations between traditional and semi-automated RAMRIS erosions score at baseline (A, 45.2% concordance) and at follow up (B, 92.9% concordance). Agreement is shown in green, disagreement in red.

4 Discussion

Detection of erosions in RA and quantification of their extent are important for both diagnosis and clinical management [9]. Current anti-rheumatic therapy has the goal of retarding or even arresting the progression of bone erosions through suppression of inflammation. This event induces a transformation of the bone microenvironment towards bone anabolism, a situation shown to be central for the induction of erosion repair in experimental models of arthritis. In RA patients, erosion repair can occur under certain circumstances, such as sustained pharmacological TNF inhibition [3].

Our results confirm that healing of erosions occurs, although rarely, in patients with RA when studied with sensitive imaging techniques, such as MRI. The percentages of improved bones was higher in our study than the 1.8% observed with MRI by Møller Døhn et al in a trial where RA patients were treated with adalimumab [3]. This difference may be ascribed to the different population of RA patients studied.

A new finding is the coexistence of erosion's healing and deterioration in the same hand or even in the same bone. This was a frequent observation, which supports the view that not only general disease activity but also localized inflammatory and mechanical stress-associated mechanisms are probably at work.

The agreement between the traditional and semi-automated RAMRIS evaluations was good only for the follow up MRI, after patient treatment (Fig. 4). This discrepancy is apparently difficult to justify because the observers and the techniques were identical at both time points. A possible explanation is the concomitant decrease of bone marrow edema that could have occurred after successful treatment. The experienced reader is in most cases able to differentiate bone marrow edema from real erosions, whereas the automated method may be not. As a consequence, a human supervision to correct possible imprecisions of the automated procedure is still necessary.

In conclusion, we have shown that the study of the volume of bone erosions reveals that healing of the erosions occurs in a limited percentage of RA patients. This information is useful for the clinicians in order to tailor the treatment to the individual patient. The use of a dedicated software may further facilitate the procedure of erosion staging.

Acknowledgements. Supported in part by a grant from the Univerity of Genova (Progetti di Ateneo 2013).

References

1. Scott, D.L., Wolfe, F., Huizinga, T.W.: Rheumatoid arthritis. Lancet **376**, 1094–1108 (2010)
2. McQueen, F.M., Stewart, N., Crabbe, J., et al.: Magnetic resonance imaging of the wrist in early rheumatoid arthritis reveals a high prevalence of erosions at four months after symptoms onset. Ann. Rheum. Dis. **57**, 350–356 (1998)
3. Møller Døhn, U., Boonen, A., Hetland, M.L., et al.: Erosive progression is minimal, but erosion healing rare, in patients with rheumatoid arthritis treated with adalimumab. A 1-year investigator-initiated follow-up study using high-resolution computed tomography as primary outcome measure. Ann. Rheum. Dis. **68**, 1585–1590 (2009)
4. Rau, R., Herborn, G., Wassenberg, S.: Healing of erosive changes in rheumatoid arthritis. Clin. Exp. Rheumatol. **22**, S44–S49 (2004)
5. Arnett, F.C., Edworthy, S.M., Bloch, D.A., McShane, D.J., Fries, J.F., Cooper, N.S., et al.: The American Rheumatism Association 1987 revised criteria for the classification of rheumatoid arthritis. Arthritis Rheum. **1988**(31), 315–324 (1987)
6. van Gestel, A.M., Haagsma, C.J., van Riel, P.L.: Validation of rheumatoid arthritis improvement criteria that include simplified joint counts. Arthritis Rheum. **41**, 1845–1850 (1998)
7. Bird, P., Conaghan, P., Ejbjerg, B., McQueen, F., Lassere, M., Peterfy, C., Edmonds, J., Shnier, R., O'Connor, P., Haavardsholm, E., Emery, P., Genant, H., Ostergaard, M.: The development of the EULAR-OMERACT rheumatoid arthritis MRI reference image atlas. Ann. Rheum. Dis. **64**(Suppl 1), i8–i10 (2005)
8. Catalano, C.E., Robbiano, F., Parascandolo, P., Cesario, L., Vosilla, L., Barbieri, F., Spagnuolo, M., Viano, G., Cimmino, M.A.: Exploiting 3D part-based analysis, description and indexing to support medical applications. In: Greenspan, H., Müller, H., Syeda-Mahmood, T. (eds.) MCBR-CDS 2012. LNCS, vol. 7723, pp. 21–32. Springer, Heidelberg (2013)
9. Haavardsholm, E.A., Ostergaard, M., Hammer, H.B., et al.: Monitoring anti-TNFalpha treatment in rheumatoid arthritis: responsiveness of magnetic resonance imaging and ultrasonography of the dominant wrist joint compared with conventional measures of disease activity and structural damage. Ann. Rheum. Dis. **68**, 1572–1579 (2009)